

Review Article

ALPORT SYNDROME: AN OVERVIEW OF THE PATHOLOGY.

ABSTRACT

Alport syndrome (AS), also known as hereditary nephrosis, is an X-linked genetic disease that predominantly affects type IV collagen mainly in the kidneys and the eyes. It primarily affects males, particularly children, and can be transmitted via autosomal dominant and recessive inheritance modes. It typically presents with a triad of kidney involvement (nephritis), sensorineural hearing loss (SNHL), and visual impairment. Diseases related to mutation of the gene of the X chromosome include leiomyomatosis and AMME complex. AMME Complex is an acronym for alport syndrome, Midface hypoplasia, Mental retardation, and Elliptocytosis.

~~The most commonly implicated genes are COL4A3, COL4A4, and rarely COL4A5.~~ All type IV collagen genes must undergo mutation for the disease to occur. The most commonly implicated genes are COL4A3, COL4A4, and rarely COL4A5. It is one of the three prevalent inherited kidney diseases ~~of the kidney, in.~~ In addition to others ~~likesuch as~~ polycystic kidney disease, cystinosis, lowe syndrome, hereditary interstitial kidney disease, fabry disease, gittleman & barter's syndrome, and nephronophthisis, AS is considered a congenital disease.

The disease has no cure. Therapeutic strategies involve combating the symptoms and complications associated with the disease. The era of 21st-century technological evolution has clarified the diagnosis and evaluation of AS, but more studies are essential to help further understand the disease spectrum. ~~The disease has no cure. Therapeutic strategies involve combating the symptoms and complications associated with the disease.~~ This review article highlights the salient learning objectives to foster a better understanding of Alport syndrome for basic medical students and health professionals.

Keywords: Alport syndrome, COL4A3-5 genes, Type IV collagen, X-linked disorder, chronic renal failure.

INTRODUCTION

This Alport syndrome (AS) is an inherited defect or disease that damages small blood vessels of the kidney, also known as a basement membrane (BM) disorder arising from the mutation of collagen type IV. This disease is characterized by sensorineural hearing loss and ocular impairment. [1]

During late childhood, patients with AS often develop sensorineural hearing loss caused by inner ear abnormalities. The affected people may also have deformed lenses in their eyes. [2]

Formatted: Not Superscript/ Subscript

It is also associated with thin basement membrane nephropathy (TBMN). [3] Patients with TBMN have disparities in the same genes that cause AS. They also have persistent hematuria, as in [alport syndrome](#) patients [3]. These patients are less likely to have extrarenal abnormalities. [Findings such as proteinuria](#) Proteinuria, hypertension, kidney insufficiency, and kidney failure are less common in TBMN patients [as to alport syndrome than AS](#) patients. [3] People with hematuria and variants in the *COL4A3*, *COL4A4*, or *COL4A5* genes should be diagnosed with [alport syndrome-AS](#). In contrast, those with TBMN but no gene variant should be diagnosed with hematuria with TBMN. Differentiating alport syndrome and TBMN can be difficult, particularly in women and young patients. [3]

There are three genetic types of AS, namely:

- i. X-linked AS (XLAS)- Most common, affects 80% of cases and usually occurs in males rather than females.
- ii. Autosomal recessive AS (ARAS) this type occurs equally in males and females. This type affects 15% of the cases. [2]
- iii. The third type is the least common, affects only 5% of the cases, and equally occurs in males and females, and this type is called autosomal dominant alport syndrome (ADAS). [1,2]

Prevalence/Epidemiology of Alport syndrome

Alport syndrome affects approximately 1 in every 5,000-10,000 people in the United States. Statistics show that about 0.2% of adults and about 3% of children in the US with end-stage kidney disease have Alport syndrome [4].

[Alport syndrome](#) does not affect any particular race or ethnicity more readily. [However, in the US, the disease](#) USA, AS has been noticed to have a higher prevalence rate in Western states than in other areas [in the USA](#) [5].

[Alport syndrome](#) AS causes about 2% of pediatric end-stage renal disease cases [6].

XLAS [type](#) is the most prevalent (80-85% of cases) [%](#). The autosomal recessive mode of inheritance accounts for about 15% of the cases. The least common type is the autosomal dominant type, with only a few cases reported, which accounts for only \leq 5% of cases [or less](#). The X-linked type of Alport syndrome is more common and has a greater severity in men than in women. [4]

ETIOPATHOGENESIS

A gene mutation in the connective tissue of collagen IV and mutations in the *COL4A3*, *COL4A4*, and *COL4A5* genes cause AS. [2]

_ The cause of glomerulonephritis is good pasture syndrome(GPS). GPS is caused by autoantibodies against the BM of the glomeruli and alveoli. Abnormality in the BM from a different cause similarly affects [this syndrome](#) AS. [2]

Being a male is the highest risk factor for getting [alport syndromeAS](#). Smoking, obesity, hypertension, glucose intolerance, or diabetes mellitus may also damage kidney filters causing AS. [7]

Formatted: Font color: Auto, Pattern: Clear

Type IV collagen is a crucial component of the inner ear structure, especially [theCorti's organ-of Corti](#), which [transformtransforms](#) sound waves and impulses from nerves to the brain. Error in type IV collagen usually leads to abnormality in the inner ear function, which causes hearing loss. [8] Collagen type IV is also crucial for keeping the shape of the lens and the retina's actual color. Type IV collagen mutation may lead to malformed lenses and an abnormally colored retina. [8, 9]

Genetic implications

AS's modes of inheritance are diverse. These modes of inheritance constitute the types of Alport syndrome.

In about 80% of cases, it is X-linked. It involves the mutation of [the COL4A5](#) gene. This gene is on the X chromosome. Males are especially susceptible as they only have a single [X-chromosome](#). One disrupted gene of [COL4A5](#) is enough to cause kidney failure and other symptoms in these patients. In females, a single copy mutation of the [COL4A5](#) gene mainly results in only hematuria, but some other females can have more severe symptoms. There is also a 50% chance of affected females transferring the disease to their male off-springs. However, fathers who have the disease cannot pass along the X-linked form of this disease to their sons [2, 3].

[Type IV collagen alpha 3, 4, and 5 interaction play a functional role in the BM of the kidney, inner ear, and eye \[10\]](#). The X-linked [COL4A5](#) gene provides the instructions for making the alpha5 (IV) chain of the type IV collagen. The alpha5 chain combines with the other two chains, alpha3, and alpha4, to form a structurally complete type IV collagen molecule. ~~Type IV collagen alpha 3, 4, and 5 interaction play a functional role in the BM of the kidney, inner ear, and eye [10]~~.

Formatted: Font: Not Italic

In about 15% of cases, the mode of inheritance is autosomal recessive. It involves a mutation in both copies of [the COL4A3](#) or [COL4A4](#) gene. For this to occur, an individual's parents must be carriers, [each](#) of one copy of the mutated genes. Most carriers are unaffected, but some could develop a less severe condition called TBMN, indicated by blood in the urine [2].

The autosomal [COL4A3](#) gene provides the instruction for making the alpha3 (IV) chain of type IV collagen [11]. The autosomal [COL4A4](#) gene provides the instruction for making the alpha4 (IV) chain of type IV collagen [12].

In about 5% of cases, the mode of inheritance is autosomal dominant. In this form of alport syndrome, there is a mutation in either the [COL4A3](#) or the [COL4A4](#) gene in each cell [2]. Some individuals with alport syndrome present with contiguous gene syndrome. It involves microdeletion of genetic material and loss of function of adjacent genes (genes in close proximity) on the long arm of the X chromosome, which affects the [COL4A5](#) and [COL4A6](#) genes. People with the contiguous gene syndrome often develop associated diseases, like leiomyomatosis and AMME complex, alongside [alport syndromeAS](#) [3].

Molecular genetics and relation to other renal diseases

The genetics of [alport syndromeAS](#) was classified under two categories, the X-linked form and the autosomal (Dominant and recessive) form of inheritance. The X-linked form involves the COL4A5 gene mutation, and the autosomal recessive [involvesconsists of](#) the COL4A3 and COL4A4 gene mutations. However, some cases involved an autosomal dominant pattern and had father-to-son transmission. The two categories could not easily be used to classify the disease. In conjunction with that, certain kidney disorders were observed to have a molecular genetic relationship with [alport syndrome-AS](#). TBMN, also known as benign familial hematuria, was present in families affected by autosomal recessive AS. There was also an associated finding of heterozygous mutations in the COL4A3 and COL4A4 genes related to TBMN. These findings confirmed the relationship between the two [13].

The spectrum of [alport syndromeAS](#) genetics is vast, with one end, TBMN, just involving hematuria with no kidney impairment, and the other, characteristic [alport syndromeAS](#) with end-stage renal disease and ocular and hearing abnormalities. So even patients with TBMN have a familial chance of kidney failure [13]. The diagnostic finding of kidney diseases and the spectrum of AS has been further problematized with the advent of hereditary focal segmental glomerulosclerosis (FSGS). Genetic analysis of patients with this disease revealed a relationship between [alport syndromeAS](#) and the spectrum [thereof](#) [13].

A cohort study conducted by Malone et al. of families diagnosed with hereditary FSGS revealed that a fraction of the families had compound heterozygosity for the COL4A3. There were no FSGS gene mutations implicated in these families. The COL4A3 alleles contained a mutation that can typically cause [alport syndromeAS](#) [13]. Alport syndrome pathogenesis involves a defect in the GBM, which would ultimately lead to foot process effacement, so secondary FSGS is commonly observed in late-stage biopsies [13]. Familial focal segmental glomerulosclerosis, characteristic proteinuria, hematuria, and glomerular pathology, can be linked to type IV collagen mutations involving the COL4 genes [13].

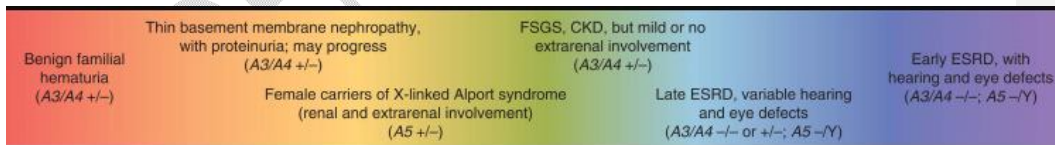

Table: 1 The spectrum of alport syndrome, thin basement membrane nephropathy (benign familial hematuria) at one end to early-onset end-stage renal disease with hearing and eye defects at the other end.

<https://els-jbs-prod-cdn.jbs.elsevierhealth.com/cms/attachment/1f81bbf1-0abb-435b-9928-be02180d5d61/gr1.jpg>

PATHOPHYSIOLOGY

In the kidneys, glomeruli form an integral component of the nephron that filters the blood, and these. The glomeruli have basement membranes called glomerular basement membranes (GBM). GBM, along with the has fenestrated capillary endothelium, and the podocytes slit diaphragm, forms a selective filter. [14,15]

In Alport syndrome, the kidney functions normally through early childhood, but over time the missing or non-functional type 4 collagen causes the GBM to become thin and overly porous. This, which allows red blood cells to pass through the capillary, and urinary filtrate leads to capillaries, causing microscopic hematuria, which is why red blood cells are seen in the urine under a microscope. This might eventually lead to or gross hematuria, where the red blood cells can be seen with the naked eye. Over time, excessive amounts of protein get through the filter, resulting in the disease progresses and causes proteinuria or protein in the urine. Finally, this excessive protein loss and other factors caused the GBM to undergo sclerosis. Unhealthy glomeruli of an Alport syndrome patient might AS patients may develop renal insufficiency, which can lead due to progressive glomeruli damage, leading to renovascular hypertension. Hematuria, renal insufficiency, and hypertension contribute to the categorization of Alport Syndrome as glomerulonephritis. [14,15]

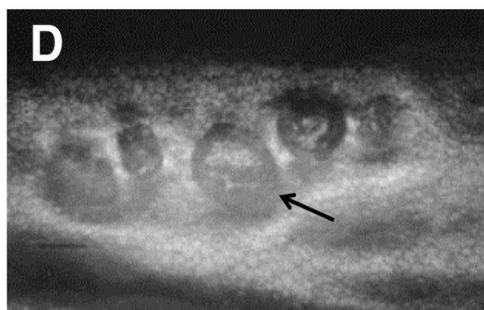
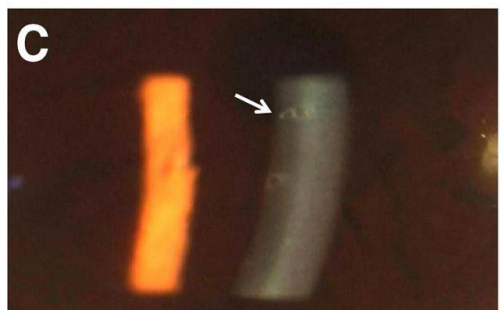
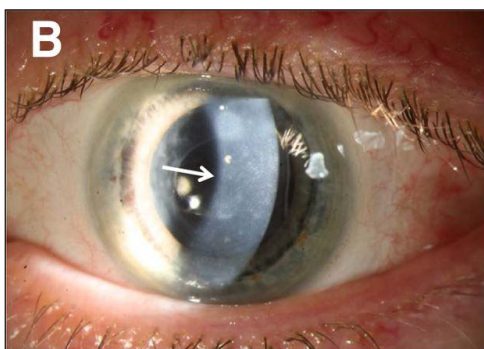
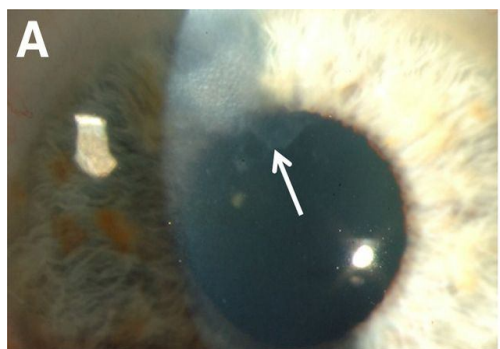
CLINICAL MANIFESTATIONS

In all types of Alport syndrome, the kidneys are affected. The tiny blood vessels in the glomeruli are harmed and may be unable to filter the wastes and extra fluid in the body. Patients with Alport syndrome may have hearing issues and abnormalities in their vision. [3]

Signs and symptoms change according to a person's age, gender, and the inherited type of Alport syndrome. However, the usual symptoms are hematuria (the most common and earliest sign of Alport syndrome), proteinuria, hypertension, lower limb edema, and eye swelling in the legs, foot, ankle, and around the eyes (edema). [16]

Also, in earlier stages, these symptoms may be noticed: Nausea and vomiting, muscle cramps, loss of appetite, dry or itchy skin, dyspnea, insomnia, and urinating either too much or too little. [3] The first sign of kidney disease is hematuria. Hematuria is often not visible to the naked eye but can be noticed under a microscope (usually microscopic hematuria). However, blood may be visible in the urine. For example, the urine may be brown, pink, or red for some days, mainly if a patient has a cold or flu (Gross hematuria). massive hematuria can occur, particularly after an upper respiratory tract infection. In early childhood, males with XLAS usually exhibit persistent microscopic hematuria. Although hematuria may be intermittent, 95% of females with XLAS syndrome have microscopic hematuria. In childhood, hematuria is seen in both males and females with ARAS. [3, 16]

Additional symptoms that may occur in Alport syndrome patients. In a few males, Aorta aneurysms of the chest or abdominal portions of the aorta can occur are not uncommon, especially in male patients [16]. Aneurysms happen when the walls of blood vessels balloon outward, potentially rupturing and causing bleeding through the body. [7] The disease can be complicated by chronic renal failure, blindness, chronic renal failure, and permanent deafness.



UNDE

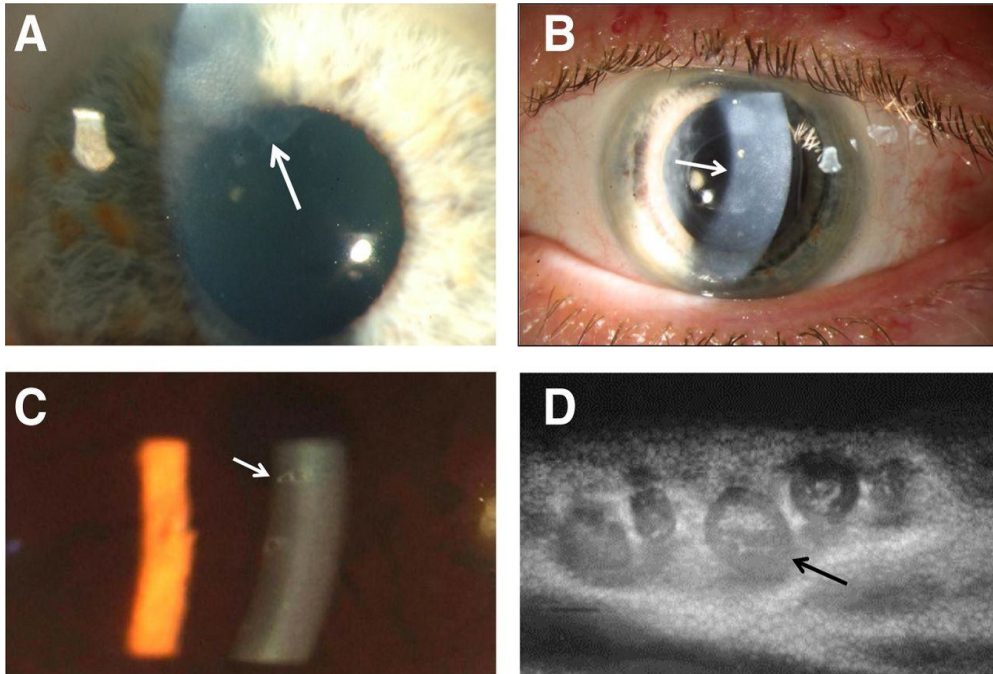


Fig1: Images showing a spectrum of corneal changes in Alport syndrome (Shown by arrows). Slit-lamp microscopy shows A. Scarring and erosion (cornea) B. Posterior corneal dystrophy C. Posterior corneal dystrophy with vesicles D. Doughnut-like lesions, vesicles, clustering around endothelial cells.

Source: <https://cjasn.asnjournals.org/content/clinjasn/10/4/703/F2.large.jpg?width=800&height=600&carousel=1>

Associated diseases

As mentioned previously, people with the contiguous gene syndrome can develop associated conditions: leiomyomatosis and AMME complex.

Leiomyomatosis is characterized by uncontrolled growth and proliferation of smooth muscle cells. It affects the esophagus and presents with difficulty swallowing (dysphagia) due to the narrowing of the esophagus. Vomiting and epigastric pain are also noted. In females, the uterus is affected. There is an enlarged and abnormal uterine wall. Vulva and clitoral hypertrophy are not uncommon [3, 17].

AMME complex is a rare associated condition. It stands for Alport syndromeX-linked. AMME complex consists of AS, intellectual disability, midface hypoplasia, and elliptocytosis. It is an X-linked contiguous gene deletion syndrome. Affected individuals exhibit symptoms of Alport

[syndrome present with AS features](#), intellectual disability, typically mental retardation, mid-face hypoplasia, and abnormally shaped red blood cells (elliptocytosis), which can result in anemia [3, 18].

Thin basement membrane nephropathy ~~typically occurs independently of Alport syndrome, but can also be associated.~~ [Thin basement membrane nephropathy](#) (TBMN) describes a condition with hematuria without other signs of kidney disease. People with this nephropathy would have thin glomerular basement membranes on kidney biopsy, and there will be no renal failure or a family history of renal failure. [Thin basement membrane nephropathy typically occurs independently of Alport syndrome, but can also be associated.](#) There is usually an overlap between Alport syndrome and thin basement membrane nephropathy. For one, TBMN results from a diseased variant in one of the type IV collagen genes. Furthermore, people diagnosed with Alport syndrome often have thin glomerular basement membranes. However, hematuria with genetic variants in the COL4A3, COL4A4, or COL4A5 should be diagnosed as Alport syndrome [3].

DIAGNOSIS

Patients with persistent glomerular hematuria and hypertension are suspected of having Alport syndrome and a family history of Alport syndrome or renal failure, which increases the likelihood of being diagnosed with this disease. Other clinical features to note are hearing loss (Audiometry), lenticonus, or retinopathy (Ophthalmoscope). Their presence suggests a high likelihood of diagnosing Alport syndrome.

Baseline investigations like urinalysis to show hematuria and proteinuria are done. Other abnormal serum [protein/proteins](#), electrolytes, urea, and creatinine suggest renal failure.

Molecular genetic testing of the pathogenic variant(s) allows for the diagnosis of Alport syndrome. The pathogenic variants in *COL4A3* and *COL4A4* can be autosomal dominant or autosomal recessive, while pathogenic variants in *COL4A5* are X-linked [19] [20] [21].

Approaches to this Molecular genetic testing can include a combination of gene-targeted and comprehensive genomic testing depending on the phenotype [19].

Histopathology

Basement membranes support the cells and form barriers. The three basement membrane layers are lamina Lucida, lamina densa (which includes the type 4 collagen, and lamina reticularis. [15]

Electron microscopy (EM) of the glomerulus of Alport syndrome can be seen as a Basket-Weave pattern, and on LIGHT MICROSCOPY, the majority of cases revealed two unique pathologic changes:

1. A "zone of separation" between the basilar membrane and overlying cells of the organ of Corti.
2. The presence of cells filling the tunnel of Corti and extracellular spaces of Nuel. [12][21]

The cytologic loss of hair cells, stria vascularis, and cochlear neuronal cells were insufficient to account for the observed SNHL in our cases. Electron microscopy was applied in four cases; all four revealed the following [15] [22]:

1. The zone of separation observed at light microscopy occurred between the basement and basilar membranes.
2. The cells within the tunnel of Corti and the spaces of Nuel were morphologically similar to supporting cells.
3. The basement membrane of the stria capillaries and the spiral vessel (under the basilar membrane) were normal. [15][22]

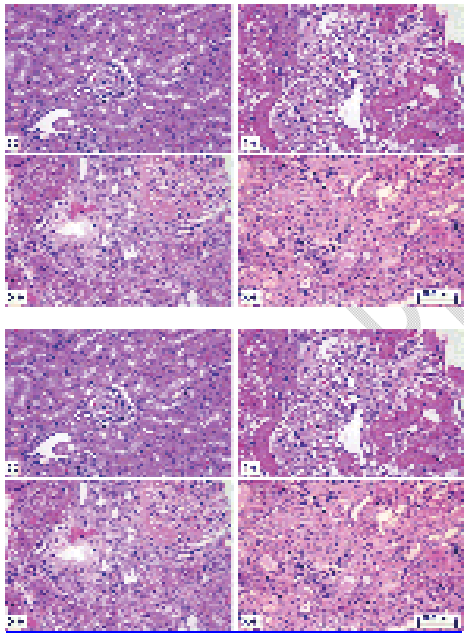
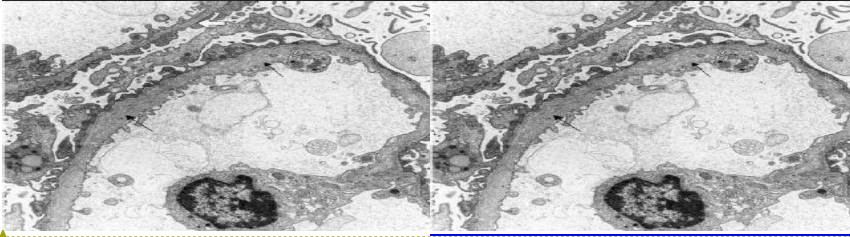


Fig2: Multiple H&E stain showing widened mesangium, mesangial cell proliferation, and sclerosed glomerulus, suggestive of Alport disease.

Source: <http://www.dxline.info/diseases/alport-syndrome#>



Formatted: Font: (Default) Trebuchet MS, 10.5 pt

Fig.3: Electron microscopic appearance of the glomerular capillary wall in the Alport syndrome (Basket weave pattern). [22]

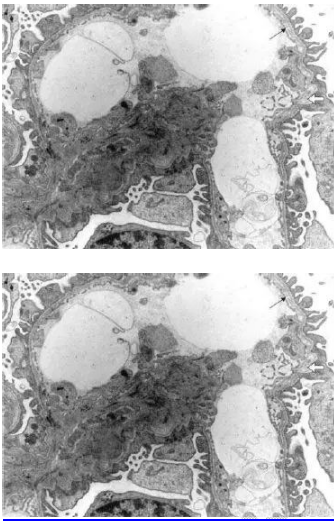


Fig.4: Extensive attention to the GBM. With one short segment Showing replication of the lamina densa and dense particles within lacunae. [22]

DIFFERENTIAL DIAGNOSIS

Some common differential diagnoses of Alport's syndrome include persistent familial hematuria, renal failure, hearing loss, retinal fleck, and lamellated glomerular basement membrane [23].

These include;

- Polycystic Kidney Disease[24]
- Thin basement membrane nephropathy[24]
- Medullary Cystic Disease [25]
- Epstein Syndrome [26]
- Fechtner Syndrome [27]
- Leiomyomatosis [28]

- MYH9-related disorders (MYH9RD) are characterized by large platelets and thrombocytopenia. It is variably associated with the young-adult onset of progressive sensorineural hearing loss, presenile cataract, the elevation of liver enzymes, and renal disease manifesting initially as glomerular nephropathy [19].

MANAGEMENT OF ALPORT SYNDROME

Alport syndrome is managed by treating symptoms as presented in each patient. [3] In order to reduce proteinuria in children with X-linked Alport syndrome, Angiotensin-converting enzyme (ACE) inhibitors are used [23]. Angiotensin-receptor blockers and aldosterone inhibitors also have additional benefits for proteinuria [29]. Some evidence from a retrospective study, animal models, and other forms of renal failure has suggested that ACE inhibitors delay the onset of end-stage renal failure and improve life expectancy in men, even before the onset of proteinuria [30]. The effect of the renin-angiotensin blockade on proteinuria and renal failure progression must be formally evaluated [21] [31]. Other potential therapies include statins [21] [32], metalloproteinase inhibitors [33], vaso-peptidase inhibitors [34], chemokine receptor antagonists [35], and stem cell therapy [36, 37]. Some patients who do not respond to or tolerate ACE inhibitors may be treated with angiotensin receptor blockers (ARBs) which bring about similar results [3].

Treatment and management may slow the progression of kidney disease in Alport syndrome. There is yet no cure for this disorder, and no drugs or therapy has thus far been shown to completely stop kidney decline [3]. The progression rate to kidney failure in patients with this disease varies highly. In many patients affected by Alport syndrome, kidney function will eventually deteriorate to where dialysis or a kidney transplant is required [3].

The renal failure may be managed conservatively to slow progression before transplantation (stem cells and organ). ~~There are numerous drug and Numerous~~ drugs and drug trials are employed to reduce the progression of chronic renal failure in these patients. - The most documented list of medications are Sodium-glucose co-transporter 2 inhibitors(SGLT2i), Bardoxolone methyl, Anti-microRNA-21, Endothelin type A receptor inhibitors, angiotensin II type 1 receptor inhibitors, anti-lipidemic drugs (statin) and lipid modifiers, osteopontin blockers, hydroxychloroquine, metformin, Paricalcitol and chaperones. [21][31][32][33][34]

Hearing problems should be prescribed In case of deafness, hearing aids as may be needed.

Cataract removal can be suggested for visual issues. Surgical intervention may be required to treat diffuse leiomyomatosis [19].

CONCLUSION

Alport syndrome, also known as hereditary nephrosis, is predominantly an X-linked inheritance disorder of type 4 collagen synthesis, but variants may be the autosomal recessive and dominant inheritance mode of inheritance. [21] They are commonly seen in males with varying degrees of

https://www.wikidoc.org/index.php/Alport_syndrome_epidemiology_and_demographics#:

6. Expert reviewer(s): Dr. Laurence HEIDET, Pr Rachel LENNON- Orphanet: Alport syndrome. March 2020. https://www.orpha.net/consor/cgi-bin/OC_Exp.php?lng=EN&Expert=63
7. Slajpah M, Gorinsek B, Berginc G, Vizjak A, Ferluga D, Hvala A, Meglic A, Jaksa I, Furlan P, Gregoric A, Kaplan-Pavlovic S, Ravnik-Glavac M, Glavac D. Sixteen novel mutations identified in COL4A3, COL4A4, and COL4A5 genes in Slovenian families with Alport syndrome and benign familial hematuria. *Kidney Int.* 2007 Jun; 71(12):1287-95. Epub 2007 March 28.
[Alport Syndrome | National Kidney Foundation](#)
8. kashtan CE. Alport syndrome: an inherited disorder of renal, ocular, and cochlear basement membranes. *Medicine.* 1999; 78:338-60. [Alport syndrome. An inherited disorder of renal, ocular, and cochlear basement membranes - PubMed \(nih.gov\)](#)
9. [Distribution of type IV collagen in the cochlea in Alport syndrome - PubMed \(nih.gov\)](#)
Zehnder AF, Adams JC, Santi PA, Kristiansen AG, Wacharasindhu C, Mann S, Kalluri R, Gregory MC, Kashtan CE, Merchant SN.
10. MedlinePlus [Internet]. Bethesda (MD): National Library of Medicine (US); [updated 2020 June 24]. COL4A5 gene, [updated Dec 1, 2013; cited 2022 August 16]
<https://medlineplus.gov/genetics/gene/col4a5/>
11. MedlinePlus [Internet]. Bethesda (MD): National Library of Medicine (US); [updated 2020 June 24]. COL4A3 gene, [updated Dec 1, 2013; cited 2022 August 16]
<https://medlineplus.gov/genetics/gene/col4a3/>
12. MedlinePlus [Internet]. Bethesda (MD): National Library of Medicine (US); [updated 2020 June 24]. COL4A4 gene, [updated Dec 1, 2013; cited 2022 August 16]
<https://medlineplus.gov/genetics/gene/col4a4/>
13. . Jeffrey H. Miner Pathology vs. Molecular genetics: (re)defining the spectrum of Alport syndrome. December 1, 2014
[https://www.kidney-international.org/article/S0085-2538\(15\)30474-9/fulltext](https://www.kidney-international.org/article/S0085-2538(15)30474-9/fulltext)
14. Pescucci C, Longo I, Bruttini M, Mari F, Renieri A. Type-IV collagen related diseases. *J Nephrol.* 2003 Mar-Apr; 16(2):314-6. Review.
pixonize usmle 1 mnemonic [Alport Syndrome | USMLE Step 1 Mnemonic - YouTube](#)
15. Ramesh Saxena, MD, PhD; Chief Editor: Vecihi Batuman, MD, *FASN* Jun 28, 2021
[Alport syndrome - an Osmosis preview - YouTube](#)
16. Thorner PS. Alport syndrome and thin basement membrane nephropathy. *Nephron Clin Pract.* 2007;106(2):c82-8. Epub 2007 June 6. Review. niddk-health-information

17. Brooke E. Howitt, Bradley J. Quade in Diagnostic Gynecologic and Obstetric Pathology (Third Edition), chapter 20- Uterine Mesenchymal Tumors. February 22, 2018.

Marc S. Levine, in Textbook of Gastrointestinal Radiology, 2-Volume set (Fourth Edition). 4 March 2022

<https://www.sciencedirect.com/topics/medicine-and-dentistry/leiomyomatosis>

18. OMIM AMME COMPLEX, ALPORT SYNDROME, MENTAL RETARDATION, MIDFACE HYPOPLASIA, AND ELLIPTOCYTOSIS; Creation: Victor A. McKusick, 6/1/1999.

Contributors: Hilary J. Vernon-updated 04/28/2022

<https://www.omim.org/entry/300194>

19. Kashtan CE. Alport Syndrome. 2001 Aug 28 [Updated 2019 Feb 21]. In: Adam MP, Mirzazadeh GM, Pagon RA, et al., editors. GeneReviews® [Internet]. Seattle (WA): University of Washington, Seattle; 1993-2022. Available from:

<https://www.ncbi.nlm.nih.gov/books/NBK1207/>

20. Kashtan CE, Ding J, Garosi G, Heidet L, Massella L, Nakanishi K, Nozu K, Renieri A, Rheault M, Wang F, Gross O. Alport syndrome: a unified classification of genetic disorders of collagen IV $\alpha345$: a position paper of the Alport Syndrome Classification Working Group. *KidneyInt.* 2018;93:104551. [PubMed] [Reference list]

21. Chavez E, Rodriguez J, Drexler Y, Fornoni A. Novel Therapies for Alport Syndrome. *Front Med (Lausanne)*. 2022;9:848389. Published 2022 Apr 25. doi:10.3389/fmed.2022.848389

22. Duvall-Young J, Short CD, Raines MF, Gokal R, Lawler W. Fundus changes in mesangiocapillary glomerulonephritis type II: clinical and fluorescein angiographic findings. *Br J Ophthalmol.* 1989;73(11):900-906. doi:10.1136/bjo.73.11.900

23. Savige J, Gregory M, Gross O, Kashtan C, Ding J, Flinter F (2013). "Expert guidelines for the management of Alport syndrome and thin basement membrane nephropathy." *J Am Soc Nephrol.* 24 (3): 364–75. doi:10.1681/ASN.2012020148. PMID 23349312.

https://www.wikidoc.org/index.php/Alport_syndrome_differential_diagnosis

24. Hudson BG, Reeders ST, Tryggvason K (1993). "Type IV collagen: structure, gene organization, and role in human diseases. Molecular basis of Goodpasture and Alport syndromes and diffuse leiomyomatosis". *J Biol Chem.* 268 (35): 26033–6. PMID 8253711. https://www.wikidoc.org/index.php/Alport_syndrome_differential_diagnosis

25. Amari F, Segawa K, Ando F (1994). "Lens coloboma and Alport-like glomerulonephritis." *Eur J Ophthalmol.* 4 (3): 181–3. PMID 7819734

https://www.wikidoc.org/index.php/Alport_syndrome_differential_diagnosis

26. Lonsdale RN, Roberts PF, Vaughan R, Thiru S (1992). "Familial oesophageal leiomyomatosis and nephropathy." *Histopathology.* 20 (2): 127–33. PMID 1559666

https://www.wikidoc.org/index.php/Alport_syndrome_differential_diagnosis

27. García-Torres R, Orozco L (1993). "Alport-leiomyomatosis syndrome: an update". *Am J Kidney Dis.* 22 (5): 641–8. PMID 8238008.

https://www.wikidoc.org/index.php/Alport_syndrome_differential_diagnosis

28. McCarthy PA, Maino DM (2000). "Alport syndrome: a review." *Clin Eye Vis Care*. 12 (3–4): 139–150. PMID 11137428.
https://www.wikidoc.org/index.php/Alport_syndrome_differential_diagnosis
29. Kaito H, Nozu K, Iijima K, Nakanishi K, Yoshiya K, Kanda K, Przybyslaw Krol R, Yoshikawa N, Matsuo M: The effect of aldosterone blockade in patients with Alport syndrome. *Pediatr Nephrol* 21: 1824–1829, 2006pmid:17039334 [PubMed]
<https://jasn.asnjournals.org/content/24/3/364>
30. Gross O, Licht C, Anders HJ, Hoppe B, Beck B, Tonshoff B, Hocker B, Wygoda S, Ehrich JH, Pape L, Konrad M, Rascher W, Dotsch J, MullerWiefel DE, Hoyer P, Knebelmann B, Pirson Y, Grunfeld JP, Niaudet P, Cochat P, Heidet L, Lebbah S, Torra R, Friede T, Lange K, Muller GA, Weber M: Early angiotensin-converting enzyme inhibition in Alport syndrome delays renal failure and improves life expectancy. *Kidney Int* 81:494–501, 2012 pmid:22166847 [PubMed]
<https://jasn.asnjournals.org/content/24/3/364>
31. Gross O, Friede T, Hilgers R, Görlitz A, Gavénis K, Ahmed R, Dürr U: Safety and efficacy of the ACE-inhibitor ramipril in Alport syndrome: The double-blind, randomized, placebo-controlled, multicenter phase III EARLY PROTECT Alport trial in pediatric patients [published online July 1, 2012]. *ISRN Pediatr* doi:10.5402/2012/436046pmid:22811928 [PubMed]
<https://jasn.asnjournals.org/content/24/3/364>
32. Koepke ML, Weber M, Schulze-Lohoff E, Beirowski B, Segerer S, Gross O: Nephroprotective effect of the HMG-CoA-reductase inhibitor cerivastatin in a mouse model of progressive renal fibrosis in Alport syndrome. *Nephrol Dial Transplant* 22: 1062–1069, 2007pmid:17287218 [PubMed] <https://jasn.asnjournals.org/content/24/3/364>
33. Zeisberg M, Khurana M, Rao VH, Cosgrove D, Rougier JP, Werner MC, Shield CF, Werb Z, Kalluri R: Stage-specific action of matrix metalloproteinases influences progressive hereditary kidney disease. *PLoS Med* 3: e100, 2006pmid:16509766
<https://jasn.asnjournals.org/content/24/3/364>
34. Ninichuk V, Gross O, Reichel C, Khandoga A, Pawar RD, Ciubar R, Segerer S, Belemzova E, Radomska E, Luckow B, Perez de Lema G, Murphy PM, Gao JL, Henger A, Kretzler M, Horuk R, Weber M, Krombach F, Schlöndorff D, Anders HJ: Delayed chemokine receptor 1 blockade prolongs survival in collagen 4A3-deficient mice with Alport disease. *J Am Soc Nephrol* 16: 977–985, 2005pmid:15716328 [PubMed]
<https://jasn.asnjournals.org/content/24/3/364>
35. Gross O, Koepke ML, Beirowski B, Schulze-Lohoff E, Segerer S, Weber M: Nephroprotection by antifibrotic and anti-inflammatory effects of the vasopeptidase inhibitor AVE7688. *Kidney Int* 68: 456–463, 2005pmid:16014022 [PubMed]
<https://www.ncbi.nlm.nih.gov/books/NBK1207/>
36. Sugimoto H, Mundel TM, Sund M, Xie L, Cosgrove D, Kalluri R: Bone-marrow-derived stem cells repair basement membrane collagen defects and reverse genetic kidney disease. *Proc Natl Acad Sci U S A* 103: 7321–7326, 2006pmid:16648256
<https://jasn.asnjournals.org/content/24/3/364>
37. Prodromidi EI, Poulsom R, Jeffery R, Roufosse CA, Pollard PJ, Pusey CD, Cook HT: Bone marrow-derived cells contribute to podocyte regeneration and amelioration of renal

disease in a mouse model of Alport syndrome. *Stem Cells* 24: 2448–2455, 2006
pmid:16873763 [PubMed] <https://jasn.asnjournals.org/content/24/3/364>

UNDER PEER REVIEW