Permanent Junctional Reciprocating Tachycardia in Infants from Myocarditis-like Presentation to Simple Tachycardia: A Case Series

ABSTRACT

Permanent Junctional Reciprocating Tachycardia (PJRT) is a rare type of supraventricular tachycardia. It can be misdiagnosed and hence under-treated in infants and children, leading to significant cardiac morbidities and mortalities. We describe four cases of young infants who presented with a wide range of clinical scenarios from neonatal tachycardia to overtly decompensated heart failure, all caused by PJRT. All cases showed complete recovery with appropriate medical treatment. In this case series, we aim to discuss the diversity of clinical presentations, and the challenges surrounding the diagnosis, management, and prognosis. To achieve this aim, we have also performed a detailed literature review and reflected on our cases presented to our center between 2016 to 2020. PJRT is rare; it is often missed or diagnosed late in the presentation. Hence, the key is to keep it in mind in infants presenting with acute cardiac problems from simple tachycardia to a myocarditis-like presentation. Anti-arrhythmic medications are safe and effective as first-line therapy for PJRT in neonates and infants. They can prevent or delay the need for invasive cardiac ablation, which is more challenging in these age groups and should be considered in cases refractory to medical treatment.

Keywords: Permanent junctional reciprocating tachycardia; supraventricular tachycardia; myocarditis; dilated cardiomyopathy; anti-arrhythmic medications.

1. INTRODUCTION

Permanent Junctional Reciprocating Tachycardia (PJRT) is a rare and lethal form of refractory and persistent supraventricular tachycardia (SVT). It represents 1% of all SVTs. SVT's estimated incidence ranges from 1 in 250 to 1 in 25000 children [1, 2]. The tachycardia is incessant in most cases, ranging from 120-250 beats/minute. This is due to anterograde conduction through the atrioventricular (AV) node and His-Purkinje system, returning retrogradely through the slowly conducting accessory pathway, usually near the ostium of the coronary sinus [1,3,4]. The Electrocardiogram (ECG) characteristics of PJRT include inverted P waves in the inferior leads (II, III, AVF) and long R-P interval compared to P-R interval. The PR interval is never prolonged, with normal and narrow QRS complexes and 1:1 AV ratio (no dissociation) (Fig. 3). Furthermore, the rate is slower than typical SVT, which can be confused with sinus tachycardia or atrial tachycardia.

PJRT is typically persistent rather than paroxysmal (>12 hours/day). It typically shows a brief slowing of tachycardia as a response to vagal maneuvers and adenosine with rapid recurrence shortly afterward. During the sinus rhythm episodes, the PR interval is normal, with no evidence of delta wave [1,3,5]. Investigative workup for PJRT requires careful attention to electrocardiographic changes. Patients often need serial ECGs, Holter study, and echocardiogram to assess cardiac function.

Outlines of management include medical therapy in the form of anti-arrhythmic medication or invasive cardiac ablation. Delay in diagnosis and effective treatment can lead to refractory heart failure and dilated cardiomyopathy, which can be reversible with appropriate diagnosis and effective therapeutic measures [1,3,5–7].

In this case series, we illustrate the challenges we have faced in diagnosing and managing PJRT in newborns and infants. We also emphasize the treatable nature of this pathology with adequate treatment. We aimed to alert neonatologists, general pediatricians, and pediatric intensivists; to identify and suspect this rare and lethal albeit treatable type of arrhythmia, which can present differently from simple tachycardia to heart failure with or without cardiogenic shock.

2. CASE PRESENTATIONS

2.1 Case 1

A three-month-old female infant presented to the Emergency Room (ER) with a history of irritability and shortness of breath. Her mother observed fast heartbeats for a few days. The baby was irritable, distressed, tachycardic (HR 230 bpm), and tachypneic (RR 60 bpm). Her SPO2 92% on room air and blood pressure (BP) 83/54(61) mmHg. Her pulses were rapid and palpable, the apex was displaced with gallop sound, and no murmur. There was evident tender hepatomegaly 4 cm palpable below the costal margin (BCM). Her ECG showed narrow QRS complex tachycardia, suggestive of SVT and the electrolytes levels were normal (Na= 139 mEq/L, K= 4.1 mEq/L, Ca= 9.3 mg/dL, Mg= 1.7 mEq/L); chest X-ray showed cardiomegaly and congested lung fields. She did not respond to vagal maneuvers or adenosine and was started on amiodarone infusion and transferred to the Pediatric Intensive Care Unit (PICU).

Further workup included echocardiography (Echo), which showed severely dilated and impaired left ventricular (LV) function, ejection fraction (EF) of <10% (Fig. 1), and severe mitral regurgitation (MR). Her troponin I was high 2.7 ng/ml (normal range below 0.04 ng/ml) with a modest elevation of other cardiac enzymes as well. Her serum viral screening was positive for rhinoviruses and adenoviruses, which gave an impression of acute myocarditis. She received milrinone, standard heart failure medications (Furosemide, Spironolactone, and Captopril), intravenous immunoglobulins (IVIG), and continued on amiodarone infusion.

A few hours after admission to PICU, she developed signs of cardiogenic shock and multi-organs failure that required advanced critical care support (Table 1). She remained persistently tachycardic with HR > 180 bpm despite amiodarone infusion, which was stopped later on due to high liver enzymes and impaired thyroid function (hypothyroidism). Our initial impression of her rhythm strips on the monitor was probable compensatory sinus tachycardia due to acute myocarditis. However, after careful reviewing of serial ECGs, we concluded that these findings were consistent with PJRT. Then, digoxin and esmolol infusion were started on day 5 post-admission. The patient showed a dramatic response with reverting to normal sinus rhythm with no further episodes of tachycardia. A few days later, esmolol was substituted with oral propranolol. She was followed up by serial Echocardiograms, which reassuringly showed a gradual improvement of her LV function (ultimately achieving EF of 63%).

The patient was extubated successfully after two days of controlling her arrhythmia. All inotropes were weaned off, and she was discharged after 19 days of hospitalization. She is now quite well on anti-arrhythmic medications, with regular follow up at a tertiary center with an electrophysiologist (EP).

2.2 Case 2

A forty-day-old boy previously well presented to ER with a two days history of irritability, interrupted feeding, and shortness of breath. He was irritable, tachycardic (HR 210 bpm), tachypneic (RR 62 bpm), afebrile with normal blood pressure. He maintained good oxygen saturation on room air. His heart sounds were normal, but he had a soft (grade 2) systolic murmur along with fine bi-basal crackles and hepatomegaly (4 cm BCM). The initial diagnostic impression was congestive heart failure secondary to SVT. Subsequently, he received adenosine with a transient response and was admitted to PICU. His echo showed a severely impaired LV function (EF 26%). This presentation raised suspicion of acute myocarditis as a differential diagnosis of tachyarrhythmia-induced cardiomyopathy and he managed accordingly (Table 1). He was discharged after nine days on oral amiodarone and standard heart failure medications. He was re-admitted after one week from the outpatient department to PICU again due to persistent tachycardia. Serial ECGs were reviewed and showed signs suggestive of PJRT, confirmed by Holter study and EP consultation.

Table 1. Illustrate the clinical findings (history, examination, investigations and therapeutic measures in the four cases diagnosed as permanent junctional reciprocating tachycardia)

	Case 1	Case 2	Case 3	Case 4
Neonatal history & examination				
Pregnancy	Term 39 week GA[5]	Term 40 weeks GA	Preterm 36 week GA	Preterm 36week GA
Delivery	Elective C/S[7]	Emergency C/S	Mother had SLE[6]	Twins pregnancy +

	Case 1	**Case 2**	**Case 3**	**Case 4**
			+ Emergency C/S	Emergency C/S
Birth weight	3.17 kg	3 kg	2.76 kg	2.1 kg
Abnormal fetal finding	No	Fetal distress	Persistent Fetal tachycardia	No
Post natal complications	No	No	No	Birth asphyxia (resuscitation) RDS[8] (Mechanical ventilation)
Clinical finding				
Age at diagnosis	95 days	73 days	12 days	14 days
Number of days to reach diagnosis	Day 4	Day 32	Day 12	Day 14
Duration of Admission	17 days	17 days	23 days	42 days
Heart failure				
Interrupted feeding	+	+	-	-
Shortness of breath	+	+	-	-
Irritability	+	+	-	-
Sweating	+	+	-	-
Tachycardia (Maximum heart rate)	+ up to (230 BPM)[9]	+ up to (210 BPM)	+ up to (210 BPM)	+ up to (230 BPM)
Tachypnia	+	+	-	-
Signs of respiratory distress	+	+	-	-
Cardiac murmur	-	+	-	-
Hepatomegaly	+	+	-	-
Gallop rhythm	+	-	-	-
Anti-failure medications	+	+	-	-
Shock				
Hypotension	+	-	-	-
Prolong CRT[1]	+	-	-	-
Weak pulses	+	-	-	-
Signs of multiorgan failure	+	-	-	-
Mechanical ventilation	+	-	-	-
Inotropes	+ (adrenalin + milrinon + nor-adrenalin)	+ (milrinon)	-	-
IVIG[2]	+	+	-	-
Investigations				
CXR[3]	Cardiomegaly + Congested lungs	Cardiomegaly + Congested lungs	Normal	Normal
ECHO[4] (admission)	Impaired function (FS[10] 4 % EF[11] 9%)	Impaired function (FS 13% EF 26%)	Normal function (FS 35% EF 71%)	Normal function (FS 34% EF 67%)
ECHO (discharge)	(FS 32% EF63%)	(FS 32% EF 63%)	(FS 34% EF 67%)	(FS 36% EF 72%)
Diagnosis work up	-Serial ECGs (in patient) -EP[12] consultation	-Serial ECGs (in patient) -Holter study (in patient) -EP consultation	-Serial ECGs(in patient) -Holter study(in patient) -EP consultation	-Serial ECGs (in patient) -Holter study (in patient)

	Case 1	Case 2	Case 3	Case 4
	-Tertiary center referral	-Tertiary center referral	-Tertiary center referral	-Tertiary center referral
Tachyarrhythmia Therapy				
Vagal stimulation	+	+	-	-
Adenosine	+	+	-	-
Cardio-version/shock	-	-	-	-
Amiodarone	+	+	+	-
Esmolol	+	-	-	-
Digoxin	+	-	-	-
Propranolol	+	+	+	+
Flecainide	-	+	-	-

(1) Capillary refiling time; (2) Intravenous immunoglobulin; (3) Chest x ray; (4) Echocardiography; (5) Gestational age; (6) Systemic Lupus erythromatosis; (7) Caesarean section; (8) Respiratory distress syndrome; (9) Beat per minute; (10) Fractional shortening; (11) Ejection fraction; (12) Electrophysiology; '+' Present '-' Absent

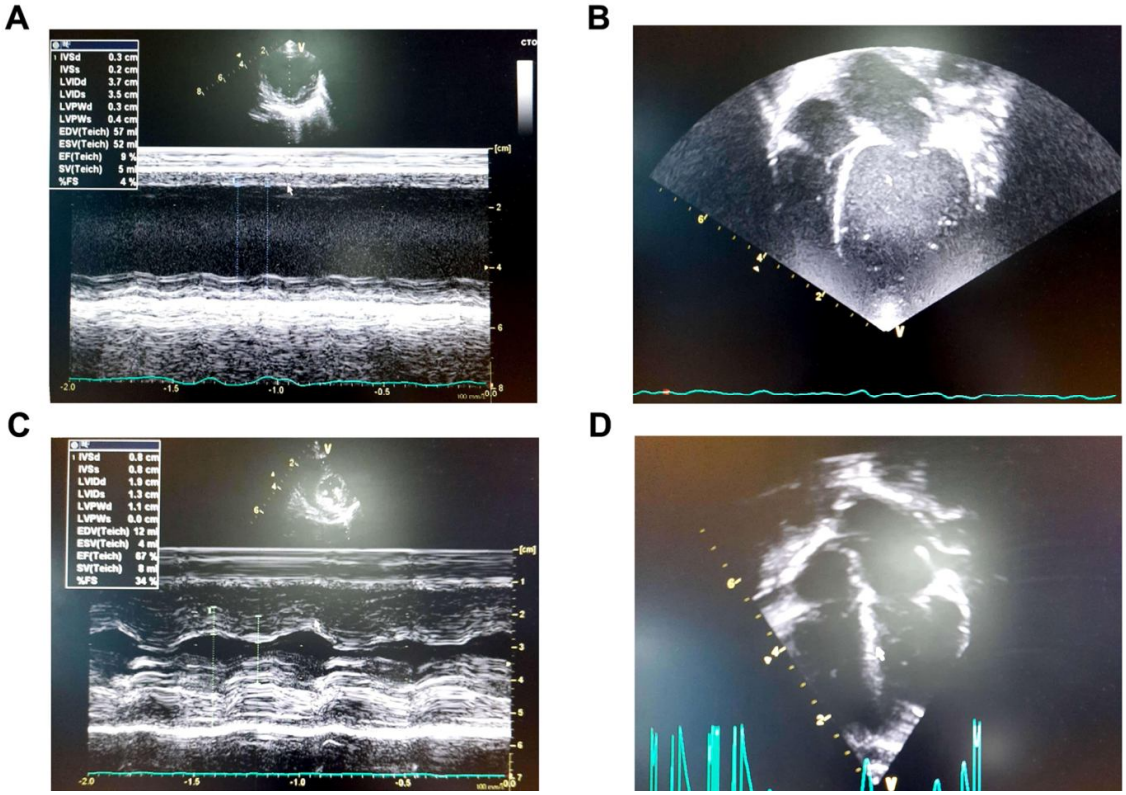

Fig. 1. Echocardiography finding in case 1. (A and C) M Mood (A) showed sever depressed Left Ventricle (LV) function with fractional shortening FS 4% and ejection fraction EF 9% on admission and (C) showed normal LV function with FS 34% and EF 67% on discharge. (B and D) Apical four chambers view (B) showed dilated Left Atrium (LA) and LV on admission and (D) showed balanced ventricles and resolved dilatation of LA and LV on discharge

Similar to case 1, his cardiac function and rhythm normalized after amiodarone and esmolol infusion. He was subsequently referred to a tertiary cardiac center for further evaluation. He is now three years old with no hospitalization admission due to this arrhythmia, he had achieved complete recovery, currently not on any anti-arrhythmic therapy. On routine follow-up at our center and a tertiary center.

2.3 Case 3

A late preterm boy (36-week Gestational age GA) was admitted to the neonatal intensive care unit (NICU) for observation post-emergency cesarean section indicated by persistent fetal tachycardia. His tachycardia persisted postnatally (HR 200-210 bpm) while being observed in NICU. He was clinically stable; his cardiovascular and other systems examinations were unremarkable.

His echocardiogram showed patent foramen ovale and normal LV function (Table 1). He was initially suspected as a case of ectopic atrial tachycardia, however, further ECGs and Holter study (Fig. 2) confirmed the diagnosis of PJRT on day 11 of life. He was started on propranolol and amiodarone infusion initially, then oral amiodarone, and discharged after 23 days with adequate control.

He continued to be followed up in a tertiary cardiac center. He is four years old now and is currently not on any medications.

2.4 Case 4

A late preterm second twin boy (36-week GA) was born by emergency cesarean section due to twin pregnancy and pre-eclampsia. He required advanced resuscitation and mechanical ventilation for a few days due to respiratory distress syndrome. He had frequent paroxysmal tachycardia (HR reached up to 220 bpm) with no signs of decompensation. His cardiovascular and other systems examinations were unremarkable. His serial ECGs raised suspicion of PJRT (Fig. 3). This diagnosis was confirmed by Holter study. His echocardiogram was normal. He was controlled with propranolol monotherapy, which was stopped at a later stage after achieving complete recovery. He is three years old now and continues to be followed up at a tertiary cardiac center.

3. DISCUSSION

PJRT can present with a diverse and wide range of clinical presentations, ranging from simple tachycardia and tachycardia-related symptoms to decompensated heart failure with or without cardiogenic shock. It has been observed in preterm babies, neonates, infants, or older children [5,6,8–11].

The first case in this series illustrates the critical presentation of PJRT with acute myocarditis-like presentation manifested by cardiogenic shock, severe LV dysfunction, pulmonary edema, and multi-organ failure (Fig. 1, Table 1). Obtaining the correct diagnosis, in this case, was crucial, not only to inform appropriate treatment but also to predict prognosis with a high degree of accuracy in this critical presentation. While the prognosis of cardiogenic shock secondary to myocarditis is very poor, in contrast, cardiogenic shock secondary to PJRT has a favorable prognosis. Hence, this changes not only the plan of management but also the aspects of counseling families about prognosis. We were fortunate to have had the experience of dealing with previous cases of PJRT (case 2), which helped us suspect it a lot earlier in this case. This positively impacted the management and outcome and was appreciated by the family and the treating team.

Alan G. Magee reported one case of a 17-months old infant with an acute myocarditis-like presentation that required ventilation, inotropes, and heart failure therapy. The patient responded well to anti-arrhythmic treatment after he was diagnosed with PJRT. He recommends careful evaluation of rhythm in any infant with myocarditis or cardiomyopathy [11]. Barbero AH et al. investigated the long-term outcome of neonates and infants with PJRT; they found that 16 out of a total of 129 patients were referred initially with SVT to have PJRT in the period from 2000 to 2015. One patient presented with cardiogenic shock in early infancy – similar to case (1)- that required advanced intensive care, and he underwent cardiac ablation at the age of three years after admission again with cardiogenic shock [6].

Critical presentations secondary to PJRT have also been reported in the adult population. Two cases (64 years old and 31 years old) were reported in 2016 and 2020, one of them had presented with cardiogenic shock that required high doses of inotropes, vasopressors, and Extracorporeal Membrane Oxygenation (ECMO). Both were diagnosed with PJRT and required cardiac ablation to control their arrhythmias and restore cardiac function [12,13].

Fig. 2. Part of Holter study in case 3 with Permanent Junctional reciprocating Tachycardia (PJRT), arrows showed inverted P wave in lead 111 with longer RP interval and narrow complex tachycardia with 1:1 Atrio-Ventricular (AV) ratio

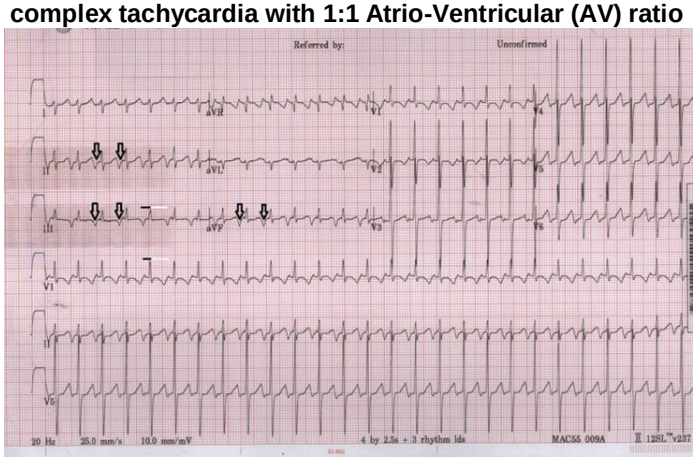

Fig. 3. 12 lead electrocardiography ECG in case 4, ECG demonstrate Permanent Junctional Reciprocating Tachycardia (PJRT) features, arrows showed inverted P wave in inferior leaders 11, 111, AVF and positive P wave in AVR , with longer RP interval (white horizontal lines) compare to PR interval (black horizontal lines) and narrow QRS complexes with 1:1 AV ratio (no dissociation)

The second case in this series illustrates the difficulty in diagnosing, controlling, and treating PJRT. Our patient presented with persistent tachycardia and heart failure with impaired LV function. It took 32 days and two hospital admissions until a diagnosis was made. Heart failure secondary to PJRT is well reported in the literature; Dorostkar PC reported 4 out of 11 patients, and Vaksmann G studied 24 out of 85 patients with congestive heart failure secondary to PJRT [4,5].

Due to the non-specific clinical presentations and the wide range of differential diagnoses in addition to the subtle ECG changes, spotting the diagnosis can often be challenging. PJRT can be misdiagnosed as either sinus tachycardia where the heart rate is slower than typical SVT [1] or as other types of incessant SVTs like atrial tachycardia (AT) or AV nodal reentrant tachycardia (AVNRT). Both AT and AVNRT share some ECG characteristics with PJRT, like narrow complex tachycardia and longer RP interval. Hence, careful ECGs evaluation and other investigations like Holter monitoring can help to confirm the diagnosis [11,14].

Despite the very good outcome with medical therapy, PJRT is usually challenging to control with monotherapy and often requires multiple medications or, on some occasions, invasive cardiac ablation [1,5–7,15]. In case (2), the

patient required multiple anti-arrhythmic medications to control PJRT (Table 1); he did not require cardiac ablation. Drago F reported successful medical treatment in 17 patients out of 19 with flecainide, amiodarone, propafenone, and sotalol as a single agent or in combination with propranolol and concluded that anti-arrhythmic medications might delay the need for radiofrequency ablation until the infants achieve adequate growth [15]. Van Stuijvenberg et al. studied 21 patients with a median age of 0.05 years and reported complete recovery in (67%) and partial recovery in (20%) of the cases to propafenone alone or combined with digoxin. The authors concluded that radiofrequency ablation could be delayed to a safer age [16]. In a large multicenter study, including 85 children - most of them were infants - diagnosed with PJRT (with or without heart failure), pharmacological treatment with amiodarone and verapamil alone or in combination with digoxin, were found to be effective in up to 94% of the cases [5].

The third and fourth cases demonstrate the value of early diagnosis in two neonates diagnosed with PJRT (Table 1). Fetal arrhythmias represented 0.6-2% of all pregnancies and can cause serious complications [6]. The third case presented prenatally with fetal tachycardia, which led to preterm delivery by emergency cesarean section. On the other hand, the fourth case was diagnosed after persistent tachycardia postnatally. Both patients' cardiac function was preserved, and the control of their PJRT was relatively easy with medical therapy.

Perinatal diagnosis of PJRT is not uncommon. J. Cornette et al. reported a case of fetal dilated cardiomyopathy secondary to PJRT diagnosed after delivery (EF at birth was only 10%). Complete recovery with the combination of digoxin and amiodarone was achieved at the age of 5 months [17]. Similarly, Barbero et al. studied infants younger than two-month with SVT. Amongst 16 patients with PJRT, ten patients were detected prenatally to have fetal tachycardia. 80% of mothers received pharmacological therapy to control fetal tachycardia, and 75% of the patients required combination therapy [6].

All four cases in this series were controlled medically and did not require cardiac ablation therapy, which is consistent with Vaksmann G and Drago F results where the success rates of pharmacological therapy were (84-94%) and 89.5 %, respectively [5,15]. In contrast, Barbero AH study had a success rate with less than 50% medical therapy, with 56.3% of the infants' required cardiac ablation at some stage [6]. The success rate of ablation therapy in children is high, about 80-93 %; however, recurrence of PJRT post-ablation is possible and may indicate more than one intervention for complete cure [1,6,7]. The overall prognosis in different clinical circumstances was reassuring with effective therapy [1,4–7,15].

4. CONCLUSION

The appropriate evaluation of ECGs in any infant with tachycardia, dilated cardiomyopathy, and myocarditis can be the turning point in the course of the diagnosis, management, and overall outcome. Pharmacological therapy is effective and safe in patients with PJRT, and it can help to delay the need for invasive cardiac ablation therapy. Radiofrequency ablation has a high success rate but can be technically challenging in neonates and young infants.

CONSENT AND ETHICAL APPROVAL

The study protocol conforms to the ethical guidelines of the 1975 Declaration of Helsinki as reflected in a priori approval by the institution's ethical review board. Written and informed consent was obtained from the patient's parents for publishing these case reports including accompanying images.

COMPETING INTERESTS

Authors have declared that no competing interests exist.

REFERENCES

1. Kylat RI, Samson RA. Permanent junctional reciprocating tachycardia in infants and children. J Arrhythmia. 2019;35:494-8.
2. Salerno JC, Seslar SP. Supraventricular tachycardia. Arch Pediatr Adolesc Med. 2009;163:268-74.
3. Bonney WJ, Shah MJ. Incessant SVT in children: ectopic atrial tachycardia and permanent junctional reciprocating tachycardia. Prog Pediatr Cardiol. 2013;35:33-40.
4. Dorostkar PC, Silka MJ, Morady F, Dick M. Clinical course of persistent junctional reciprocating tachycardia. J Am Coll Cardiol. 1999;33:366-75.
5. Vaksmann G, D'Hoinne C, Lucet V, Guillaumont S, Lupoglazoff J-M, Chantepie A, et al. Permanent junctional reciprocating tachycardia in children: A multicentre study

on clinical profile and outcome. Heart. 2006;92:101-4.

6. Barbero AH, Cesar S, Martinez-Osorio J, Margarit A, Moreno J, Campuzano O, et al. Long-term outcome of neonates and infants with permanent junctional reciprocating tachycardia. When cardiac ablation changes natural history. J Electrocardiol. 2019;56:85-9.
7. NOë P, VAN DRIEL V, Wittkampf F, Sreeram N. Rapid recovery of cardiac function after catheter ablation of persistent junctional reciprocating tachycardia in children. Pacing Clin Electrophysiol. 2002;25:191-4.
8. Press S, Lipkind RS. Acute myocarditis in infants: Initial presentation. Clin Pediatr. 1990;29:73-6.
9. Dancea AB. Myocarditis in infants and children: A review for the paediatrician. Paediatr Child Health. 2001;6:543-5.
10. Ross RD, Bollinger RO, Pinsky WW. Grading the severity of congestive heart failure in infants. Pediatr Cardiol. 1992;13:72-5.
11. Magee AG. Cardiomyopathy in Infants: Case-based management of potential pitfalls, look at the rhythm, then look again. Practical Pediatric Cardiology. Chapter 23: Springer. 2016:155-60.
12. Boulé S, Détis N, Lamblin N. Permanent junctional reciprocating tachycardia: A rare, but not to be missed, cause of cardiogenic shock in adults. Eur Heart J Acute Cardiovasc Care. 2016;2048872 616676604.
13. Kauh B, Leventhal A, Hesselson A. A rare case of permanent junctional reciprocating tachycardia in an adult who presents in cardiogenic shock. J Am Coll Cardiol. 2020;75:2624.
14. Yagishita A, Hachiya H, Higuchi K, Nakamura T, Sugiyama K, Tanaka Y, et al. Differentiation of atrial tachycardia from other long RP tachycardias by electrocardiographic characteristics. J Arrhythmia. 2014;30:376-81.
15. Drago F, Silvetti MS, Mazza A, Anaclerio S, Di Pino A, Grutter G, et al. Permanent junctional reciprocating tachycardia in infants and children: effectiveness of medical and non-medical treatment. Ital Heart J. 2001;2:456-61.
16. Van Stuijvenberg M, Beaufort-Krol GC, Haaksma J, Bink-Boelkens MTE. Pharmacological treatment of young children with permanent junctional reciprocating tachycardia. Cardiol Young. 2003;13:408.
17. Cornette J, Ten Harkel A, Steegers EP. Fetal dilated cardiomyopathy caused by persistent junctional reciprocating tachycardia. Ultrasound in Obstetrics and Gynecology: Ultrasound Obstet Gynecol. 2009;33:595-8.

© 2022 Mohmmedahmed et al.; This is an Open Access article distributed under the terms of the Creative Commons Attribution License (http://creativecommons.org/licenses/by/4.0), which permits unrestricted use, distribution, and reproduction in any medium, provided the original work is properly cited.