

# Supraventricular tachycardia (SVT) in newborn leading to Hydrops fetalis syndrome: case report

### Abstract:

Hydrops fetalis is defined by the accumulation of fluids in the serous membranes (pleurisy, ascites, pericarditis...), it is a rare condition; its etiologies are divided into immunological and non-immunological. Supraventricular tachycardia remains a known cause, non-immunological, but difficult to manage.

In this article we report the case of a newborn with hydrops fetalis secondary to supraventricular tachycardia, which failed to be treated.

The clinical, paraclinical, etiological diagnosis and finally the treatment were discussed.

Keywords: Supraventricular, tachycardia, Hydrops fetalis

### Introduction

Hydrops fetalis is defined by the collection of excessive fluid in two separate fetal compartments. It alludes to a surplus of bodily water, which is usually demonstrated by an extracellular accumulation of fluid in tissues and serous cavities. [1]. "The pathophysiology of Hydrops Fetalis can be classified according to immune and nonimmune etiology. Nonimmune hydrops fetalis (NIHF) refers specifically to cases not caused by red cell alloimmunization, rather than being a diagnosis, NIHF is a clinical characteristic. It includes cardiovascular etiology and can be divided into 4 categories: structural heart disease; cardiomyopathies; fetal arrhythmias; and vascular disorders" [2]. "There are several forms of tachyarrhythmias; the most common are benign and curable, but those that are life-threatening require early and appropriate management; these are listed as follows: supraventricular tachycardias (SVTs); atrial flutter (AF); ventricular, junctional, or chaotic atrial tachycardias, and bradyarrhythmias" [3].

In our case, we describe an uncommon, a fatal and difficult to manage cardiac etiology of non-immune hydrops fetalis which is a supraventricular tachycardia.

### Case presentation

A 35+3-week female baby was born by caesarean section for worsening hydrops fetalis (HF) detected in the third trimester of pregnancy. Prenatal ultrasound showed an extrasystole with abundant peritoneal effusion. At delivery, APGAR score was 8/10, she immediately developed respiratory distress, transient hypotonia, and received nasal continuous positive airway pressure. Physical examination showed tachypnoea (70 breaths/min) and a moderate generalized subcutaneous edema. Chest X-ray showed a cardiothoracic index of 0.67 with sign of pleural effusions (figure 2). An abdominal ultrasound shows a moderate ascites. At 10 min of life, her heart rate was 230–280 per minute. An ECG showed a

paroxysmal supraventricular tachycardia (PSVT) with narrow complexes (figure 1). We begin with vagal maneuvers, amiodarone and furosemide however it was ineffective, consequently we opted for electric cardioversion with good results. The heart rate decreases to 180-200 per minute. We also proceeded to do the ascites puncture, which shows a transudate fluid, the thyroid hormones and the serologic viral screening was normal. Echocardiography showed severe tricuspid insufficiency and dilated right cardiac chambers. After 24 hours the baby presents a general edema, then signs of heart failure and died.

## Discussion

“Hydrops fetalis is usually divided into two categories: Immune and non-immune hydrops fetalis. The most important etiologic factor for immune hydrops fetalis is Rh isoimmunization and this is markedly decreased in the past three- four decades by the effective administration of prophylactic regimens; currently most of the hydrops fetalis cases were in the category of non-immune group and the etiology of these are multifactorial” [4]. 10% to 20% of patients of non-immunologic hydrops fetalis had cardiac etiologies. [1], [5] These include arterial calcification, cardiac arrhythmias, tumors, physiological dysfunction brought on by infection, inflammation, and infarction, in addition to anatomical abnormalities. The right atrial pressure or volume overload caused by cardiac and intrathoracic lesions that cause hydrops fetalis appears to be most frequently linked to these conditions. According to Krapp et al. [6], “among fetal tachyarrhythmias, fetal arrhythmia’s made up 26.2% and SVTs made up 73.2%. Hydrops fetalis was found in 38.6% of fetuses with AF and 40.5% of fetuses with SVT”.

“The most typical tachycardia connected to NIHF is fetal supraventricular tachycardia. The majority of these (90%) involve accessory-pathway-related atrioventricular reentrant tachycardia. A fetal heart rate of more than 220 beats per minute (bpm) results in decreased cardiac output, reduces tissue oxygenation, and raises central vein pressure due to decreased ventricular filling” [7]. “A conducted study by Veeral and AL concluded that the prognosis of hydrops fetalis mortality depends on the etiology, and showed that 13.1% died from a cardiac arrhythmia, much lower compared to those with a cardiac malformation (40.9%), however the most fatal etiology remains the atrioventricular canal defect (88.9%)” [8].

“Ascites, pleural effusion, pericardial effusion, or generalized skin edema are signs of hydrops fetalis that can be detected by prenatal ultrasound. Ultrasonographic examinations are frequently carried out during the second and third trimesters of pregnancy since. Magnetic resonance imaging (MRI), three- and four-dimensional ultrasonography, and other imaging modalities have been researched as potential means to enhance prenatal identification of concomitant structural anomalies” [9], [10]. “Once NIHF has been recognized, it is critical to identify the underlying cause and establish whether a suitable therapeutic strategy exists. In as many as 60% to 85% of cases, prenatal and postnatal assessment can pinpoint the cause” [11].

Vagal maneuvers are used to treat SVT and are followed by boluses of adenosine followed by antiarrhythmic medication (digoxin, amiodarone, or all three) or electrical cardioversion.

Deciding to begin maintenance therapy is determined by the tachycardia and the severity of the episodes. Mechanism, adverse drug effects, and treatment being typically kept up

until age one. Ablation using a radiofrequency catheter is a sensible option for newborns with lifethreatening arrhythmias or refractory SVT[12].

In our case the SVT responds initially to vagal maneuvers and electric cardioversion, but this condition worsened.

The long-term forecasts were evaluated in only two studies. In a group of 107 live-born instances, Haverkamp et al. (2000) examined the psychomotor growth of 28 of the 61 surviving infants. Four of the 28 (14%) kids showed signs of neurological morbidity. Two had modest neurological impairment, and two more had spastic cerebral palsy. In a series of 51 newborns with NIHF, Nakayama et al. (1999) investigated 19 survivors beyond the age of one year; 3 of them (16%) showed severe psychomotor development delay and 3 had mild retardation.

Consequently, nonimmune hydrops fetalis (NIHF) now accounts for almost 90% of hydrops cases. However, Mortality of NIHF remains high ranging between 55% and 90%, depending on the cause.

### Conclusion

Understanding the etiology of NIHF is important for effective management in pregnancies, and in the neonatal period as both morbidity and mortality depend on the underlying cause[13]. Although diagnosis has advanced over time, there are still a sizable percentage of idiopathic instances.

While morbidity and mortality are still high, some of these illnesses are treatable in utero while others need neonatal systemic support and time to recover.

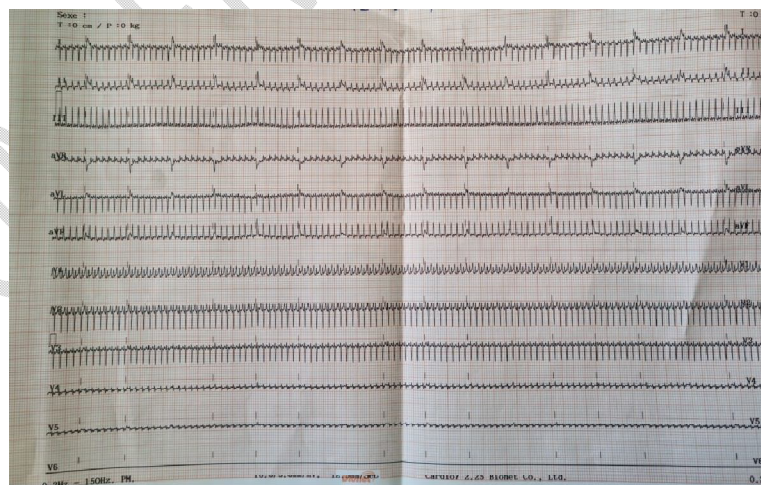


FIGURE 1: Chest Xray showing an ICT= 0.67 and sign of pleural effusion

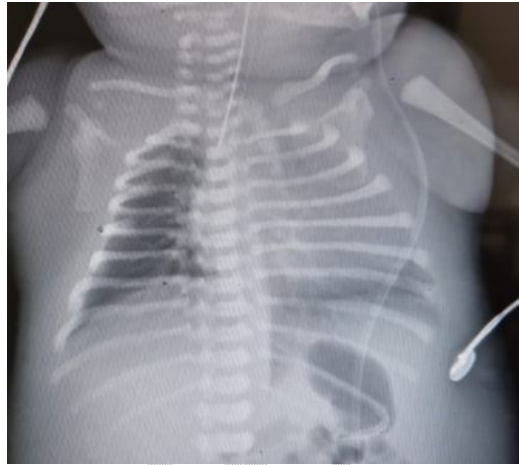


FIGURE 2: ECG showing a supraventricular tachycardia

**Ethical Approval:**

As per international standard or university standard written ethical approval has been collected and preserved by the author(s).

**Consent**

As per international standard or university standard, patient (s) written consent has been collected and preserved by the author(s).

## References

- [1] G. A. Machin, « Hydrops revisited: Literature review of 1, 414 cases published in the 1980s », *Am. J. Med. Genet.*, vol. 34, n° 3, p. 366–390, 1989.
- [2] C. Swearingen, Z. A. Colvin, et S. R. Leuthner, « Nonimmune Hydrops Fetalis », *Clin. Perinatol.*, vol. 47, n° 1, p. 105–121, mars 2020, doi: 10.1016/j.clp.2019.10.001.
- [3] « Fetal arrhythmias - PubMed ». <https://pubmed.ncbi.nlm.nih.gov/10822185/> (consulté le 16 octobre 2022).
- [4] C. Çetin, Ç. Akçabay, S. Büyükkurt, et N. Özbarlas, « Successful medical treatment of fetal supraventricular tachycardia that cause hydrops fetalis », *Turk. J. Obstet. Gynecol.*, vol. 11, n° 3, p. 193, 2014.
- [5] T. K. Knilans, « Cardiac abnormalities associated with hydrops fetalis », in *Seminars in perinatology*, 1995, vol. 19, n° 6, p. 483–492.
- [6] M. Krapp, T. Kohl, J. M. Simpson, G. K. Sharland, A. Katalinic, et U. Gembruch, « Review of diagnosis, treatment, and outcome of fetal atrial flutter compared with supraventricular tachycardia », *Heart*, vol. 89, n° 8, p. 913–917, 2003.
- [7] A. Randenberg, « Nonimmune hydrops fetalis part I: etiology and pathophysiology », *Neonatal Netw.*, vol. 29, n° 5, p. 281–295, 2010.
- [8] V. N. Tolia *et al.*, « Hydrops fetalis—trends in associated diagnoses and mortality from 1997–2018 », *J. Perinatol.*, vol. 41, n° 10, p. 2537–2543, 2021.
- [9] F. V. White *et al.*, « Congenital disseminated malignant rhabdoid tumor: a distinct clinicopathologic entity demonstrating abnormalities of chromosome 22q11 », *Am. J. Surg. Pathol.*, vol. 23, n° 3, p. 249–256, 1999.
- [10] A. H. Mardy, S. P. Chetty, M. E. Norton, et T. N. Sparks, « A system-based approach to the genetic etiologies of non-immune hydrops fetalis », *Prenat. Diagn.*, vol. 39, n° 9, p. 732–750, 2019.
- [11] C. Bellini et R. C. Hennekam, « Non-immune hydrops fetalis: a short review of etiology and pathophysiology », *Am. J. Med. Genet. A.*, vol. 158, n° 3, p. 597–605, 2012.
- [12] E. Battistuz *et al.*, « Newborn with hydrops fetalis and a severe supraventricular arrhythmia », *Arch. Dis. Child.-Educ. Pract.*, vol. 106, n° 2, p. 103–104, 2021.
- [13] A. M. Quinn, B. N. Valcarcel, M. M. Makhamreh, H. B. Al-Kouatly, et S. I. Berger, « A systematic review of monogenic etiologies of nonimmune hydrops fetalis », *Genet. Med.*, vol. 23, n° 1, p. 3–12, 2021.