

Original Research Article

Anaesthetic and Histological Effects of Lidocaine Hydrochloride On *Oreochromis niloticus* Juveniles

Comment [B1]: Replace with on

ABSTRACT

This study investigated the toxicity of Lidocaine Hydrochloride-sodium Bicarbonate (LHB) on *Oreochromis niloticus* juveniles (20.75g). The histological tissue examinations were used to assess the effects of the anaesthetic agent (LHB) on the fish after exposure. Varying concentrations of LHB in increments of 10mg/L ranging from 60mg/L to 100mg/L were used for the static bioassay. There was a decrease in induction and recovery time with an increasing concentration of LHB showing a significant positive correlation ($R^2= 0.9721$; $p<0.05$) and ($R^2= 0.7338$; $p<0.05$) respectively. Anaesthetic values of LHB for *O. niloticus* at an induction time of less than 4 minutes and recovery time of less than 3 minutes were observed. No mortality occurred during the experiment. Histological examination of the gills, liver and kidney of *O. niloticus* after exposure showed different pathological changes. The gills and liver of the fish exposed to 100 mg/L concentration showed no sign of histological changes. However, the results obtained showed a severe histological effect on the kidney of juveniles *Oreochromis niloticus* at 100 mg/L of LHB

Key words: Anaesthesia, Exposure, Lidocaine hydrochloride-sodium bicarbonates

Comment [B2]: Add more relevant key words

1.0 INTRODUCTION

Comment [B3]: Remove 0

Anesthetics are a type of sedative that helps to prevent stress and physical harm (Ross and Ross 2009). Researchers are highly concerned about the suffering fish endure due to the handling and aquaculture industry's rapid global expansion (Ashley, 2007). Therefore, from a scientific perspective, the use of anesthetics is very necessary and has developed into a practice in the aquaculture business; as a result, it may be impossible to imagine exposing fish to different stressors without anesthetics (Velek *et al.*, 2009). Aquaculture fish are subject to a variety of stressors, including chemical, biological, physical, and procedural stressors (Obirikorang *et al.*, 2020). Fish raised in intensive culture systems are subjected to a variety of acute and chronic stresses, which have a negative impact on their ability to develop, reproduce, and have immune systems that are competent (Barton *et al.*, 1987; Maule *et al.*, 1989; Shreck *et al.*, 2001; Iwama *et al.*, 2006). These particular stressors for fish in aquaculture include chemical factors like poor water quality, biological factors like illnesses, physical factors like temperature changes, and procedural factors like selection or sorting. The procedural stressors that are created by routine management procedures in fish farming are the most common and cause stress in fish, necessitating the use of anaesthetic. The condition known as anaesthesia prevents the senses, including the ability to feel pain, entirely or partially (Neiffer and Stamper, 2009). Addition of an anesthetic chemical to water, which is comparable to inhalation anesthesia in terrestrial animals,

is the most often employed anesthetic approach in aquaculture. The anaesthetic is absorbed into the bloodstream by breathing, causing numbing of the senses and promoting blood circulation. The gills, kidney, digestive tract, and skin are used for the excretion of the remaining metabolites. To determine the effectiveness of various anesthetics, fish of various sizes were utilized. Both common anesthetics like MS-222, Benzocaine, Eugenol, Clove oil, 2-phenoxyethanol PE), Lidocaine hydrochloride, sodium bicarbonate (LHB), and others, as well as unconventional substances like the alcoholic and aqueous tobacco extracts and crude marijuana leaf extract (Small, 2003, Abbas *et al.*, 2006, Opiyo *et al.*, 2013, Agokei and Adebisi, 2010, Audu *et al.*, 2013). A proven anesthetic agent in aquaculture due to its significant efficacy and accessibility is lidocaine hydrochloride. Lidocaine hydrochloride's toxicity profile is also easily accessible (Park *et al.*, 2006). In freebase form, it is easily soluble in acetone or alcohol but insoluble in water. It is typically utilized in the form of a salt called hydrochloride, which is freely soluble in water (Merck and Company, 1989). Nevertheless, buffering agents are necessary for lidocaine hydrochloride to neutralize the pH and so increase efficacy (Ferreira *et al.*, 1984) and avoid metabolic acidemia, a state brought on by anesthesia-induced hypoxemia and anaerobic metabolism (Neiffer and Stamper, 2009). Sodium bicarbonate (NaHCO_3), the buffering agent, is a white powder that quickly dissolves in water to release carbon dioxide gas. It also goes by the name "baking soda." Sodium bicarbonate is widely accessible, affordable, non-toxic, and secure for use by people (Pawar *et al.*, 2013). The purpose of the current study is to ascertain the anesthetic effects of lidocaine hydrochloride buffered with sodium bicarbonate on juvenile *O. niloticus* through its effectiveness in terms of induction and recovery time, behavioral changes during exposure, and histological effects at various concentrations.

2.0 MATERIALS AND METHODS

Comment [B4]: Remove

Collection of Experimental fish

A total of one hundred and twenty (120) *O. niloticus* juveniles with mean weight of 20.75g were obtained from the Teaching and Research Fish Farm, Department of Fisheries and Aquaculture Technology, Federal University of Technology Akure, Nigeria. They were kept in a plastic tank for 24 hours to acclimatize them to the laboratory condition prior to the experiment.

2.1 Lidocaine hydrochloride

Commercial lidocaine hydrochloride solution (2% solution) was obtained from Matador Dafon Pharmaceutical Limited, Akure, Nigeria. Its active ingredients are 2- [diethylamino]-*N*-2,6-dimethylphenyl acetamide hydrochloride and its concentrations were expressed in mg/l.

2.2 Water quality parameters

The selected water quality parameters such as temperature, pH, dissolved oxygen and conductivity were analyzed using Multi-purpose thermometer (Model: YSI 550) and Searchtech Instruments, Model PHS-3C, Model YSI 550 DO, and Model DDS-307, for pH, DO and conductivity respectively using standard methods (APHA, 1989).

2.3 Experimental procedure

A preliminary experiment was conducted to determine whether Lidocaine hydrochloride would be effective or not as anaesthesia for fish. One gram per litre (1g/l of Sodium bicarbonate (NaHCO_3)) was added to each treatment and stirred to dissolve completely before adding Lidocaine hydrochloride solution to each treatment at the concentration of 60mg/l, 70mg/l, 80mg/l, 90mg/l and 100mg/l respectively. NaHCO_3 was added to increase the efficacy of the anesthetic agent and to serve as a buffering effect because of the acidic nature of the anesthetic agent. Ten (10) fish were randomly selected and placed in each plastic tank with 10 L of water containing the anaesthetic agent to determine the induction time. The four stages of anaesthesia indicated in Table 1 were achieved based on the dose and the length of exposure (Shawn *et al.*,

2004). The induction time of anaesthetization and recovery were recorded during the experiments. The concentration of Lidocaine hydrochloride buffered with NaHCO₃ at which *O. niloticus* juveniles reached sedation in the least induction time and with the highest recovery time and 100% survival was chosen as the maximum level of Lidocaine hydrochloride to be used. After anaesthesia, the fish were removed and placed in the recovery tanks (anaesthetic-free tanks) and recovery time was recorded. The fish were maintained for 48 hours to observe possible mortality. Behavioural responses of the test organisms were observed during the exposure to the anaesthetic agent.

Table 1: The four stages of anaesthesia and the behavioural response of juveniles of *O. niloticus* exposed to different concentrations of Lidocaine hydrochloride-sodium bicarbonate.

STAGE	CONDITION	BEHAVIOUR/RESPONSE
I	Sedation	Motion and breathing reduced
II	Anaesthesia	Partial loss of equilibrium Reactive to touch stimuli
III	Surgical anaesthesia	Total loss of equilibrium No reaction to touch stimuli
IV	Death	Breathing and heart beats stop Overdose-death

Source: Shawn *et al.*, 2004

Comment [B5]: Replace with after
After Shawn *et al.*, 2004

2.4 Histological examination of tissues

The samples of gills, liver and kidney of *O. niloticus* juveniles exposed to Lidocaine Hydrochloride-Sodium bicarbonate were examined at the Histopathology laboratory, Department of Veterinary Anatomy, University of Ibadan, immediately after the experiment. The samples were preserved in 10% formaldehyde prior to the microscopic examination. The preserved organs were dehydrated in graded level of alcohol (50%, 70%, 90% and 100%) after which they were cleared in mixture of alcohol and xylene (each of same volume) for 3 hours; then 100% xylene for 3 hours. The specimen was then impregnated in molten and placed in the oven for 6 hours after which they were embedded in petri-dishes with wax. The specimens were then mounted on wooden blocks and sectioned with the aid of a microtome of 7 microns sections before staining in haematoxylin stain. The specimens were sectioned into thin sections with the aid of microtome prior to staining in haematoxylin eosin stain. The stained specimens were observed under a light microscope at different magnifications (x400) and the photographs of slides were taken.

Linear regression and graph was used to analyze the data collected in order to determine the relationship between the concentration of LHB and the induction and recovery time. Water quality parameters data collected were analyzed using One Way Analysis of Variance (ANOVA) to test the significant differences using Duncan Multiple Range Test (DMRT). Pearson correlation was calculated using SPSS Version 20. All tests, except the histopathological analysis, were carried out at 5% level of probability.

3.0 RESULTS AND DISCUSSION

3.1 Behavioral activities

Comment [B6]: Remove

When fish were exposed to LHB, swimming activity generally decreased. Some fish were stationary while others swam erratically in a circular pattern. The fish remained in an oblique position with partial loss of equilibrium. After a while, the fish fell flat on their sides with rapid opercula movements and finally were insensitive to external stimuli with no opercula movements. The fish recovery signs started with opercula movements which is slow, steady and the movements in the head and tail region to maintain normal lateral position.

3.2 Induction and recovery time

Table 2 shows induction and recovery time of the test fish for each dose of LHB. The induction time decreased with increasing concentrations of LHB (Table 2). The recovery time also decreased with increasing concentrations of LHB with 100% survival rate after 24 hours.

Table 2: The Relationship between the Induction and Recovery time of *O. niloticus* juveniles exposed to different concentration of Lidocaine hydrochloride-sodium bicarbonate.

Concentrations (mg/L)	Induction time (min)	Recovery time (min)
Control	-	-
60	35.34±2.84	4.86±1.95
70	31.08±2.76	3.85±0.83
80	24.18±1.58	4.19±2.65
90	11.70±5.15	3.93±2.50
100	3.74±0.76	2.69±2.25

Figures 1 and 2 shows the relationship between the concentration of Lidocaine hydrochloride-sodium bicarbonate and induction time and recovery time. Both have a positive linear effect with significant correlation of $R^2 = 0.9721$ and $R^2 = 0.7338$ ($P < 0.05$) respectively.

As the concentrations of Lidocaine hydrochloride increased, the pH and the conductivity increased, the dissolved oxygen (DO) decreased while there were fluctuations in the temperature as presented in Table 3. The conductivity of the test solution increased rapidly after the anaesthetic agent was administered. The increase in pH and conductivity were because of the addition of the buffering agent to the anaesthetics while the decrease in dissolved oxygen can be as a result of the by-product of NaHCO_3 given off as CO_2 which increases the pH leading to rapid opercula movement of the fish during anaesthesia.

Table 3: Water parameters of different concentrations of Lidocaine hydrochloride-sodium bicarbonate used during the experiment

Concentration (mg/L)	Temperature ($^{\circ}\text{C}$)	pH	DO (mg/l)	Conductivity (uS/cm)
Control	30.25±0.07 ^a	6.49±0.01 ^a	5.25±0.21 ^c	21.25±0.07 ^a
60	30.30±0.00 ^a	7.62±0.01 ^b	3.45±0.35 ^b	120.80±2.12 ^b
70	30.40±0.57 ^a	7.51±0.02 ^b	3.20±0.14 ^{ab}	124.70±0.28 ^c
80	30.40±0.28 ^a	7.57±0.07 ^b	3.05±0.07 ^{ab}	128.50±2.26 ^d

Comment [B7]: Bold with reduce font size 10

90	30.30±0.14 ^a	7.58±0.13 ^b	3.50±0.28 ^b	130.20±0.14 ^d
100	30.25±0.07 ^a	7.64±0.01 ^b	2.85±0.2 ^a	130.75±0.07 ^d

Different superscript in each column indicate significant differences (P<0.05).

Comment [B8]: Bold with reduce font size 10

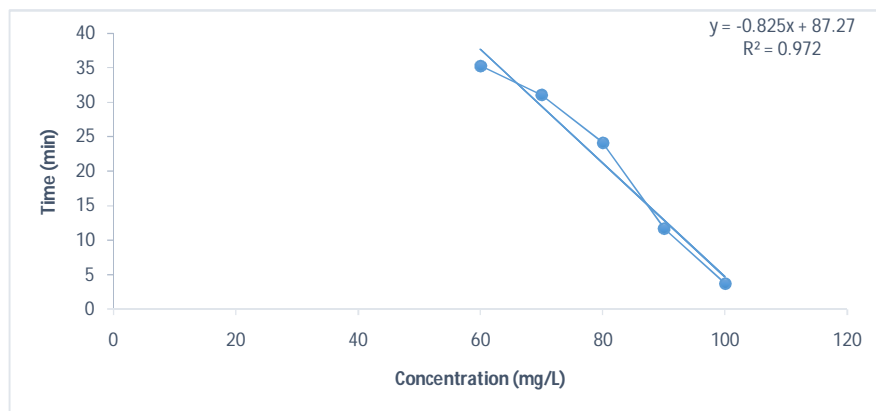


Figure 1: Relationship between Concentration and Induction time of *O. niloticus* juveniles exposed to different concentration of Lidocaine hydrochloride-sodium bicarbonate

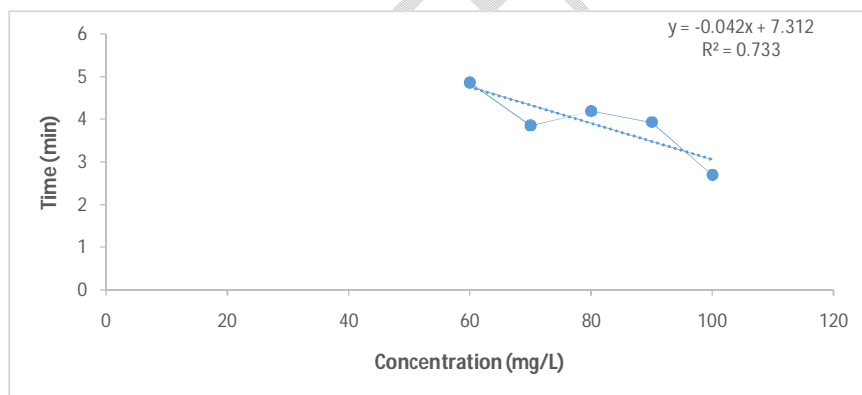


Figure 2: Relationship between Concentration and recovery time of *O. niloticus* juveniles exposed to different concentration of Lidocaine hydrochloride-sodium bicarbonate.

3.3 Histological examination

Experimental fish exposed to LHB showed no lesions in the gills of the control fish (Plate 1) and 100mg/L concentration (Plate 6). Other concentrations (60, 70, 80, and 90mg/L) of LHB showed severe, mild to moderate erosion of the gill mucous membrane (Plates 2-5). No lesions were

observed in the kidney of the control and 90mg/L concentration (Plates 7 and 11). There were moderate to severe congestion of the renal blood vessel of fish exposed to concentrations of 70mg/L, 80mg/L and 90mg/L (Plate 8, 9 and 10). Epithelial degeneration of the renal tubules was seen in 100mg/L concentration (Plate 18). In the liver of experimental fish, no lesion was seen in the control (Plate 13). Concentrations of 80mg/L and 100mg/L (Plate 16 and 18) also show no lesion but concentration of 90mg/L (Plate 17) had prominent melanomacrophage centres. The liver of fish exposed to 60mg/L and 70mg/L showed moderate to severe haemorrhage in the liver parenchyma and portal and sinusoid congestion (Plates 14 and 15).

Comment [B9]: Make single plates and all figs must be included in it. Their information should be given under single legend.

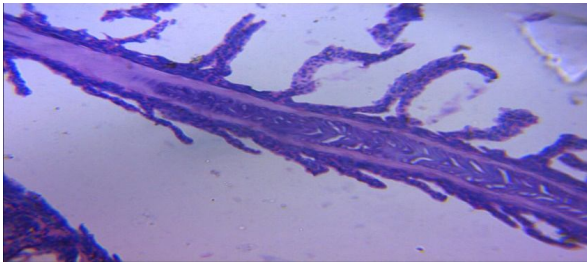


Plate 1: Gills of *O. niloticus* in the control experiment shows no signs of lesions. (Mg. x400).

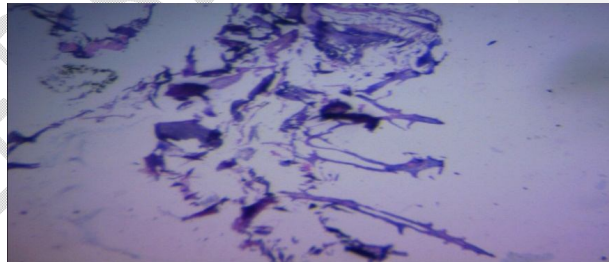


Plate 2: Gills of *O. niloticus* exposed to 60 mg/L of Lidocaine hydrochloride-sodium bicarbonate shows severe erosion of mucous membrane. (Mg x400)

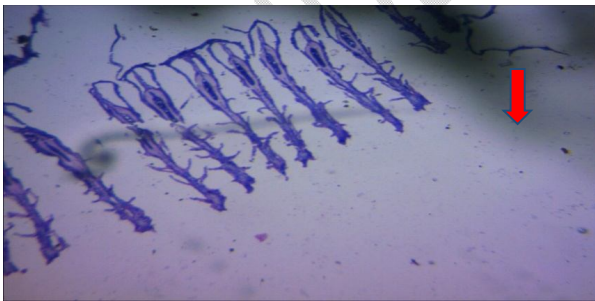

Plate 3: Gills of *O. niloticus* exposed to 70 mg/L of Lidocaine HCL-sodium bicarbonate shows mild to moderate erosion of gill mucous membrane (Mg x 400)

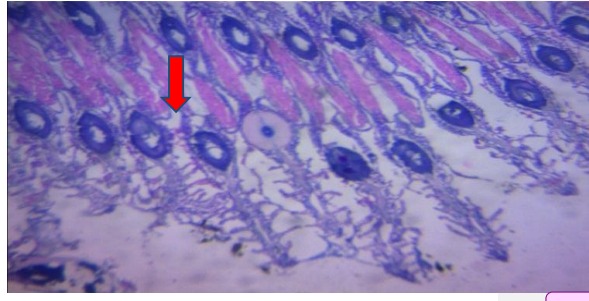


Plate 4: Gills of *O. niloticus* exposed to 80 mg/L of Lidocaine HCL-sodium bicarbonate shows mild to moderate erosion of gill mucous membrane though the primary lamellae is normal (Mg x 400)

Comment [B10]: All photographs must come under single plate (make plate in corel draw). Don't stretch the figs, better to enhance their pixels. Scale bar is missing. Use Scale bar to represent exact dimension of the figures.

Plate 6: Gills of *O. niloticus* exposed to 100 mg/L of Lidocaine HCL-NaCO₃ shows no signs of any lesions (Mg x400)

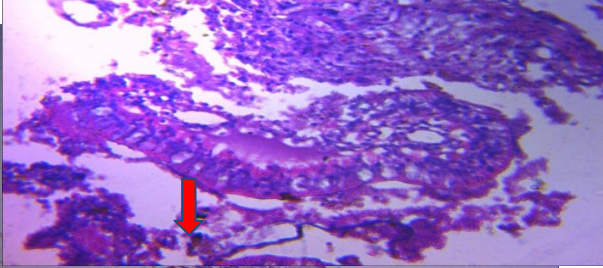


Plate 7: Kidney of *O. niloticus* in the control shows no signs (Mg x400)

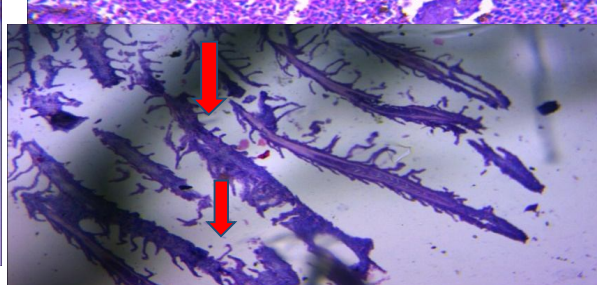


Plate 8: Kidney of *O. niloticus* exposed to 60mg/L of HCL-NaCO₃ shows severe congestion of the renal blood vessels and some areas are haemorrhagic (Mg x400).

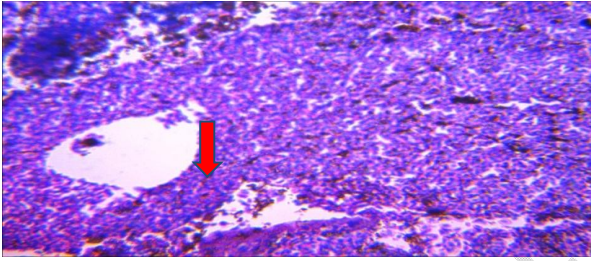


Plate 9: Kidney of *O. niloticus* exposed to 70mg/L of Lidocaine HCL- NaCO₃ shows severe congestion of the renal blood vessels (Mg x400).

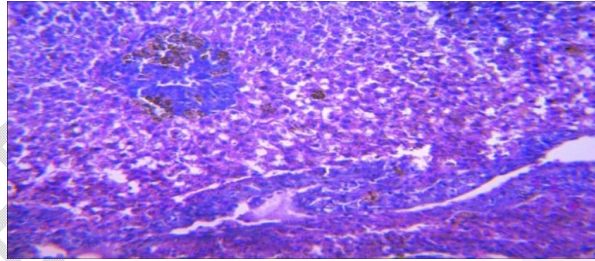


Plate 10: Kidney of *O. niloticus* exposed to 80mg/L of Lidocaine HCL-NaCO₃ shows moderate congestion of the renal blood vessels (Mg x400)

Plate 5: Gills of *O. niloticus* exposed to 90 mg/L of Lidocaine HCL- NaCO₃ shows mild erosion of gill

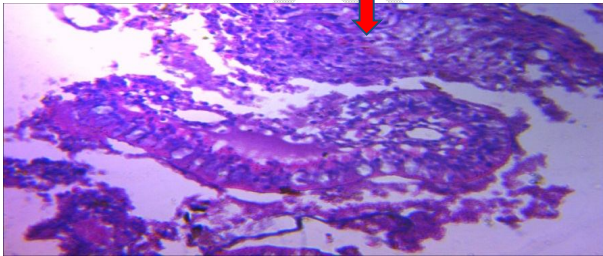


Plate 11: Kidney of *O. niloticus* exposed to 90mg/L of Lidocaine hydrochloride-sodium bicarbonate shows no signs of any lesions (Mg x400).

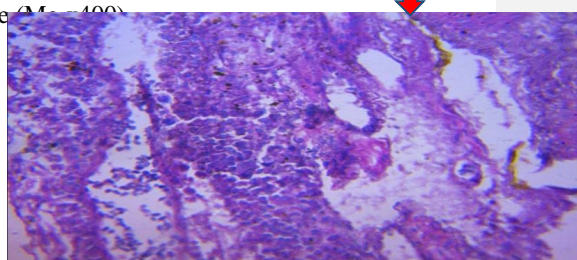


Plate 12: Kidney of *O. niloticus* exposed to 100mg/L of Lidocaine hydrochloride-sodium bicarbonate shows severe epithelial degeneration of the renal tubules (Mg x400).

Comment [B11]: Don't use red arrow as it is hampering the quality of Figs.

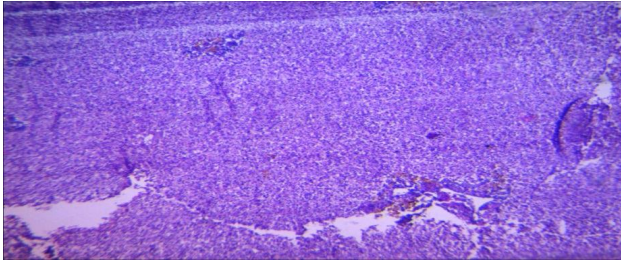


Plate 13: Liver of *O. niloticus* in the control shows no sign of lesions (Mg x400)

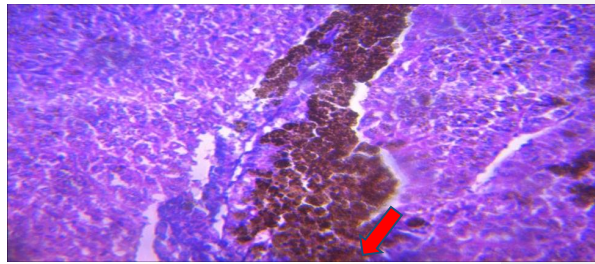


Plate 14: Liver of *O. niloticus* exposed to 60mg/L of Lidocaine HCL-NaCO₃ shows moderate to severe hemorrhage in the liver parenchyma (Mg x400)

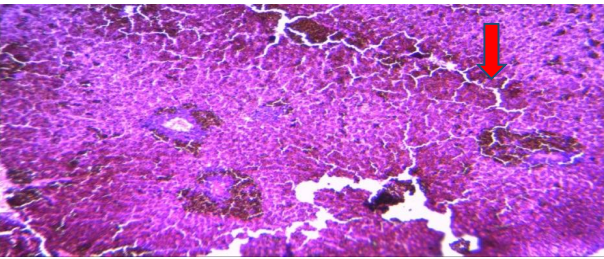


Plate 15: Liver of *O. niloticus* exposed to 70mg/L of Lidocaine HCL NaCO₃ shows severe portal and sinusoidal congestions (Mg x400).

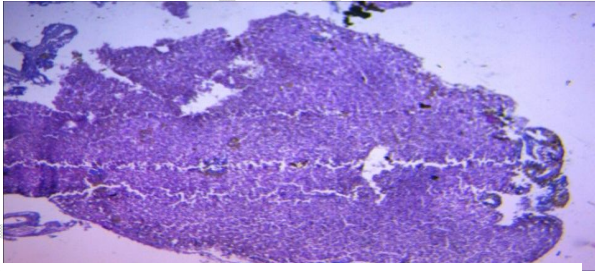
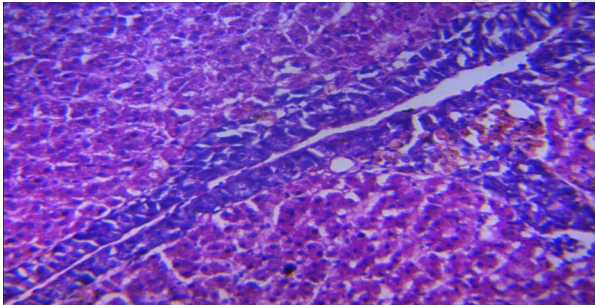


Plate 16: Liver of *O. niloticus* exposed to 80mg/L of Lidocaine HCL-NaCO₃ shows no signs of any lesions (Mgx400).



Plates 17: Liver of *O. niloticus* exposed to 90mg/L of Lidocaine HCL-NaCO₃ shows no signs of lesions but the liver had prominent melanomacrophage centres (Mg x400).

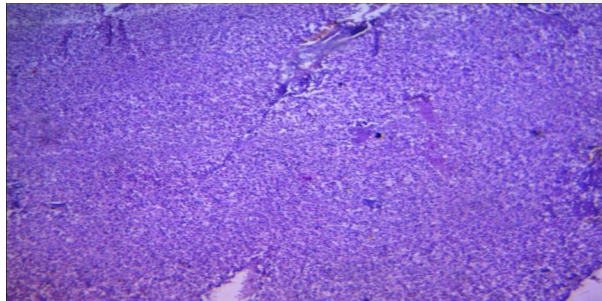


Plate 18: Liver of *O. niloticus* exposed to 100mg/L of Lidocaine HCL-NaCO₃ shows no signs of lesions (Mg x400)

One technique for reducing fish stress and for making aquaculture processes easier is the use of anesthetics (Husen et al., 2014). In the current work, *O. niloticus* induction and recovery times were calculated using LHB. Gilderhus (1989) claims that when placed in a recovery tank, induction time often lasts less than 4 minutes and recovery time typically lasts between 10 and 15 minutes. According to this study, LHB dosages of 60, 70, 80, and 90 mg/L can be utilized for moderately rapid anesthesia (20 min and 40 min), while doses of 100 mg/L can induce anesthesia in fish in less than 4 minutes. Chereen *et al.* (2014), on the other hand, reported that 325mg/L concentration of LHB produced Zebrafish (*Danio rerio*) in 365s (6.08 min). This is in agreement with Abbas *et al.* (2006) who used the same LHB concentration and Park et al. (2006) who used 1000 mg/L Lidocaine hydrochloride buffered with 1 g/L sodium bicarbonate to sedate soft-shelled turtles (*Pelodiscus sinensis*). Agokei and Adebisi (2010) exposed *O. niloticus* to alcoholic extract and aqueous preparation of tobacco and reported effective dosages of 6-7ml/L (alcoholic extract of tobacco) and 4-4.5g/L (aqueous preparation of tobacco), with an induction time of 2.40.54 and 3.20.14 minutes, respectively. This finding is consistent with the hypothesis that the *O. niloticus* induction time reduces with increasing LHB concentration. When compared to the induction time (3.740.74minutes) of 100mg/L of LHB employed in this investigation, the induction times of the alcoholic extract of tobacco and the aqueous preparation of tobacco were faster. According to Agokei and Adebisi (2010), alcoholic extract and aqueous tobacco preparation had no impact on the pH (6-7) and temperature (28.1.0oC) of the water, however lidocaine hydrochloride increased the pH, temperature, and conductivity of the water (as shown in Table 2). The use of sodium bicarbonate increases water's pH and is useful for anesthesia, according to Altun *et al.*, (2008). The healing time shortens when LHB concentration rises. When exposed to lidocaine hydrochloride, *O. niloticus* fingerlings recovered more slowly, according to Abbas *et al.*, (2006). This is as a result of the inability of the fish to rapidly eliminate the chemical from its body. The buffering effect of NaHCO₃ makes Lidocaine hydrochloride effective for rapid anaesthesia. This is consistent with Chereen *et al.*, (2014) experiment using Zebrafish to test the effectiveness of lidocaine hydrochloride buffered with sodium bicarbonate (*Danio rerio*). The recovery time of lidocaine hydrochloride slowed with a concentration increase from 325 mg/L to 350 mg/L, although there was mortality due to the stated limited margin of safety. In fish bodies, diffusion of sodium bicarbonate at low concentration caused a rapid recovery, according to Opiyo *et al.*, (2013). This is explained by the fact that anesthesia is unaffected significantly by CO₂ produced at low concentrations. However, the effectiveness of a particular anesthetic depends on the species of fish. Medaka fish can be rendered unconscious by giving them up to 800 mg/L of lidocaine hydrochloride, according to Chereen *et al.*, (2014). (*Oryzias dancena*). Histopathological alterations have been used as indicators of different chemical effects on different fish tissues, which reflect the health of the fish in the body of water (Pandey *et al.*, 2014). The extent of damage caused by any chemical or pollutant has been found to be dependent on the concentration and exposure duration of such chemical (Venkatesh and Ashok, 2010); which was noted by Nasiruddin *et al.*, 2012 that histopathological variations in different organs depend on the toxicity of the chemicals to which they are exposed to. The histopathological effect in *O. niloticus* juveniles exposed to varying concentrations of LHB showed varying degree gill erosion which ranges from severe, moderate to mild erosion of the gill mucous membrane. The severity increases with increasing time of exposure. The changes observed in the kidney of exposed to lidocaine hydrochloride-sodium bicarbonate showed an inconsistent histopathological effect with increasing concentration. There was severe epithelial degeneration of the renal tubules in fish exposed to the highest concentration (100mg/L). This agreed with El-Sherif and El-Feky (2008) who examined the kidney of Nile tilapia fingerlings after 75 days of exposure to un-ionized ammonia (NH₃-N)

Comment [B12]: Replace with last

which showed an increase in the thrombus formation and infiltration of melanomacrophage cells between the renal tubules. Additionally, there was significant glomerulosclerosis, hyaline droplet degeneration and swelling of the renal tubules, necrosis of the renal tubules, rupture of the melanomacrophage center, and disseminated melanomacrophage cells in the renal parenchyma. The alterations in the liver agreed with the results obtained by Saber *et al.*, 2004 and El-Sherif and El-Feky (2008). Wajsbrodt *et al.*, 1993 also reported that the histopathological effects of chronic toxicity of ammonia on the gills and liver function induces tissue hypoxia which may lead to reduction in fish growth.

Comment [B13]: Replace with induce

4.0 CONCLUSION

Comment [B14]: Remove 0

A cheap, non-toxic, commonly used chemical that is user-friendly, environmentally acceptable, and also easily accessible is lidocaine hydrochloride and sodium bicarbonate. They have each been employed separately to put various fish species, including reptiles, under anesthesia. Lidocaine hydrochloride's effectiveness has been demonstrated to be enhanced by the buffering effect of sodium bicarbonate (1g/L), which indicates rapid anesthetic agent elimination without adverse effects on organs as well as a decrease in the quantity or amount used for anesthesia when used separately.

5.0 REFERENCES

Comment [B15]: Remove 0

Abbas, H.H.H., Abdel-Gawad A.S. and Akkr, A. A. (2006). Toxicity and Efficacy of Lidocaine as an Anaesthetics for Nile Tilapia (*Oreochromis niloticus*). *Pakistan Journal of Biological Sciences* 9(12): 2236-2242.

Agokei O. E., and Adebisi A. A., (2010). Tobacco as an Anesthetic for Fish Handling Procedures. *Journal of Medicinal Plants Research* Vol. 4(14), pp. 1396-1399. <http://www.academicjournals.org/JMPR> DOI: 10.5897/JMPR09.380 ISSN 1996-0875

Comment [B16]: Why italics follow same pattern for referencing

APHA, AWWA and WPCF (American Public Health Association and Water Pollution Control Federation) (1989). Standard Methods for the Examination of Water and Waste Water. 17th Edition. APHA, Washington D.C, USA. 1391 pp.

Audu, B.S, Adamu K.M and Ufodike, E.B., (2013). Behavioural Response and Opercular Ventilation Rate of Nile Tilapia (*Oreochromis niloticus*) Fingerlings after Anesthesia with Crude Leaf Extract of Marijuana (*Cannabis sativa*). *Applied Science Research Journal*. Vol 1 (2) 66 – 77.

Barton BA, Shreck CB, Barton LD, (1987). Effects of chronic cortisol administration and daily acute stress on growth, physiological conditions and stress responses in Juvenile rainbow trout. *Disease Aquatic Organisms*, 2:173-185.

Chereen Collymore, Angela Tolwani, Christine Lieggi, and Skye Rasmussen (2014). Efficacy and Safety of 5 Anesthetics in Adult Zebrafish (*Danio rerio*). *Journal of the American Association for Laboratory Animal Science* 53 (2): 198–203.

Donald L. Neiffer and M. Andrew Stamper, (2009). Fish Sedation, Anesthesia, Analgesia, and Euthanasia: Considerations, Methods, and Types of Drugs. *ILAR Journal* 50 (4): 343-360.

- El-sherif, M.S. and El-feky, Amal M. (2008). Effect of Ammonia on Nile Tilapia (*O. niloticus*) Performance and some Hematological and Histological measures. *8th International Symposium on Tilapia in Aquaculture*.
- Ferreira JT, Schoonbee HJ, Smit GL. (1984). The uptake of the anesthetic benzocaine hydrochloride by the gills and the skin of three freshwater fish species. *Journal of Fish Biology* 25:35-41
- Gilderhus P.A. (1989) Efficacy of benzocaine as an anesthetic for salmonid fishes. *North American Journal of Fisheries Management* 9:150-153.
- In-Seok PARK, Sung Hwoan CHO, Jun Wook HUR, Gyeng-Cheol CHOI, Sung-Yong OH, Dong Soo KIM and Jae-Seong LEE, 2006. Lidocaine hydrochloride–sodium bicarbonate as an anesthetic for soft-shelled turtle (*Pelodiscus sinensis*). *Fisheries Science* 2006; 72: 115–118
- Iwama, G.K., Afonso LOB, Vijayan MM.(2006). Stress in fishes In: Evans DH, Claiborne JB (eds) *The physiology of fishes*. CRC Press Taylor and Francis, Boca Raton. Florida. 2006; 601pp.
- Mary A. Opiyo, Erick Ochieng Ogello and Harrison Charo-Karisa, 2013. Effectiveness of Sodium Bicarbonate as an Anaesthetic for different sizes of Nile tilapia (*Oreochromis niloticus* L., 1758) Juveniles. *International Journal of Aquatic Science ISSN: 2008-8019 Vol.4, No.2, 14-22*.
- Maule, A.G, Tripp R.A., Kaatarist, A.Y, and Shreck C.B., 1989. Stress alters immune functions and disease resistance in Chinook Salma (*Oncorhynchus tshawytscha*). *Journal of Endocrinology* 120: 135-142.
- Md. Akbal Husen and Subodh Sharma, 2014. Efficacy of anaesthetics for reducing stress in fish during aquacultural Practices- A Review. *Journal of Science, Engineering and Technology, Vol.10, No.1, pp 104-123*
- Merck and Company (1989). *The Merck Index*, 11th ed. 1606pp. Rahway, New Jersey: Merck and Company.
- Nasiruddin, Munira, Mohammad, Al, Azadi and Akllima Jahan (2012). Histopathological changes in the gill, liver and intestine of *Heteropneustes fossilis* (Bloch) treated with three dry seed extracts. *J. Asiat. Soc. Bangladesh Sci.* 38 (2) 217-226.
- Popoola, O, M and Olufayo, M. O., (2007). Histological changes in the Gills of *Oreochromis niloticus* Exposed to Promethazine Hydrochloride. *J. Fish. Aquat. Sc.* 2(5): 366-370, ISSN 1816-4927
- Pandey, Devenda N., Pandey, Neha and Shukla, Sandeep k. (2014). Histopathological changes in the gill tissue of the fish, *Labio rohita* exposed to untreated and treated Amlai paper mill effluent. *Indian Streams Research Journal* 4. (6) 1-4.
- Pawar H.B., Ingole B.S. and Sreepada R.A., (2013). Efficacy of sodium bicarbonate as anaesthetic for yellow seahorse, *Hippocampus kuda* (Bleeker, 1852). *International Journal of Research in Fisheries and Aquaculture* 3(3): 103-107.

Comment [B17]: Follow same pattern while writing journal namesexpand journal names everywhere where their short forms have been used in the references of the manuscript.

- Saber, A. El-Shafai, A. El-Gohary Fatma, A. N. Fayza, N. Peter van der Steen and J. G. Huub. (2004). Chronic ammonia toxicity to duckweed-fed tilapia (*O. niloticus*). *Aquaculture* 232: 117-127.
- Shreck CB; Wilfreds C, Fitzpatrick MS. (2001). Effect of stress on fish reproduction, gamete quality and progeny. *Aquaculture* 197:3-24.
- Small, B. C. (2003). Anesthetic efficacy of metomidate and comparison of plasma cortisol responses to tricaine methanesulfonate, quinaldine and clove oil anesthetized channel catfish (*Ictalurus punctatus*): *Aquaculture* 218: 177-185.
- Shawn D. Coyle, Robert M. Durborow and James H. Tidwell, 2004. Anesthetics in Aquaculture: Southern Regional Aquaculture Centre. SRAC Publication No. 3900
- Tülay Altun, Ramazan Bilgin, Durali Danabaş, (2009). Effects of Sodium Bicarbonate on Anaesthesia of Common Carp (*Cyprinus carpio* L., 1758) Juveniles: *Turkish Journal of Fisheries and Aquatic Sciences* 9: 29-31.
- Venkatesh, Chaturvedi and Ashok, Kumar (2010). Toxicity of Sodium dodecyl sulphate in fishes and animals: a review *International Journal of Applied Biology and Pharmaceutical Technology*.1 (2):630-634.
- Wajsbrodt, N., A. Gasith, A. Diamant and D. M. Popper. (1993). Chronic toxicity of ammonia to juvenile gilthead sea bream *Sparus aurata* and related histopathological effects. *J. Fish Biol.* 43,321 – 328.