

Case study

Venous hemangioma in hemilabium case report

Abstract

Infantile hemangiomas (IH) are benign tumorous vascular lesions of endothelial origin that appear in early childhood with a higher incidence in women than men. Affecting 8-12% of infants. Clinically, variables in size and shape are appreciated. Predominant in the skin, subcutaneous tissues, bone, liver and spleen. In rare cases, they even become ominous in appearance and generate functional disability that interferes with eating and language. The correct diagnosis is achieved through the clinic and diagnostic aids such as nuclear magnetic resonance imaging techniques. Treatment must be multidisciplinary. It depends on the size, location and style of the lesion. We present the case of a 6-year-old female patient with a three-year-long brown-colored increase in volume on her lower left lip. Which occurs intermittently with increase and dissemination of the lesion with exacerbation pictures. Which was treated surgically by the Department of Maxillofacial Surgery of the Children's Hospital of Morelia.

Key words: Hemangioma; Case report; Childhood; Vascular malformation.

Background

Infantile hemangiomas (IH) are benign vascular tumor lesions of endothelial origin. It commonly appears during early childhood with a higher incidence in women than men. Affecting 8-12% of infants. Clinically, variables in size and shape are appreciated. Predominant in the skin, subcutaneous tissues, bone, liver and spleen. And a non-odontogenic tumor of the blood vessels rarely found on the lip, where it is associated with ulcerative complications during the proliferative period, scarring and lip contour deformity. In rare cases, they even become ominous in appearance and generate functional disability that interferes with eating and language. What triggers psychological problems.¹⁻⁵

Erin CC, Fallon FS in 2016 described the risk factors to consider as: Caucasian ethnicity, female gender, prematurity, multiple management, low birth weight; increasing risk for every 500g of lower birth weight, increased maternal age, in-vitro fertilization, pre-eclampsia and placental abnormalities.⁶

In 2018, the International Society for the Study of Vascular Anomalies (ISSVA) obtained updated guidelines for the classification of vascular anomalies. In this we can find vascular tumors such as hemangioma, which in turn is subdivided into cavernous or capillary. And they can be classified into arterial, venous and capillary type.¹⁻³

Histopathologically, numerous thin-walled blood vessels with dilated blood vessel spaces, areas of hemorrhage, and chronic inflammatory cell infiltrate are seen.¹

The correct diagnosis is achieved through the clinic and diagnostic aids such as nuclear magnetic resonance imaging techniques.³

The differential diagnosis encompasses Veau-Walsh angiomas, nodular melanoma, and basal cell carcinoma.⁷

Treatment should be multidisciplinary, according to the size, location and style of the lesion, where different methods such as embolization, steroid therapy, cryosurgery and electrodesiccation can be used. However, the surgical option cannot be avoided. Dye lasers or neodymium-doped yttrium aluminum garnet lasers can also be used successfully for the lesion showing overgrowth.^{4,8}

Report or description of the case

A 6-year-old female patient is presented accompanied by her guardian who refers to starting her condition at birth, presenting 3 brown volume increases in the left corner of the lower lip, which manifests intermittently with increase and dissemination of the lesion with exacerbation pictures. Reason for which he goes to a private consultation where they specify that it is a tumor with a tendency to cancer. For this reason he goes to the Maxillofacial Surgery service of the Morelia Children's Hospital.

No relevant history for his current condition. On physical examination, a normocephalic skull was observed, exostoses and/or sinking were not palpable, symmetrical, complete eyebrows, orbital rim without a solution of continuity, eyes with isochoric pupils, with light reflexes of photomotor and consensual accommodation. Patent nostrils, no signs of deviation in the nasal septum, hyperemic oropharynx, hypertrophy, no retroload, no exudate. The patient presents an apparent chronological age, aligned, alert, oriented, neurologically in line with Glasgow 15. A 14x14mm lesion can be seen on the lower lip on the left side that makes the lips incompetent at closure, brown with Positive diascopy and slow capillary refill after pressure relief. Sessile based. It does not seem to be at the expense of the muscular plane, asymptomatic with a superficial lesion in the occlusal area. Intraoral examination shows multiple caries in the deciduous dentition. **(Figure 1)**

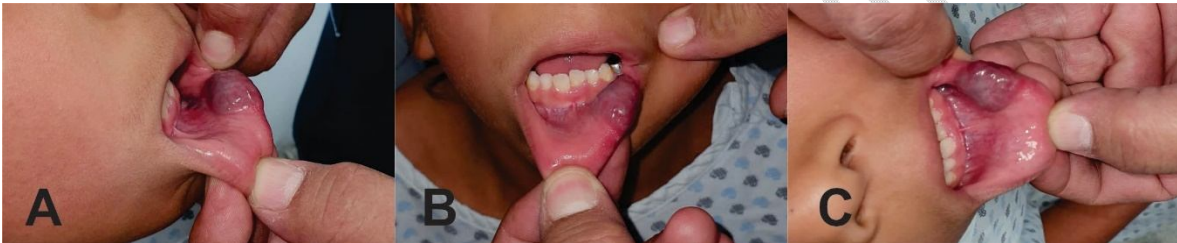

Figure 1: An increase in volume can be seen in the lower left lip, brown in color, with well-defined edges and a sessile base. A) Lateral view of the left lower lip showing an increase in volume that extends from the lip to the bottom of the sac. B) frontal view of the tumor lesion that extends from the midline to the corner of the lips. C) Superior view that extends from the vermilion of the lips to the mucosa of the oral cavity.

Laboratory studies: leukocytes 6.1(103/mm³), Hemoglobin 13 g/dL, platelets 315(103/mm³), group B+, prothrombin time 16.5sec, partial thromboplastin time 35sec

Diagnoses or clinical problems: lower left lip hemangioma, surgical time is scheduled after legal authorization and hospitalization is extended.

Histopathological: skin spindle measuring 2x0.7x0.6cm, dark brown, with a 0.5cm diameter violaceous lesion in the center. Being diagnosed venous hemangioma in the left lower lip.

After the surgical act, the tutor refers to a post-surgical evolution at 22 days of resection of the lip lesion, she refers to a good evolution, with 100% satisfaction with the result. On physical examination, the vermilion border is seen without a solution of continuity, an adequate white and red lip union with the presence of separation of the dry and wet lip in the process of fibrosis, no evidence of infection or bleeding from healing. **(Figure 2) (Figure 3)**

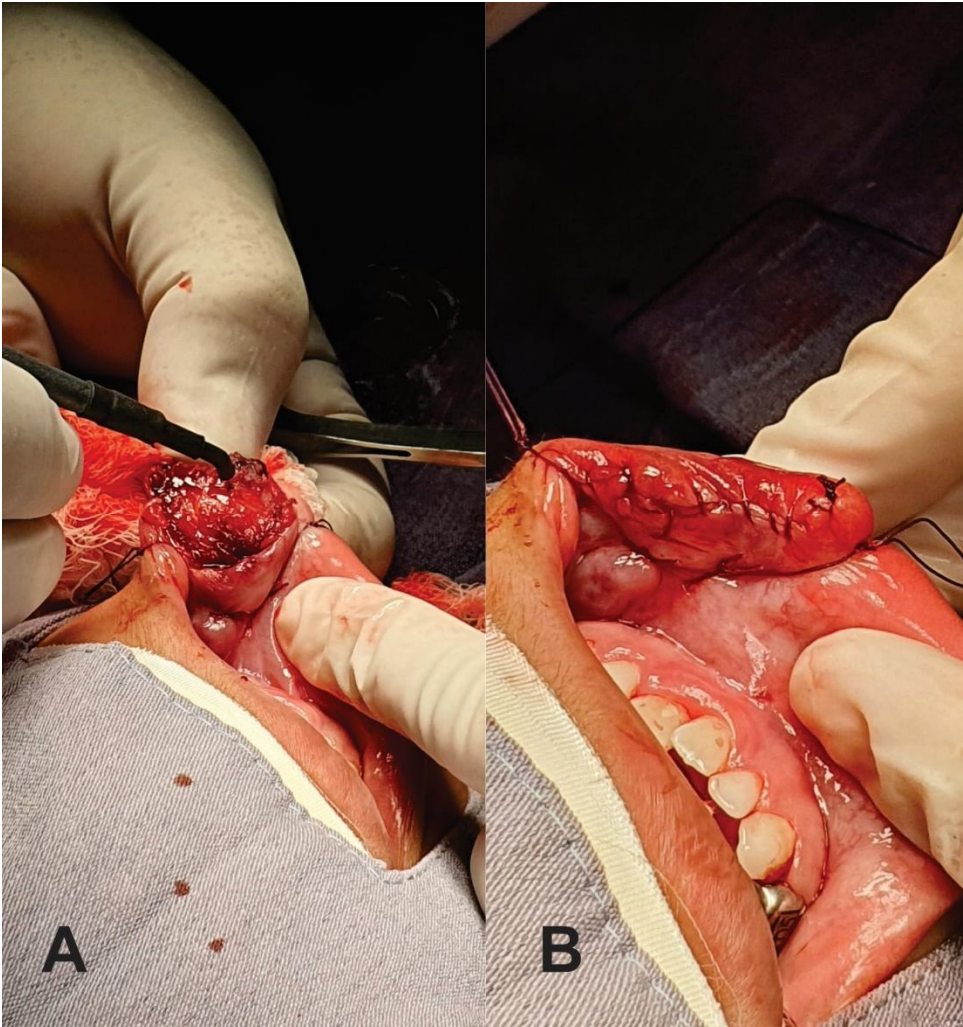


Figure 2: A) Surgical removal of the tumor present in the left hemilabium. B) Union of the anatomical planes after the surgical procedure.

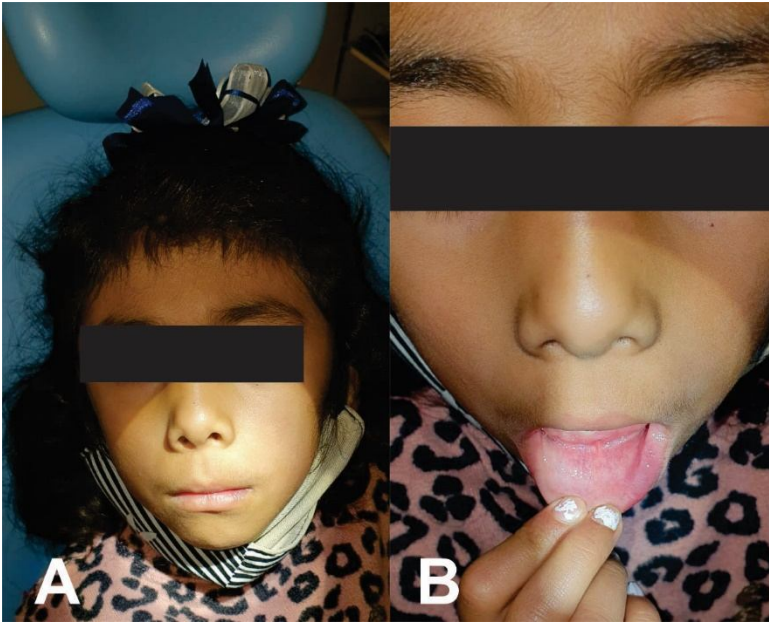

Figure 3: A) Post-surgical physical examination at 22 days, normochromic tissues are appreciated, without pathological data. B) Intraoral examination shows normochromic tissues, normothermic, without pathological data

Discussion

As mentioned by Yagoub AA, et al. 2022, hemangiomas are rarely recurrent within the oral cavity, and are even considered rare when they occur on the lips.¹

The surgical procedure was the treatment of choice due to the lack of sophisticated equipment to perform other procedures indicated in the literature.

The literature review shows that lip hemangiomas are rare pathological entities that compromise not only the physical appearance of the patient. But also, a multidisciplinary treatment must be carried out between doctors, maxillofacial surgeons and psychologists in order to identify the socio-emotional impact derived from the nosological condition.

Conclusion and recommendations

Multidisciplinary work is the best option for the treatment of pathological injuries that manifest in the fasciae. Therefore, it is necessary to refer patients to specialists in the health area.

Bibliography

1. Yagoub AA, Jaber AA, Mohammed AS, Ali AA, Mohammed AH, Mahmoud SH. Hemangioma in the lower labial vestibule of an eleven-year-old girl: a case report. *World Cases J Clin.* 2022;16(5):1617-1622.

2. Ochando IG, Azaña-Defez JM. Infantile hemangioma of the upper lip and enamel hypoplasia: report of two cases. *Pediatr Dermatol*. 2019;36(6):899-901.
3. Ujala UA, Diwakar NR. A very rare case of bilateral capillary hemangioma of the lower lip and face: A case report. *Indian Journal of Dental Research*. 2021;32(1):131-133.
4. Vazquez MP, Diner PA, Picard A, Soupre V, Enjolras O. Les levres angiomateuses angiomatous lips. *Annales de Chirurgie Plastique Aesthetics*. 2002;47(5):561-579.
5. Brentegani LG, Pardini LC, Salata LA, Rosa AL. Hemangioendothelioma of the lip. *Puerto Acta Med*. 1994;7(4):231-234
6. Erin CC, Fallon FS. Infantile hemangiomas, complications and treatments. *Seminars in Cutaneous Medicine and Surgery*. 2016;35(1):108-116.
7. Mangal S, Padhiar B, Karia U, Bela JS. Senile hemangioma of the lips. *Indian Journal of Dermatology*. 2014;59(6):633.
8. Chang JW, Kyu S, Heo, Woong-Lee JH. Wound closure with Dermabond after excision of hemangioma on the lip. *Medicine*. 2019;98(17):e15342