

## Case study

# 'BETTER LATE THAN NEVER'-A CASE REPORT ON DELAYED REIMPLANTATION OF AN AVULSED TOOTH

### ABSTRACT

Tooth avulsion is one of the most common dental injuries following trauma. Even though the golden period for reimplantation of an avulsed tooth ranges from 20-30 minutes after the trauma, it is not possible in all scenarios. In such cases, the option of delayed reimplantation can be considered. This paper highlights on the reimplantation of an avulsed tooth with 24 hours extraoral time with a follow up period of 6 months.

*Keywords: {Avulsion, Delayed reimplantation, Splinting}*

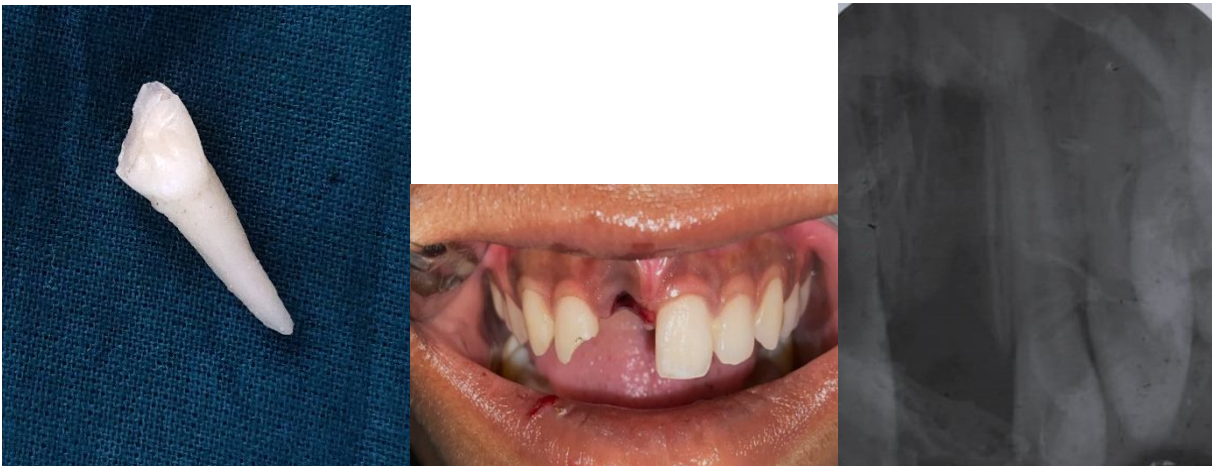
### 1. INTRODUCTION

Tooth avulsion refers to the complete displacement of a tooth from its socket caused by trauma, the incidence of which ranges from 0.5% to 3% in all dental injuries.[1-4] The etiology varies according to the type of dentition; As a result of fights, sport injuries, falls, automobile accidents, and child abuse. [5-6]

Following an avulsion, there will be breakdown of periodontal ligaments and impaired blood supply to the pulp tissue which in turn can result in necrosis of the pulp tissue and damage to the surrounding periodontium. [7] The primary goal for treating an avulsed tooth is to preserve and treat the supporting tissues along with the reimplantation of the tooth. The success of the procedure will be dependent on various factors including the general health of the patient, the extraoral time, storage media. [8-9]The possible consequences after delayed reimplantation includes ankylosis and resorption. The period of extra-oral time and the storage medium have the most critical effect ,as dry storage can affect the revascularization of the pulp tissue and survival of the periodontal ligament cells present on the root surface.[10-12]. The present case report discusses the management of an avulsed permanent maxillary right central incisor with 24 hours extraoral time.

### 2. CASE REPORT

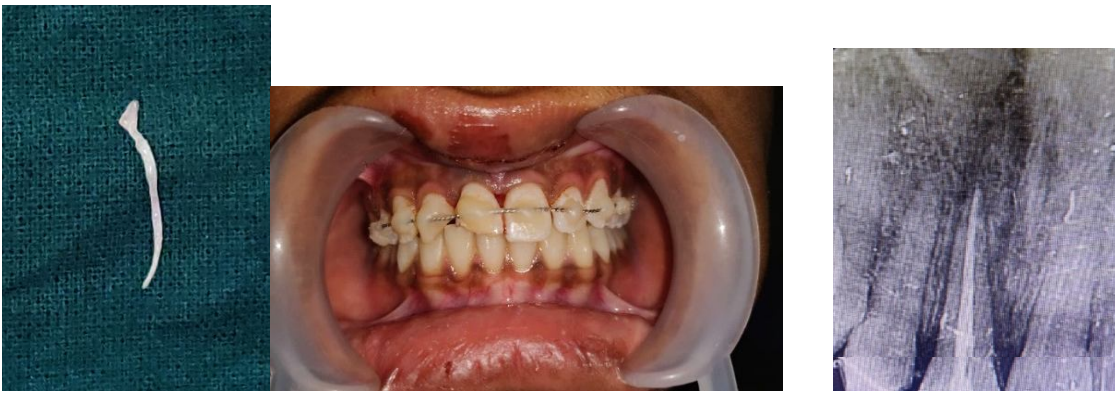A 15-year-old female child reported to the Department of Conservative Dentistry and Endodontics with an avulsed maxillary central incisor 1 day after road traffic accident. The tooth was initially stored in water for 1 hour after which it was stored under dry conditions in a container . The total extraoral time of the avulsed tooth when brought into the department was 24 hrs. On extra oral examination, laceration and slight swelling of the upper lip was noted. Intra oral examination revealed empty socket space suggestive of avulsed tooth irt 11 and Elli's class II fracture irt 12. (Fig 1)



(Fig 1) Morphology of teeth

Intra oral periapical radiograph was taken which revealed empty socket with no bony defects. (Fig 1). Pulp vitality test was carried out for 12,21 and 22 using an electric pulp tester which showed normal response. Extra oral root canal treatment followed by reimplantation and splinting of 11 was planned according to the IADT guidelines. Consent was taken from the patient's relatives and the possible risks and outcome of the treatment were explained.

The root surface of the tooth was cleaned and washed with saline. Access opening was done and pulp was extirpated, followed by cleaning and shaping using 3% sodium hypochlorite and saline upto #45 master file(Neo Endo) and obturated using 45,2% gutta percha(Dentsply Maillefer) and MTA Fillapex. The socket was curettaged and rinsed with saline. The tooth was reimplanted and splinting was done using round twist flex arch wire from canine to canine.



(FIG 2) ROOT SURFACE OF THE TOOTH

The occlusion was checked to make sure that there was no pre mature contacts. Radiograph was taken to verify the position of the tooth. Patient was advised to take only soft diet and the necessary oral hygiene instructions were given. Prophylactic antibiotic therapy with Amoxicillin clavulanate 625 mg for 5 days was prescribed to the patient. In addition, patient was also referred for an antitetanus booster. After 4 weeks, as the patient was asymptomatic, the splint was removed and composite build up was done for 11 and 12. (FIG 3). Recall visits were scheduled after 1 month, 3 months and 6 months. The 3 month radiograph showed mild resorption (Fig4) which was slightly increased in the 6 months radiograph.(Fig5)

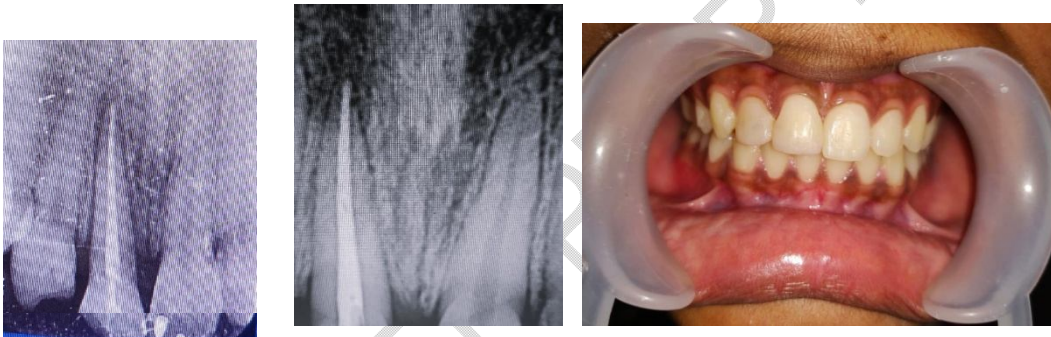


FIG 3-5. RADIOGRAPH SHOWING TOOTH MORPHOLOGY

### 3. DISCUSSION

Depending on a number of conditions, there are different standards for managing avulsed permanent teeth, but the best course of action is to maintain its prompt and fast replanting which is not possible always. The method of therapy for an avulsed tooth depends upon various elements like the root apex maturity and periodontal cell's state.[13] The viability of periodontal cells are majorly dependent on the extra oral time and the medium for storage. Clinical investigations have demonstrated that replanting teeth as soon as possible—within five minutes following an avulsion can offer the best results. While a 60-minute extra-oral dry period or more becomes unprofitable.[14] Therefore, patients should be informed to keep the avulsed tooth for an extended period of time outside of the mouth, in an appropriate medium like HBSS, saline, milk, or saliva until it is replanted back into the socket.[15-16]

In this case, patient was not aware that the tooth should be kept in storage media and was stored in dry condition except for the initial few hours after the injury. Hence, it was concluded that the periodontal ligament cells were

non-viable which can result in replacement resorption ultimately resulting in fusion of tooth root with adjacent alveolar bone.[17] In this case, there was also no evidence of any soft tissue remains on the root surface of the avulsed tooth and was completely clean when being brought for the treatment. Thus the root surface was rinsed only with saline to maintain the balance and to prevent over scraping of the cemental layer.

According to Heithersay GS, time is the key element in a successful replantation. If there is a delay of more than 2 hours, endodontic therapy is carried out before replantation.[18] IADT standards states that if the extra-alveolar time is greater than 60 minutes prior to reimplantation, root canal therapy can be done before reimplantation.[4] Hence in this case, root canal treatment was completed extra orally on the same day patient reported, after which the tooth was reimplanted and splinted for 4 weeks using a flexible splint. Occlusal forces and fundamental fibroblastic growth factor can be used to create healthy tooth-PDL bone formations ultimately, increasing production of growth factor.[19] However, in the circumstances at hand, there was no application of any root surface agents was undertaken prior to reimplantation as a result of the immediate accessibility of various agents is not always feasible in therapeutic settings.

Replacement resorption and ankylosis are the optimal processes followed when there are no PDL residues and root contamination is under control, claim Panzarini et al. Though these occurrences will eventually result in tooth loss, any diminution in the height of the alveolar ridge is seen as crucial for the planning of future prostheses.[20] Because of this, tooth replacement in the present situation is carried out even after a significant delay to prevent the loss of alveolar ridge height.

The present case is still ongoing and any appropriate treatment procedures will be carried out based on the prognosis of the treatment.

#### **4. CONCLUSION**

Teeth with delayed replantation may still be kept in a stable and useful position in the dental arch despite an extended extra-alveolar dry storage period. Moreover, the reimplanted tooth can be used to maintain the surrounding bone in patients where growth is not ceased, until the patient becomes a suitable candidate for implant.

The society should be made aware of tooth avulsion and the procedures to be followed after an avulsion injury, which can highly influence on the success rate of the treatment. As mentioned in the title of this paper, "Better late than never": More rapid the action, more rapid the results

#### **CONSENT**

"All authors declare that 'written informed consent was obtained from the patient (or other approved parties) for publication of this case report and accompanying images. A copy of the written consent is available for review by the Editorial office/Chief Editor/Editorial Board members of this journal."

#### **ETHICAL APPROVAL**

As per the international standard or university standard written ethical approval has been collected and preserved by the authors.

## REFERENCES

- 1) Delayed Replantation of Avulsed Teeth: Two Case Reports Selcuk Savas,1 Ebru Kucukyilmaz,1 Merve Akcay,1 and Serhat Koseoglu2
- 2) J. O. Andreasen and F. M. Andreasen, "Classification, etiology and epidemiology," in Textbook and Color Atlas of Traumatic Case Reports in Dentistry 5 Injuries to the Teeth, J. O. Andreasen and F. M. Andreasen, Eds., pp. 151–179, Mosby, Munksgard, Copenhagen, Denmark, 1994.
- 3) J. O. Andreasen and F. M. Andreasen, "Examination and diagnosis of dental injuries," in Textbook and Color Atlas of Traumatic Injuries to the Teeth, J. O. Andreasen and F. M. Andreasen, Eds., pp. 195–217, Mosby, Copenhagen, Denmark, 1994.
- 4) L. Andersson, J. O. Andreasen, P. Day et al., "International Association of Dental Traumatology guidelines for the management of traumatic dental injuries: 2. Avulsion of permanent teeth," Dental Traumatology, vol. 28, no. 2, pp. 88–96, 2012.
- 5) A. D. Kaba and S. C. Marechaux, "A fourteen-year follow-up study of traumatic injuries to the permanent dentition," ASDC Journal of Dentistry for Children, vol. 56, no. 6, pp. 417–425, 1989.
- 6) J. O. Andreasen, "Etiology and pathogenesis of traumatic dental injuries. A clinical study of 1,298 cases," Scandinavian Journal of Dental Research, vol. 78, no. 4, pp. 329–342, 1970.
- 7) Ram2004TherapeuticPF, Therapeutic protocols for avulsed permanent teeth: review and clinical update, Diana Ram and Nestor Cohenca, Pediatric dentistry, 2004, volume 26, 251-5
- 8) N. Cohenca, S. Karni, D. Eidlitz, E. Nuni, and J. Moshonov, "New treatment protocols for avulsed teeth," Refuat Hapeh Vehashinayim, vol. 21, pp. 48–53, 2004.
- 9) U. Glendor, A. Halling, L. Andersson, and E. Eilert-Petersson, "Incidence of traumatic tooth injuries in children and adolescents in the county of Vastmanland, Sweden," Swedish Dental Journal, vol. 20, no. 1-2, pp. 15–28, 1996. J. O. Andreasen, "Effect of extra-alveolar period and storage media upon periodontal and pulpal healing after replantation of mature permanent incisors in monkeys," International Journal of Oral Surgery, vol. 10, no. 1, pp. 43–53, 1981.
- 10) Ize-lyamu IN, Saheeb B. Reimplantation of avulsed dry permanent teeth after three days: a report of two cases. Niger J Clin Pract. 2013 Jan-Mar;16(1):119-22. doi: 10.4103/1119-3077.106784. PMID: 23377486.
- 11) Andreasen JO, Borum MK, Jacobsen HL, Andreasen FM. Replantation of 400 avulsed permanent incisors.4. Factors related to periodontal ligament healing. Endod Dent Traumatol 1995;11:76-89.
- 12) 14)Andreasen JO, Borum MK, Andreasen FM. Replantation of 400 avulsed permanent incisors.3. Factors related to root growth. Endod Dent Traumatol 1995;11:69-75.
- 13) Cohenca N, Karni S, Eidlitz D, Nuni E, Moshonov J. New treatment protocols for avulsed teeth. Refuat Hapeh Vehashinayim 2004;21(2):48–53.
- 14) Kaba AD, Marechaux SC. A fourteen-year follow-up study of traumatic injuries to the permanent dentition. J Dent Childr 1989;56(6):417–425.
- 15) 17)Barrettand EJ, Kenny DJ. Avulsed permanent teeth: a review of the literature and treatment guidelines. Endod Dent Traumatol 1997;13(4):153–163. 28.
- 16) Pohl Y, Filippi A, Kirschner H. Results after replantation of avulsed permanent teeth. II. Periodontal healing and the role of physiologic storage and antiresorptiveregenerative therapy. Dent Traumatol 2005;21(2):93–101
- 17) Hasanuddin S, Reddy JS. Sequelae of delayed replantation of maxillary permanent incisors after avulsion: A case series with 24-month follow-up and clinical review. J Indian Soc Pedod Prev Dent. 2018 Oct-Dec;36(4):410-416.
- 18) Heithersay GS. Replantation of avulsed teeth. A review. Aust Dent J 1975;20:63-72

- 19) Sonmez AB, Castelnuovo J. Applications of basic fibroblastic growth factor (FGF-2, bFGF) in dentistry. Dent Traumatol 2014;30:107-11
- 20) . Panzarini SR, Gulinelli JL, Poi WR, Sonoda CK, Pedrini D, Brandini DA. Treatment of root surface in delayed tooth replantation: A review of literature. Dent Traumatol 2008;24:277-82.

UNDER PEER REVIEW