

Giant Coronary Artery Ectasia Presenting with ST Elevation Myocardial Infarction

ABSTRACT

Background: During routine coronary angiography we often come across coronary artery ectasia (CAE). Patients with coronary ectasia can present with acute coronary syndrome due to a large thrombus burden requiring emergency intervention or anticoagulation.

Case: 56-year-old diabetic, a nonsmoker, presented with chest pain lasting for more than twelve hours. On examination, he was hemodynamically stable, and cardiac auscultation was unremarkable. ECG sinus rhythm and suggestive of anteroseptal myocardial infarction, repeat ECG after loading with DAPT and heparin revealed ST-segment resolution. An echocardiogram showed hypokinesia of the anteroseptal and apical anterior wall, an LV ejection fraction of 56%. Coronary angiogram revealed Non-obstructive giant ectatic coronaries with slow contrast clearance, patient had an episode of ventricular tachycardia during a coronary angiogram, DC cardioverted. The patient was initially on parenteral LMWH and DAPT. He was discharged with antiplatelet (Aspirin 75 mg once a day) and anticoagulants (Rivaroxaban 2.5 mg 12th hourly), beta-blocker. Cardiac CT revealed Mild coronary artery disease with a calcium score – 30, and no significant coronary artery stenosis. Diffusely ectatic coronary arteries.

Conclusion: We highlight this case due to a lack of consensus approach in the management of CAE and long-term follow-up due to the inadequacy of prospective studies.

Keywords: Ectatic coronaries; spontaneous recanalised STEMI; acute coronary syndromes; coronary artery ectasia.

1. INTRODUCTION

“Coronary artery ectasia (CAE) is an aneurysmic abnormality of the artery characterized by diffuse dilatation, with a luminal diameter 1.5x wider than that of adjacent normal segments. It differs to coronary artery aneurysms which is a focal dilatation of an artery. Coronary artery ectasia is found in 2.7–2.8% of angiograms and occurs from disease processes that impair vessel wall integrity” [1, 2, 3]. “Clinical symptoms could be caused by the presence of concomitant obstructive atherosclerotic disease or distal embolization due to local thrombosis in the lumen of a large aneurysmatic coronary segment. The abnormal coronary dilatation and flow disturbances, often associated with high thrombus burden in patients with MI, advocate more potent and prolonged antithrombotic therapies. However, in absence of robust large-scale data, the pharmacological treatment is not standardized yet and still relies on the choice of

the clinicians based on their own experience” [4,5].

2. CASE PRESENTATION

A 56 year old south Indian gentleman who is diabetic, non smoker, presented to our emergency room with chest pain lasting for more than twelve hours. On examination he was hemodynamically stable, cardiac auscultation was unremarkable. ECG sinus rhythm and suggestive of anteroseptal myocardial infarction (Fig. 1A) repeat ECG after loading with DAPT and heparin revealed ST segment resolution (Fig. 1B). Echocardiogram showed hypokinesia of anteroseptum and apical anterior wall, LV ejection fraction of 56%. Coronary angiogram revealed Non obstructive giant ectatic coronaries with slow contrast clearance (Figs. 2A, 2B), patient had an episode of ventricular tachycardia during coronary angiogram, DC cardiovetred. Patient was initially on parenteral LMWH and DAPT. He was discharged with antiplatelet (Aspirin 75 mg once a day) and anticoagulants (Rivaroxaban 2.5mg 12th hourly), beta-blocker.

Cardiac CT done revealed Mild coronary artery disease with calcium score – 30, no significant

coronary artery stenosis. Diffusely ectatic coronary arteries (Fig. 3).

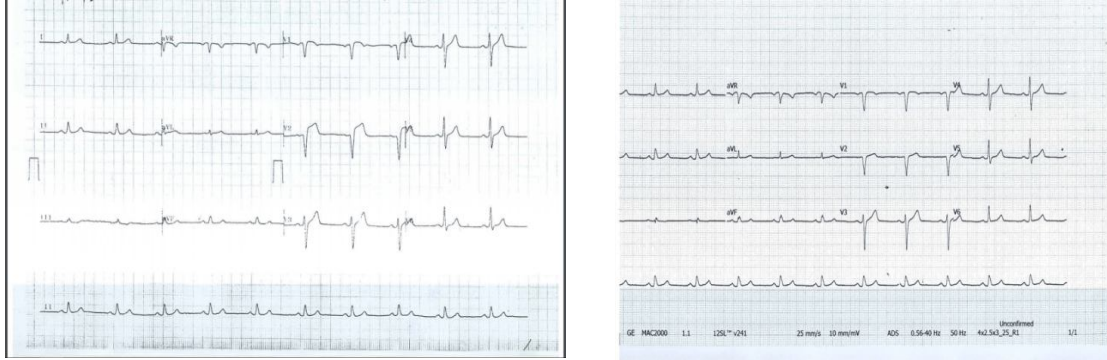

Fig. 1 A) ECG in emergency room 1 B) ECG after few minutes

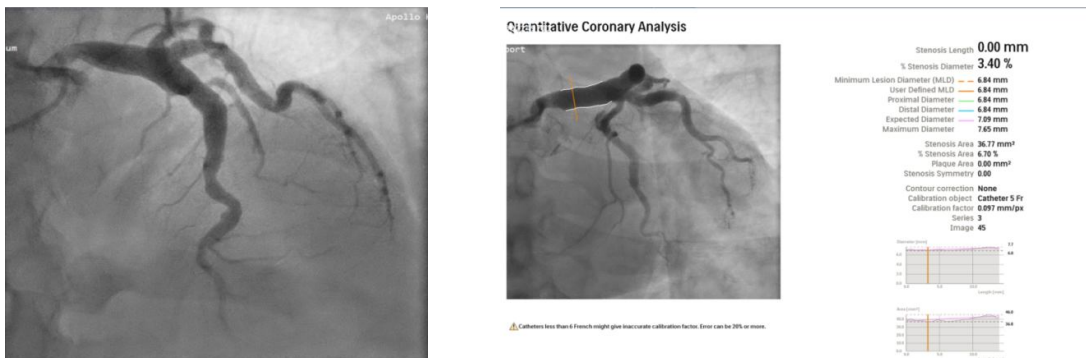


Fig. 2A. Left coronary angiogram

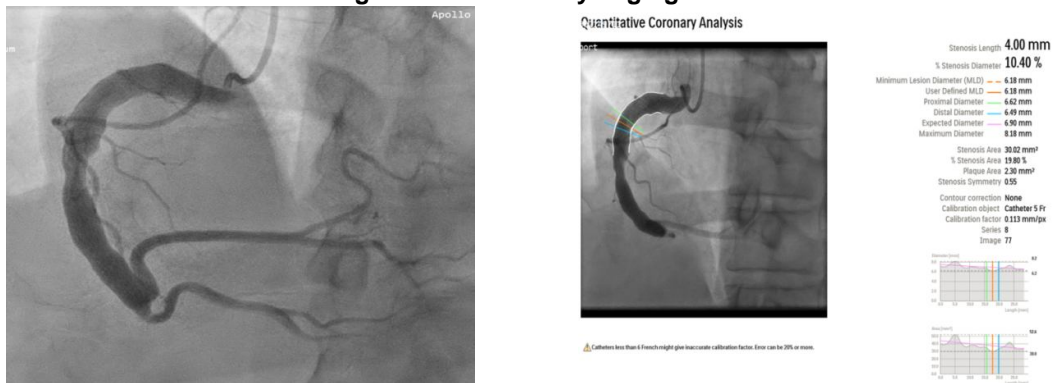


Fig. 2B. Right coronary angiogram

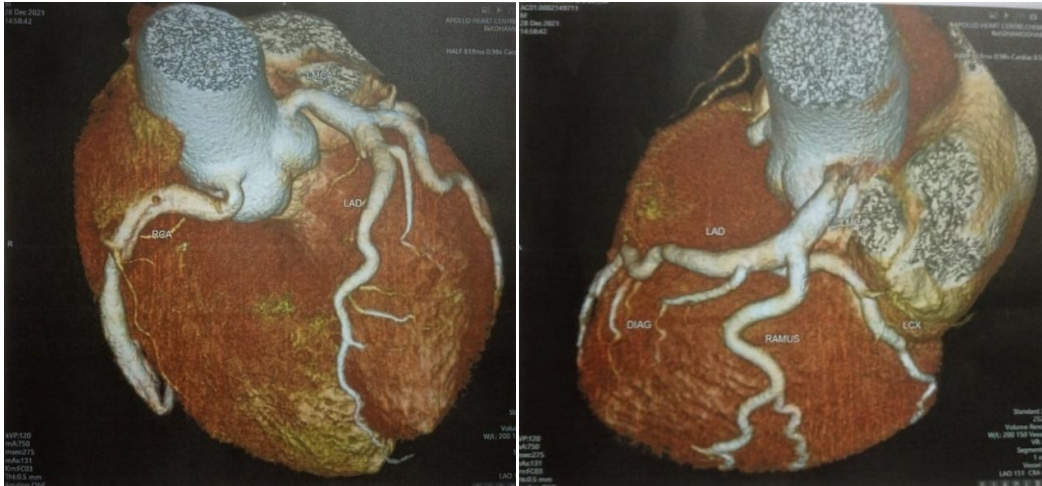


Fig. 3 - CT coronary angiogram

Table 1. Timeline of the study

Day 1 11:33 hours (ECG at peripheral health centre) History of chest pain	Sinus rhythm ST elevation V1, V2, V3 with ST depression III, aVF Medications administered as per standard ACS protocol
15:52 hours (Emergency room) Persistent chest pain with decrease in intensity	Sinus rhythm Q with ST elevation V1, V2 settling, ST depression in III, aVF
16:20 hours (Cath lab angiogram)	Non obstructive ectatic coronaries with slow contrast clearance Ventricular tachycardia – DC cardioverted with 100J
17:00 hours (CCU) No chest pain Day 2 & Day 3	Sinus rhythm Q S in V1, V2 with ST elevation settled Uneventful Discharged with rivaroxaban 2.5 mg twice daily and aspirin 75mg once a day with high intensity statin and beta blocker.
CT CAG done	Mild coronary artery disease. Calcium score - 30 No significant coronary artery stenosis. Diffusely ectatic coronary arteries

3. DISCUSSION

During angiographic procedures we come across Coronary Artery Ectasia (CAE) in 3 to 8% of patient's, few may present as acute coronary syndromes (ACS) or recurrent ACS. Only few case series and reports were published regarding the treatment and prevention of ACS in CAE [1]. Though limited data was available on use of SAPT, DAPT, anticoagulation, combined anticoagulation with SAPT/DAPT; there is no consensus in the long term management of non obstructive or thrombotic CAE and prevention of recurrence [2-4]. Due to lack of robust data on therapeutic strategies specific to isolated non obstructive or thrombotic CAE, the management needs to be tailored to individual patient with consideration of clinical presentation, angiographic findings and comorbidities [5].

Aspirin has been recommended in CAE patients with concomitant obstructive coronary lesions and myocardial infarction [6]. "The role and specific benefits of DAPT in long-term secondary prevention are unknown" [6]. "Initial studies have recommended the use of long-term oral anticoagulation on the premise of an increased risk of thrombosis in ectatic segments. Data from a retrospective study showed patients who were treated with vitamin K antagonists with the percentage of time in therapeutic range (%TTR) >_60% had a lower occurrence of major adverse cardiac events than those with low %TTR" [7]. "In ATLAS-ACS 2 TIMI 51 Rivaroxaban 2.5 mg b.i.d. was associated with a significant reduction in the composite of cardiovascular death, myocardial infarction, or stroke with no increase in fatal bleeding" [8].

4. CONCLUSION

We highlight this case due to lack of consensus approach in management of CAE and long term follow up due to inadequacy of prospective studies.

CONSENT

As per international standard or university standard, patients' written consent has been collected and preserved by the author(s).

ETHICAL APPROVAL

As per international standard or university standard written ethical approval has been collected and preserved by the author(s).

COMPETING INTERESTS

Authors have declared that no competing interests exist.

REFERENCES

Please check all references

1. Is anticoagulant necessary in patients with coronary artery ectasia presenting with acute coronary syndrome? A systematic review of case reports. *International Journal of Angiology*. 2019;28(4).
2. Mavrogeni S. Coronary artery ectasia: Diagnosis and treatment. *Hellenic J Cardiol* 2010;51:158–163.
3. Malviya A, Jha PK, Mishra A. Isolated coronary artery ectasia: Clinical, angiographic, and follow up characteristics. *Indian Heart J*. 2017;69:619–623.
4. Boles U, et al. Coronary artery ectasia; clinical updates and management options in acute presentation. *Med Res Arch*. 2017;5. ISSN 2375-1924.
5. Kawsara A, Nuñez Gil IJ, Alqahtani F, Moreland J, Rihal CS, Alkhouli M. Management of coronary artery aneurysms. *JACC Cardiovasc Interv*. 2018;11:1211–1223.
6. Devabhaktuni S, Mercedes A, Diep J, Ahsan C. Coronary artery ectasia—A review of current literature. *Curr Cardiol Rev*. 2016; 12:318–323.
7. John Lee, Satish Ramkumar, Nancy Khav, Benjamin K. Dundon coronary artery ectasia presenting with ST-elevation myocardial infarction in a young indigenous man: A case report-European Heart Journal - Case Reports. 2020;4:1–5. doi:10.1093/ehjcr/ytaa253
8. Korjian S, Braunwald E, Daaboul Y, Verheugt F, Bode C, Tendera M, Jain P, Plotnikov A, Burton P, Gibson CM. Safety and efficacy of rivaroxaban for the secondary prevention following acute coronary syndromes among biomarker-positive patients: Insights from the ATLAS ACS 2-TIMI 51 trial. *European Heart Journal: Acute Cardiovascular Care*. 2019; 8(2):186-93.

© 2022 Dhamodaran and Abhishek; This is an Open Access article distributed under the terms of the Creative Commons Attribution License (<http://creativecommons.org/licenses/by/4.0>), which permits unrestricted use, distribution, and reproduction in any medium, provided the original work is properly cited.