

The management of degenerative Complete Heart block in the time of Coronavirus.

Abstract

The use of chloroquine for SARS COV2 has been adopted by many countries around the world, including Morocco. The Chloroquine is known for its anti-arrhythmic and bradycardic effects and for its formal contraindication in cardiac conduction disorders, long QT and high-degree heart block, which makes the management of a complete heart block in a positive Covid a great dilemma for the rhythmologist. In this article, we describe the management of the association COVID 19-symptomatic high-degree heart block.

Keywords: chloroquine, COVID 19, complete heart block

Introduction

The activity in the Rhythmology department wasn't much reduced during the covid period. The changes linked to this pandemic do not only concern the organization of the activity but also the indications for treatment for certain pathologies. In Morocco, since April 2020, the Ministry of Health has adopted chloroquine as the standard treatment for patients with covid 19[1], a class 1 anti-arrhythmic drug known since the 1970s for its effectiveness on viruses, paludism and on system diseases such as lupus... yet the doses are not the same, and for the covid we use high doses with an initiation from the outset at a maximum dose.

The Chloroquine is known for its anti-arrhythmic and bradycardic effects and for its formal contraindication in cardiac conduction disorders, long QT and high-degree heart block, which makes the management of a complete heart block in a positive Covid a great dilemma for the rhythmologist. In this article we describe the management of two covid positive patients arriving in the emergency room for symptomatic complete heart block.

Case report 1:

Patient information: A patient 62 years old, type 2 diabetic for four years

Clinical findings: the patient arriving in the emergency room for five episodes of fainting for three days, the patient reports the notion of dry cough with fever for 5 days rebellious to symptomatic treatment. Clinical examination found a conscious patient with Heart Rate at 32 beats/minute, Blood Pressure (BP) 180/100 mm Hg, Saturation in oxygen at 90%, no cardiac murmur, normal vascular and neurological examination.

Time line and diagnostic assessment: ECG recorded a complete heart block with ventricular escape rate at 30 heart/beats (Figure 1). The chest radiograph showed diffuse interstitial syndrome (Figure 2). The emergency chest CT scan showed a CORADS 5 (Figure 3). The cardiac ultrasound returned normal; the PCR of SARS COV 2 came back positive.

Therapeutic intervention: The management consisted of monitoring the patient and his conditioning, the administration of isoprenaline by slow intravenous route, the placement of an emergency stimulation probe, the next day the patient received a double chamber pacemaker (PM) by a team of rhythmology well trained for these situations in a block prepared by respecting the precautionary measures against the infection covid.

At 24 hours post-stimulation by the PM (Figure 4), the patient began his anti-covid treatment based on heparin at a curative dose, chloroquine 200 mg * 3 / d, azithromycin 500 d1 then 250 mg / d with paracetamol, vitamin C and zinc,

Follow-up and outcomes: the electrical monitoring of the patient showed a normal QT remained between 420 ms and 440 ms during the ten days of hospitalization (Figure 5).

Case report 2:

Patient information: a patient 57 years old, hypertensive on a calcium channel blocker for 4 years complicated by hypertensive nephropathy at the hemodialysis stage, Covid positive on day 3 of the chloroquine-based treatment at home

Clinical findings: The patient was admitted for traumatic syncope, the clinical examination found a conscious patient, bruise on the face with facial wound, BP at 150/80 and HR at 40 cpm, neurological examination was normal, brain CT returned to normal, facial CT showed fracture of the bones of the nose, ECG showed complete atrio-ventricular block (AVB) with a junctional escape rate of 40 heart/beats (Figure 6), so we stopped the chloroquine.

Time line and diagnostic assessment: Laboratory workup showed terminal kidney failure, normal serum potassium and negative troponin. The cardiac echography showed good kinetics with a normal ejection fraction.

Therapeutic intervention: The patient received double chamber PM on the same day, and after the implantation, the patient resumed her anti-covid treatment with chloroquine.

Chest X-ray and chest CT scanner of the second patient after pace maker implantation showed CORADS 5.

Follow-up and outcomes: the PCR control at day 10 came back negative and the patient was discharged with good outcome

DISCUSSION :

“Coronavirus disease 2019 (COVID-19) is now a pandemic as recognized by the World Health Organization (WHO) on March 11, 2020. The disease is caused by Severe Acute Respiratory Syndrome Coronavirus 2 (SARS-CoV-2/2019-nCoV), a positive-sense, single-stranded RNA virus. The most common presenting symptoms include cough, fever, fatigue, shortness of breath, sore throat, and headache. At the time of release of this statement, as per the available global statistics, more than 66M million had infection and around 1.52million had died” [2]. “The corresponding figures in Morocco are 372,620 and 6,136 respectively” [3].

“The possible efficacy of chloroquine/hydroxychloroquine in the treatment of various diseases, including viral infections such as COVID-19 [4] has received increasing interest. The drug, hydroxychloroquine (HCQ), is a 4-amino-quinoline that is widely used to treat certain autoimmune disorders, and related inflammatory and dermatological conditions”. “It is a hydroxylated version of chloroquine e an antimalarial that has been in use for decades, with a similar mechanism of action. HCQ is considered to be safer than chloroquine based on clinical studies” [5]. “This drug has now found place in management of COVID-19 infection. It has been observed to inhibit ACE2 receptor-mediated entry of the SARSCoV2 virus through various actions such as raising of intravascular pH, inhibiting lysosomal activity, affecting antigen processing, etc. In addition, it has anti-inflammatory and immunomodulator actions which could be relevant in the crisis generated by cytokines storm during COVID-19 infection” [6].

Like many countries [7], Morocco adopted the chloroquine as the first-line treatment for covid 19 infection, the protocol consists of the administration of chloroquine at a dose of 500mg * 2 / day or hydroxychloroquine sulfate at a dose of 200mg * 3 / day in combination with azithromycin and symptomatic treatment [1].

The side effects of chloroquine/hydroxychloroquine on the heart are mainly of two types: those involving changes in electrical conduction, heart rate and rhythm [8,9]; and those involving structural changes associated with cardiomyopathy [10] or myocardial remodeling.

The mechanisms underlying the conduction and rhythm changes mainly involve inhibitory actions on various ion channels. Block of Na⁺ channels (local anesthetic action) is likely responsible for observed bundle branch and intraventricular block [8,9,10]. Block of K⁺ channels will tend to lengthen the action potential duration, whereas inhibition of Na⁺ and Ca²⁺ channels will have opposite effects. That the drugs given alone at low or moderate concentrations and for a short duration produce only limited prolongation of the QT interval is likely due to this balanced contribution of opposite effects [9-10]. Heart rate changes also result from a balance between a bradycardic action of If and I_{Ca-L} inhibition and a tachycardic effect of I_{K1} and I_{K-ACh} inhibition [8,10], in addition to suppression of the vagal tone on the heart [8,9]. The resultant action of chloroquine can be proarrhythmic or antiarrhythmic depending on the underlying condition [8,9,11]

Chloroquine is a Class I anti-arrhythmic formally contraindicated in high-grade AVB, it can even sometimes be the cause of complete AVB in patients with sinus rhythm [12].

“Few cases have reported an association between AV block and COVID-19 infection” [13]. Our patient was found to have no reversible cause of his AV block, such as thyroid dysfunction, electrolyte disturbances, acute myocardial infarction, myocarditis or use of medications. Our patient did not have extensive systemic or myocardial involvement; however, accidentally they present with a degenerative heart block consistent with the infection. the management consisted quite simply of the abstention of chloroquine, and its readministration just after the implantation of the pacemaker.

Conclusion

The use of chloroquine for SARS-COV2 has been adopted by many countries around the world, including Morocco and some African countries. The combination of Covid and high-grade atrioventricular block requiring the implantation of a pacemaker is not a rare situation. in this article, the management of this type of patient has been well described.

Ethical Approval:

As per international standard or university standard written ethical approval has been collected and preserved by the author(s).

Consent

As per international standard or university standard, patients' written consent has been collected and preserved by the author(s).

References:

- [1] circulaire du ministere de santé marocain du 23 mars (sante.gov.ma)
- [2] <https://www.who.int/emergencies/diseases/novel-coronavirus-2019/situation-reports>.
- [3] Statistiques relatives au coronavirus - Bing
- [4] Devaux CA, Rolain JM, Colson P, Raoult D. New insights on the antiviral effects of chloroquine against coronavirus: what to expect for COVID-19? *Int J Antimicrob Agents* 2020;55:105938.
- [5] Perez BC, Fernandes I, Mateus N, Teixeira C, Gomes P. Recycling antimalarial leads for cancer: antiproliferative properties of N-cinnamoyl chloroquine analogues. *Bioorg Med Chem Lett* 2013;23:6769–72.
- [6] Plantone D, Koudriavtseva T. Current and future use of chloroquine and hydroxychloroquine in infectious, immune, neoplastic, and neurological diseases: a mini-review. *Clin Drug Investig* 2018;38:653–71.
- [7] Coronavirus : Pays où l'hydroxychloroquine est recommandée – IHU (mediterranean-infection.com)
- [8] Cardiac Complications Attributed to Chloroquine and Hydroxychloroquine: A Systematic Review of the Literature Clotilde Chatre, François Roubille, Hélène Vernhet, Christian Jorgensen ; Yves-Marie Pers

[9] Heart conduction disorders related to antimalarials toxicity: an analysis of electrocardiograms in 85 patients treated with hydroxychloroquine for connective tissue diseases N. Costedoat-Chalumeau, J.-S. Hulot, Z. Amoura, G. Leroux, P. Lechat, C. Funck-Brentano, J.-C. Piette *Rheumatology*, Volume 46, Issue 5, May 2007, Pages 808–810,

[10] Chloroquine cardiomyopathy – a review of the literature Ernst Tönnesmann, Reinhard Kandolf & Thorsten Lewalter Pages 434-442 | Received 02 Jan 2013, Accepted 22 Feb 2013, Published online: 01 May 2013 <https://doi.org/10.3109/08923973.2013.780078>

[11] Cardiac effects and toxicity of chloroquine: a short update Kanigula Mubagwaa, Department of Cardiovascular Sciences, KU Leuven, Leuven, Belgium & Department of Basic Sciences, Faculty of Medicine, Université Catholique de Bukavu, Bukavu, DR Congo

[12] Complete heart block in chronic chloroquine poisoning ; G.O.A. Ladipo, E.E.Essien, J.J.Andy.

[13] Atypical presentation of COVID-19 as subclinical myocarditis with persistent high-degree atrioventricular block treated with pacemaker implant. Omar Al-assaf, Madiha Mirza, Anas Musa. From the-Internal Medicine Department, Rashid Hospital, Dubai Health Authority, Dubai, United Arab Emirates, and-Cardiology Department, Rashid Hospital, Dubai Health Authority, Dubai, United Arab Emirates.

Figures

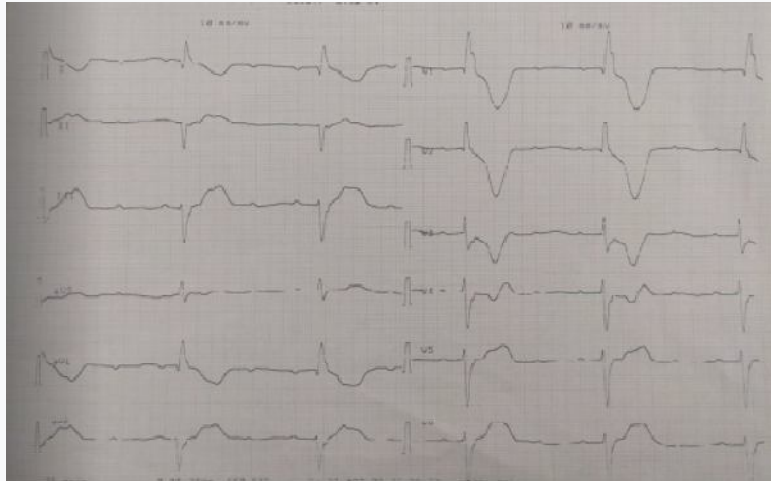


Figure 1: ECG of the first patient on admission

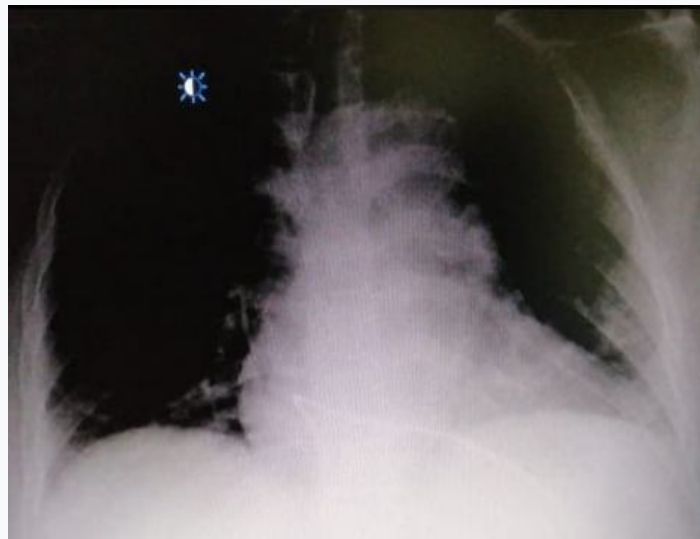

Figure 2: chest X-ray of the first patient showing the stimulation probe

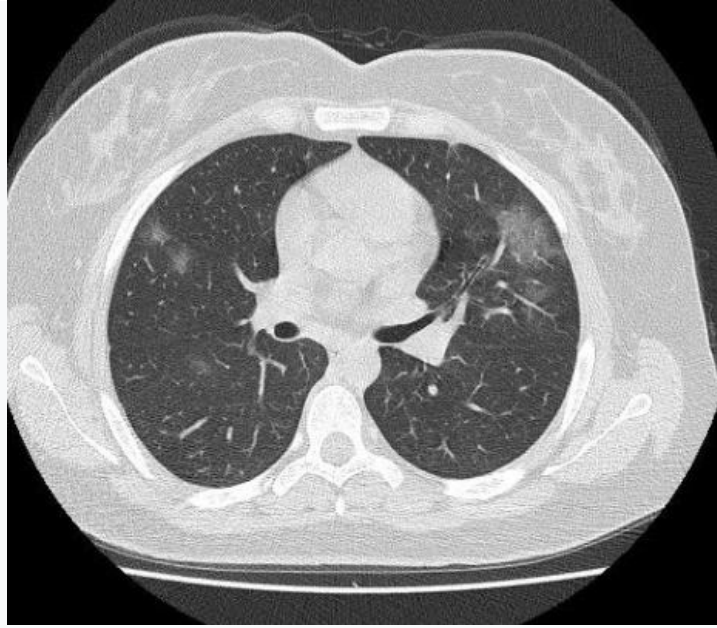


Figure 3: chest CT scanner of the first patient

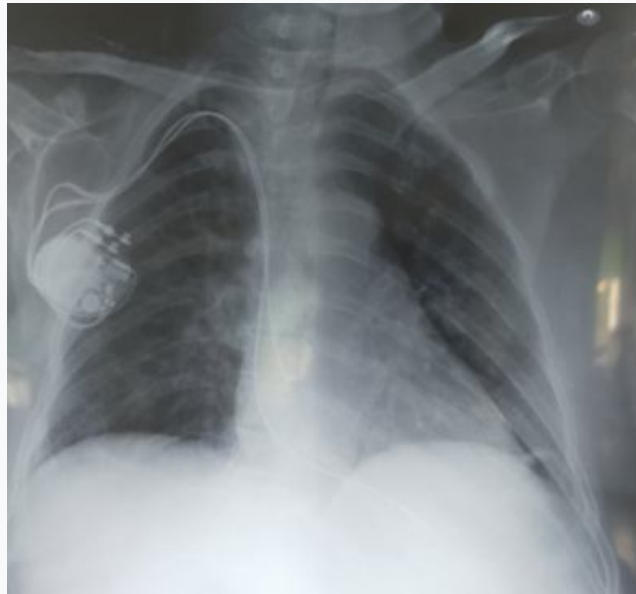

Figure 4: chest X-ray of the first patient after pace maker implantation

on admission

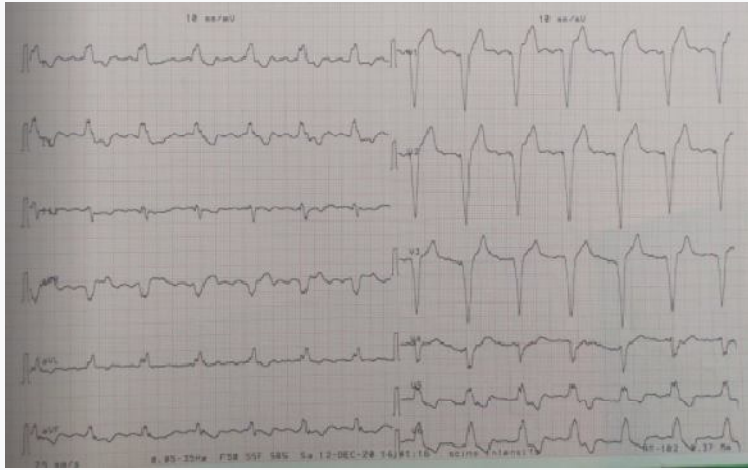


Figure 5: ECG of the first patient after pace maker implantation

UNDER PEEK

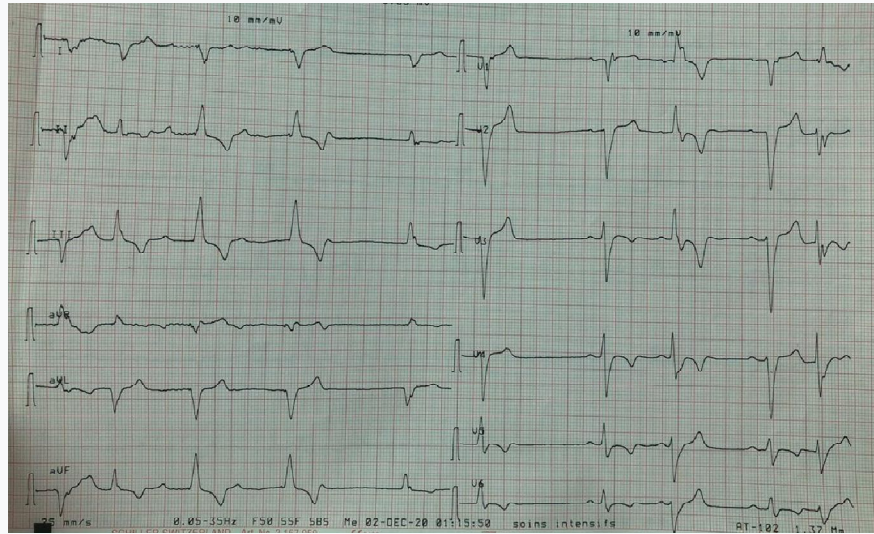


Figure 6: ECG of the second patient on admission

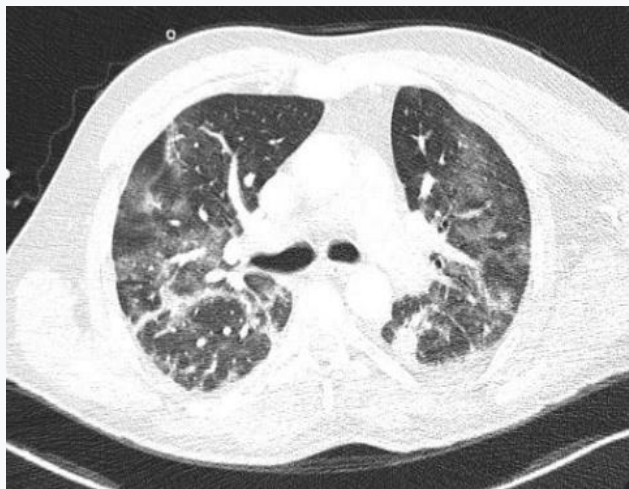
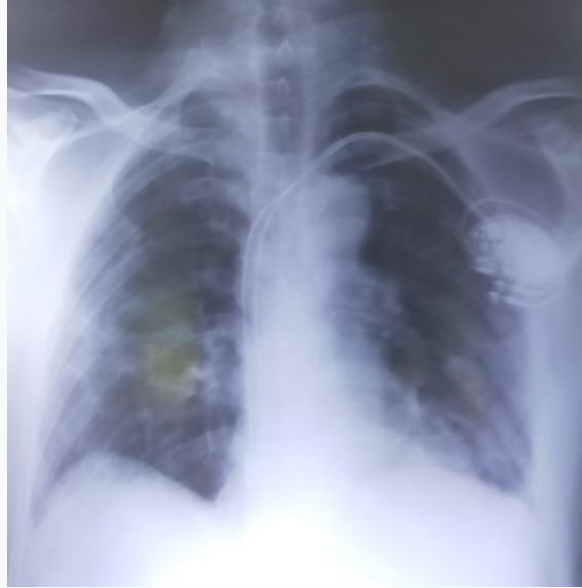

Figure 7: chest X-ray and **chest CT scanner** of the second patient after pace maker implantation