

Case study

Case report: Retroperitoneal Rhabdomyosarcoma in a 48 year old male patient

Abstract

We present to you the case report of a 48 year old male who came to us with swelling in left lower abdomen, left scrotal swelling and pain in left inguinal area. It was a rare, non-resectable, pleomorphic Rhabdomyosarcoma. A multidisciplinary approach was taken and Cytoreduction (debulking surgery) was done followed by chemotherapy and radiation therapy.

Introduction

Rhabdomyosarcoma (RMS) is a malignant tumor of mesenchymal origin that currently has a greater than 70% overall 5-year survival. [1] Rhabdomyosarcoma can be classified according to the prognosis. Botryoid and spindle cell tumors have good prognosis, embryonal tumors have intermediate prognosis, alveolar and undifferentiated sarcomas have poor prognosis and those with rhabdoid features, their prognosis is unevaluable. Embryonal RMS is composed of blastemal mesenchymal cells that tend to differentiate into cross-striated muscle cells. Highly characteristic of embryonal RMS are ribbon or strap shaped cells with elongated nuclei. Some tumors contain cells with bipolar cytoplasmic extensions, "tadpole" cells, with eccentrically located nuclei and only one cytoplasmic process and the so called spider web cells, which contain large periodic acid-Schiff positive vacuoles between threadlike strands of cytoplasm. Alveolar Rhabdomyosarcoma are composed of anastomosing fibrovascular connective tissue septa forming an alveolar pattern lined by neoplastic cells. Undifferentiated Sarcomas are

generally diffuse, with no specific features. The pattern of growth may be fascicular or hemangiopericytoma-like. [4]

RMS is treated by a combination of surgery, chemotherapy, and radiation. If tumor is surgically inoperable then initially radiotherapy and chemotherapy given to shrink the tumor followed by wide surgical excision of the tumor performed. [2] Multimodality treatment is determined by risk stratification according to pretreatment stage, postoperative group, histology, and site of the primary tumor. Pretreatment staging is dependent on primary tumor site, size, regional lymph node status, and presence of metastases. Unique to Rhabdomyosarcoma is the concept of postoperative clinical grouping that assesses the completeness of disease resection and takes into account lymph node evaluation. Overall, the prognosis for Rhabdomyosarcoma is dependent on primary tumor site, patient age, completeness of resection, extent of disease, including the presence and number of metastatic sites and histology and biology of the tumor cells. [1]

Case presentation

A 48 years old male, uneducated, rickshaw driver resident of Chung, Punjab, Pakistan, married with four children, presented in outpatient department (OPD) with the complaints of swelling in left lower abdomen for two months left scrotal swelling for two weeks and pain in left inguinal area for three days.

Patient was alright two months back, when he first noticed a swelling in left lower abdomen which has been increasing in size. He had pain in the swelling that was dull and localized. There were no associated gastrointestinal symptoms in the patient's history. There was also a swelling in the left scrotal region which was initially painless and subsequently started aching. This swelling was non-progressive, non-reducible, with no changes noted in the overlying skin. The pain was sudden in onset, stabbing in character and radiating to the lower back and the periumbilical region. It was aggravated by bending and lifting weights and on coughing, and was relieved by analgesics.

He complained of post-prandial bloating and constipation which was of recent onset. Patient was recently diagnosed with renal lithiasis (incidental). He had no history of weight loss, fever, night sweats, nausea or vomiting. No prior history of any medical disorder or admission to a

hospital. His surgical history was insignificant. He had no known drug or food allergy and had no family history of any malignancy in his family.

On general physical examination, patient was sitting comfortably on the bed, well oriented in time, place and person and was co-operative. His vitals were pulse rate 84 beats per minute, respiratory rate 16 per minute, blood pressure 110/70 mmHg, temperature 99° F and weight 130kg. First and second heart sounds were normal with no added sounds, there was normal vesicular breathing with no added sounds and his central nervous system was intact.

On inspection, abdomen was protuberant and asymmetrical towards the left of the midline. Carnett sign was positive which is that the mass becomes less prominent when the patient is asked to raise his head on lying flat. On superficial palpation, there was a bulge noticed in the left lower abdomen. On deep palpation, there was a spherical mass noted in the left lower abdomen. Its surface was smooth with well-defined margins. The Upper limit was palpable just above the level of the umbilicus and extended into left iliac fossa, left lumbar region & the hypogastrium and the lower limit was not palpable. The mass was mildly tender on deep palpation and does not move with respiration. It was not attached to overlying skin & abdominal wall but appeared to be fixed with deeper structures. Mass was bimanually palpable and no other organomegaly was noted. Mass was dull on percussion.

On examination of inguinoscrotal region, a Grade 2 varicocele was present in the left hemiscrotum. There were no palpable hernias or regional lymphadenopathy.

Patient was admitted. His abdominopelvic ultrasound showed abdominal mass measuring 15.4 x 14cm extending into left iliac fossae, left lumbar region & hypogastrium. There was hepatomegaly with steatosis and left nephrolithiasis with moderate hydronephrosis. Post contrast computed tomography (CT) scan showed soft tissue density neoplastic mass in left lower abdomen likely of nodal origin-biopsy correlation was suggested to rule out lymphoma. There were small peri splenic ascites.

Initially ultrasound guided needle biopsy was planned but later it was abandoned as it was not safe, so diagnostic laparoscopy was conducted along with biopsy. The histopathology report of the biopsy specimen revealed Rhabdomyosarcoma (malignant neoplasm) composed of atypical

and moderately pleomorphic spindled cells with elongated nuclei, brisk mitotic activity was also seen.

Diagnosis of retroperitoneal Rhabdomyosarcoma was made. Then an opinion of oncologist was taken. It was a non-resectable tumor and he suggested debulking surgery (cytoreduction) which was then done. Post-operative recovery was uneventful. Patient was discharged after 7 days and then referred to oncologist for chemotherapy and radiotherapy. Last follow up was done after one month and patient was doing well.

Discussion

Rhabdomyosarcoma is a malignant tumor of mesenchymal tissue. RMS can occur at any site, although it has a predilection for the head and neck, genitourinary organs, retroperitoneum, and extremities. [4] Rhabdomyosarcoma can arise in retroperitoneum. Twenty-two cases of retroperitoneal Rhabdomyosarcoma have been reported by Pack and Tabah (1954). It occurs in both children and adults. However, retroperitoneal Rhabdomyosarcoma is an extremely rare tumor in general, which is occasionally reported in a large cohort of cases with retroperitoneal tumors. Of 121 cases of Rhabdomyosarcoma reviewed by Stout (1946), only one case of primary retroperitoneal Rhabdomyosarcoma was found. [3] The pathogenesis of RMS remains unclear; however, many hypotheses exist. It is largely thought that RMS arises because of regulatory disruption of skeletal muscle progenitor cell growth and differentiation. Open biopsy of a mass suspected to be malignant should be performed to confirm the diagnosis. Care should be taken to obtain adequate specimens for pathologic, biological, and treatment protocol studies. For small lesions in areas that will be treated with only chemotherapy and radiation or for metastatic disease, open surgical biopsy is the best choice. Core biopsy may not be ideal because of sampling error and insufficient tissue samples. [1] Rhabdomyosarcoma most often present as an expanding mass, resulting in pain and symptoms related to the compression of nearby structures. [4] For treatment, Chemotherapeutic agents which are commonly used are vincristine,

cyclophosphamide, dactinomycin, adriamycin, ifosfamide, VP-16. With combined modality of treatment - chemotherapy, radiation therapy, and surgery - the overall survival rate for all most RMS is 71 %. [2]

Conclusion

We have presented a retroperitoneal Rhabdomyosarcoma. Diagnostic laparotomy was performed and biopsy was taken .Histopathology confirmed the diagnosis. Tumor was unresectable so debulking surgery was done, followed by chemotherapy and radiotherapy.

Ethical approval

Not required

UNDER PEER REVIEW

References

1. Dasgupta, R., & Rodeberg, D. A. (2012). Update on Rhabdomyosarcoma. *Seminars in Pediatric Surgery*, 21(1), 68-78. <https://doi.org/10.1053/j.sempedsurg.2011.10.007>
2. MB Mc Carville, SL Spunt, AS Pappo. Rhabdomyosarcoma in Pediatric Patients. *American Journal of Roentgenology*. 2001; 176:1563–69.
3. Miao, C., Luo, CH. (2018). Retroperitoneal Rhabdomyosarcoma. In: Luo, CH. (eds) *Retroperitoneal Tumors*. Springer, Dordrecht. https://doi.org/10.1007/978-94-024-1167-6_17
4. Newton, W.A., Jr., Gehan, E.A., Webber, B.L., Marsden, H.B., van Unnik, A.J.M., Hamoudi, A.B., Tsokos, M.C., Shimada, H., Harms, D., Schmidt, D., Ninfo, V., Cavazzana, A.O., Gonzalez-Crussi, F., Parham, D.M., Reiman, H.M., Asmar, L., Beltangady, M.S., Sachs, N.E., Triche, T.J. and Maurer, H.M. (1995), Classification of rhabdomyosarcomas and related sarcomas. Pathologic aspects and proposal for a new classification-an intergroup rhabdomyosarcoma study. *Cancer*, 76: 1073-1085. [https://doi.org/10.1002/1097-0142\(19950915\)76:6<1073::AID](https://doi.org/10.1002/1097-0142(19950915)76:6<1073::AID)

Supplementary file for retroperitoneal rhabdomyosarcoma

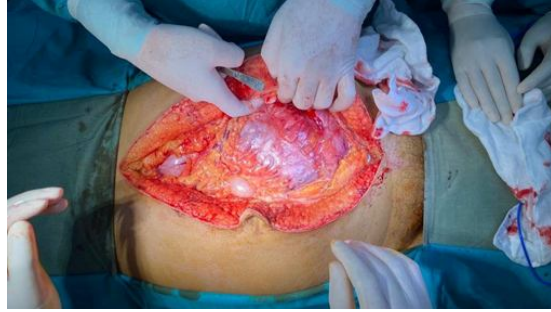

Figure 1: Diagnostic laparotomy

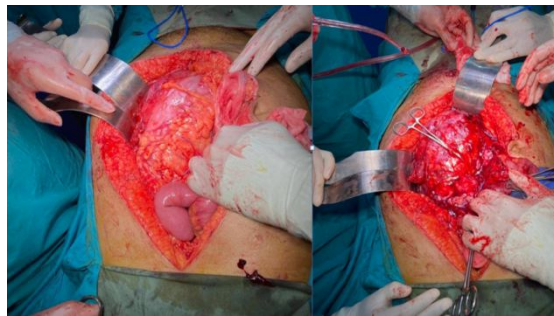


Figure 2: Debulking Surgery (cytoreduction)

UNDER PEER REVIEW

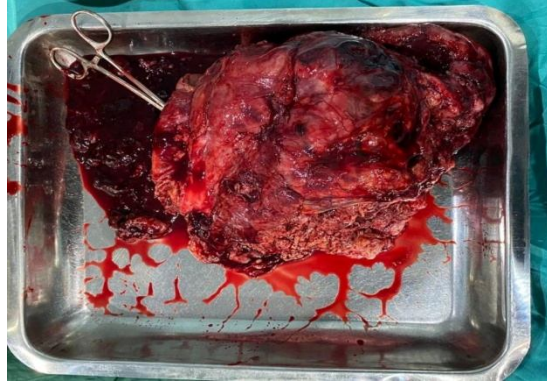


Figure 3: Part of tumor resected to debulk

UNDER PEER REVIEW