

# Goblet Cell Adenocarcinoma associated with appendiceal diverticulum presenting as acute appendicitis

---

## ABSTRACT

Appendiceal diverticuli are strongly associated with appendiceal malignancy, and are usually only identified incidentally on histopathology or uncommonly present as acute appendiceal diverticulitis. Due to their rarity and mixed histological features, there has been significant inconsistency in the nomenclature and grading of goblet cell adenocarcinomas. This case report of a 30 year old female with incidental findings of both appendiceal diverticulum and goblet cell adenocarcinoma aims to reconcile established evidence as well as provide insight into the natural history of this uncommon appendiceal malignancy.

*Keywords: Goblet cell adenocarcinoma, Appendiceal cancer, goblet cell carcinoid*

## 1. INTRODUCTION

Appendiceal diverticuli are strongly associated with appendiceal malignancy, and are usually only identified incidentally on histopathology or uncommonly present as acute appendiceal diverticulitis. Due to their rarity and mixed histological features, there has been significant inconsistency in the nomenclature and grading of goblet cell adenocarcinomas. This case report of a 30 year old female with incidental findings of both appendiceal diverticulum and goblet cell adenocarcinoma aims to reconcile established evidence as well as provide insight into the natural history of this uncommon appendiceal malignancy.

## 2. PRESENTATION OF CASE

A woman in her 30's presented to the emergency department with a 3 day history of periumbilical pain that had since migrated to the suprapubic region, with associated symptoms of nausea, vomiting and anorexia, and a single episode of loose stools. She had a previous medical history of GORD but otherwise no other significant medical or surgical history. Family history was significant for breast cancer in her maternal grandmother. On examination, she was tachycardic to 132, febrile to 38.7c and hypotensive to 99/61, and had signs of localised peritonitis with point tenderness over McBurney's point and positive Rovsing's sign. Bloods revealed leucocytosis to  $25.1 \times 10^9/L$ , elevated CRP to 338mg/L. Computed tomography with intravenous contrast demonstrated thickening and hyperenhancement of the appendix with associated thickening of the caecum and ascending colon, mesenteric fat stranding and free fluid within the pouch of Douglas.

A diagnosis of acute appendicitis was made. She was commenced on intravenous antibiotics and underwent laparoscopic appendectomy. Intraoperatively she was found to have a contained perforation at the tip of the appendix with omental phlegmon, and purulent contamination of the peritoneal cavity. The caecum and base of the appendix appeared

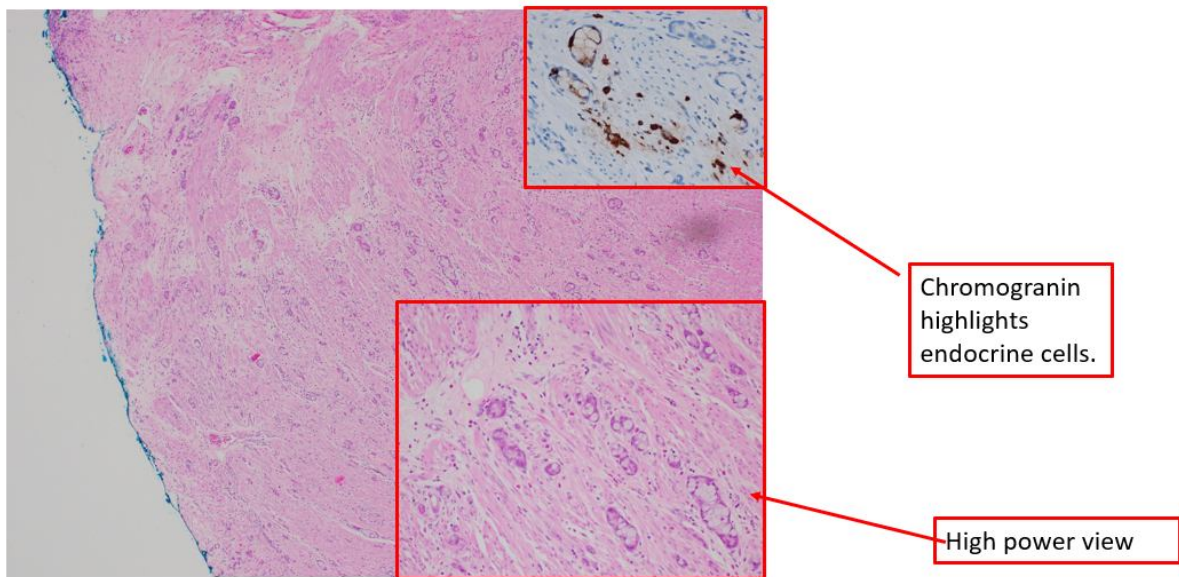
macroscopically normal on laparoscopy, so a routine appendectomy was performed. The peritoneal contamination was washed out and a drain left in situ.

The specimen was sent for histopathological examination. Macroscopically, this demonstrated an inflamed appendix with several diverticulae, of which one at the tip of the appendix was perforated. On microscopic examination, there were several clusters of goblet-like cells, endocrine and Paneth-like cells invading through the muscularis propria into the subserosal tissue and mesoappendix. These clusters were found throughout the entire appendix including the surgical margin, with foci of perineural invasion.

Immunohistochemistry did not demonstrate mismatch repair deficiency. The tumour cells were positive for CK20, CDX2 and demonstrated intermediate to high Ki67 proliferation index. Less than 25% of the cells demonstrated high grade patterns and as such it was considered low grade based on 2019 WHO classification <sup>1</sup>.

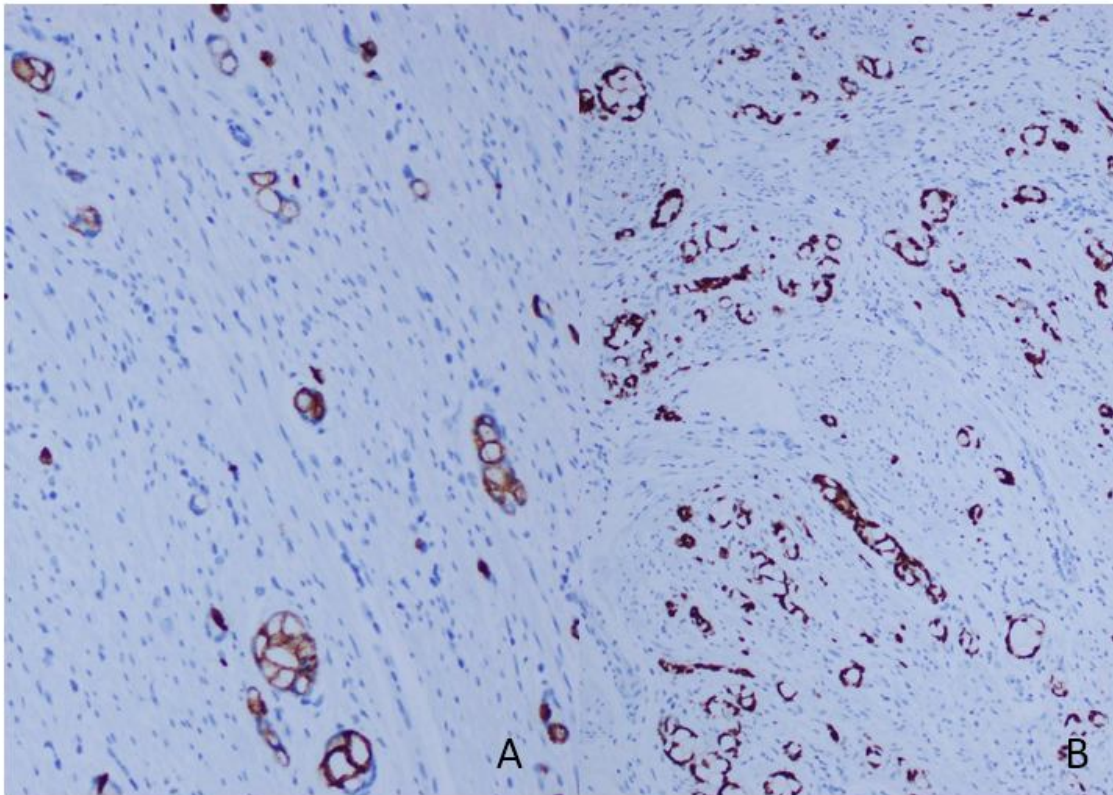
Immunoprofile	
CK20	Positive
CDX2	Positive
Synaptophysin	Positive in some cells
Chromogranin	Positive in some cells
Ki67 proliferation index	Intermediate to high
CK7	Negative

Table 1: Immunoprofile



Clusters and small tubules, composed of goblet-like cells, endocrine cells and Paneth-like cells in the muscularis propria involving the inked margin

Figure 1 - Histopathology



The cells are positive for CK20 (A) and CDX2 (B).

Fig 2: The cells are positive for CK20(A) and CDX2(B)

The patient then underwent further investigations postoperatively. CT of her chest did not demonstrate any obvious metastasis. Blood tests demonstrated a CEA 0.9, CA19.9 of 5 and a CA 125 of 77. Follow up colonoscopy was macroscopically normal, and the patient proceeded to have a completion right hemicolectomy. On histological examination it confirmed residual goblet cell adenocarcinoma extending from the appendiceal stump to the appendicocaecal junction, measuring 16x10mm in size, with associated perineural invasion within the muscularis propria and mesoappendix. 19 of 19 lymph nodes did not demonstrate any metastasis. TMN staging was deemed to be T3N0M0, or stage IIA. She did not receive any further adjuvant therapies.

### 3. DISCUSSION

True congenital diverticulae of the appendix are rare, with an incidence of 0.0014% in patients undergoing appendicectomy. Acquired diverticulae, which are thought to form in a similar process to colonic diverticulae, are more common with an incidence of 0.8-1.7%<sup>2,3</sup>. These are often identified incidentally following appendicectomy for acute appendicitis, and are strongly associated with appendiceal malignancy. Dupre et al identified that up to 48% of cases of appendiceal diverticulae are associated with malignancy, including neuroendocrine tumours, mucinous adenomas, tubular adenomas and adenocarcinomas<sup>2</sup>. Medlicott et al found an associated malignancy in 30% of cases, including adenomas and goblet cell

carcinoids.<sup>2,3</sup> These are often identified incidentally following appendectomy for acute appendicitis and are strongly associated with appendiceal malignancy. Acute appendicitis and appendiceal diverticulitis have similar clinical presentations with a few important differences. Cases of appendiceal diverticulitis are more likely to be associated with perforation and abscess formation, with one case series noting that in 52% of patients later diagnosed with appendiceal diverticulitis did not have a detectable appendix on computed tomography. CT findings favouring appendiceal diverticulitis include absence of fluid in the appendix, absence of appendicolith and abscess formation without a visible appendix. They also found that the incidence of appendiceal diverticulitis in patients undergoing appendectomy in their cohort was up to 9.7%<sup>4</sup>.

Goblet cell adenocarcinomas are a rare combination of both neuroendocrine and epithelial neoplasia and account for less than 5% of appendiceal cancers. Previously known by various names including goblet cell carcinoids, adenocarcinoma ex goblet cell carcinoid, and crypt cell adenocarcinomas, the naming was standardised in the 2019 WHO classification of tumours<sup>1</sup>. They classically do not manifest as discrete masses, but rather with circumferential involvement of the appendiceal wall extending along the length of the appendix<sup>5</sup>.

Tang et al proposed further classification based on histologic features into group A (typical GCC), group B (Adenocarcinoma ex GCC, signet ring cell type), and group C (adenocarcinoma ex GCC, poorly differentiated), with mean survival of 199 months, 43 months and 31 months respectively<sup>5</sup>.

In 2018, Yozu et al developed a grading system with 3 tiers based on proportion of tubular or clustered growth (low-grade pattern) against loss of tubular or clustered growth (high-grade pattern), which has since been adopted as part of the 2019 WHO classification of tumours. Prognosis by grade was similar to that of Tang's with median survival of 204, 86 and 29 months for low, intermediate and high grade<sup>6</sup>.

Historically these tumours have been found to behave similarly to aggressive adenocarcinomas with a high propensity to metastasise, transform into adenocarcinoma of either signet ring cell type or poorly differentiated type. As such staging and treatment of goblet cell adenocarcinomas also follows that of appendiceal adenocarcinomas

TNM staging of goblet cell adenocarcinomas follow that of appendiceal adenocarcinomas as defined by the Union of International Cancer Control (UICC), rather than that of NETs.

Current North American Neuroendocrine Tumour Society (NANETS)<sup>7</sup> and European Neuroendocrine Tumour Society (ENETS) guidelines<sup>8</sup> recommend right hemicolectomy for goblet cell adenocarcinomas regardless of TNM stage due to their high risk of metastasis (lymph node involvement in 20-40% of cases), and poorer survival in metastatic disease. Similar to appendiceal adenocarcinomas, adjuvant systemic therapy with a 5-FU based regimen is recommended for any cases with lymph node involvement. Cytoreductive surgery and hyperthermic intraperitoneal chemoperfusion combined with systemic chemotherapy improves overall survival in patients with GCAs with peritoneal metastases<sup>9</sup>.

Some authors suggest low grade GCAs localised to the appendix without caecal involvement can be managed with appendectomy alone, with a meta-analysis demonstrating no survival benefit of right hemicolectomy in those patients<sup>10</sup>. Pham et al found no significant difference in 5 year survival in patients with stage II to IV disease undergoing appendectomy compared to right hemicolectomy<sup>11</sup>.

F-FDG PET/CT and CEA/CA19-9/CA 125 are useful in detecting recurrence of GCC<sup>12</sup>

#### **4. CONCLUSION**

Appendiceal diverticuli are strongly associated with appendiceal malignancies of all types, with 30-48% of cases associated with malignancy. They uncommonly present with acute appendiceal diverticulitis, or more commonly as incidental findings on histopathology following appendicectomy for acute appendicitis at a rate of anywhere between 0.8-1.7%. CT findings favouring appendiceal diverticulitis include absence of fluid in the appendix, absence of appendicolith and abscess formation without a visible appendix.

Goblet cell adenocarcinomas are a rare but important neoplasm often encountered incidentally after appendicectomy. Due to their rarity and mixed histological features, there has been inconsistency in nomenclature and multiple grading systems created to describe these neoplasms, which now have been recognised to be more similar to adenomas. As a result, they are both staged and treated as adenocarcinomas, though evidence suggests appendicectomy alone is sufficient for lower grade tumours with negative margins. This case report adds to existing knowledge of the natural history of these rare tumours, which in this case was associated with multiple appendiceal diverticulae.

#### **CONSENT (WHERE EVER APPLICABLE)**

Consent was obtained from the patient for publication of this case report including accompanying images.

#### **REFERENCES**

1. Nagtegaal ID, Odze RD, Klimstra D, Paradis V, Rugge M, Schirmacher P, et al. The 2019 WHO classification of tumours of the digestive system. *Histopathology*. 2020;76(2):182-8.
2. Dupre MP, Jadavji I, Matshes E, Urbanski SJ. Diverticular disease of the vermiform appendix: a diagnostic clue to underlying appendiceal neoplasm. *Hum Pathol*. 2008;39(12):1823-6.
3. Kaser SA, Willi N, Maurer CA. Prevalence and clinical implications of diverticulosis of the vermiform appendix. *J Int Med Res*. 2013;41(4):1350-6.
4. Ito D, Miki K, Seiichiro S, Hata S, Kobayashi K, Teruya M, et al. Clinical and computed tomography findings of appendiceal diverticulitis vs acute appendicitis. *World J Gastroenterol*. 2015;21(13):3921-7.
5. Tang LH, Shia J, Soslow RA, Dhall D, Wong WD, O'Reilly E, et al. Pathologic classification and clinical behavior of the spectrum of goblet cell carcinoid tumors of the appendix. *Am J Surg Pathol*. 2008;32(10):1429-43.
6. Yozu M, Johncilla ME, Srivastava A, Ryan DP, Cusack JC, Doyle L, et al. Histologic and outcome study supports reclassifying appendiceal goblet cell carcinoids as goblet cell adenocarcinomas, and grading and staging similarly to colonic adenocarcinomas. *The American journal of surgical pathology*. 2018;42(7):898-910.
7. Boudreaux JP, Klimstra DS, Hassan MM, Woltering EA, Jensen RT, Goldsmith SJ, et al. The NANETS consensus guideline for the diagnosis and management of neuroendocrine tumors: well-differentiated neuroendocrine tumors of the Jejunum, Ileum, Appendix, and Cecum. *Pancreas*. 2010;39(6):753-66.

8. Pape UF, Perren A, Niederle B, Gross D, Gress T, Costa F, et al. ENETS Consensus Guidelines for the management of patients with neuroendocrine neoplasms from the jejunum and the appendix including goblet cell carcinomas. *Neuroendocrinology*. 2012;95(2):135-56.
9. McConnell YJ, Mack LA, Gui X, Carr NJ, Sideris L, Temple WJ, et al. Cytoreductive surgery with hyperthermic intraperitoneal chemotherapy: an emerging treatment option for advanced goblet cell tumors of the appendix. *Ann Surg Oncol*. 2014;21(6):1975-82.
10. Varisco B, McAlvin B, Dias J, Franga D. Adenocarcinoid of the appendix: is right hemicolectomy necessary? A meta-analysis of retrospective chart reviews. *The American Surgeon*. 2004;70(7):593.
11. Pham TH, Wolff B, Abraham SC, Drelichman E. Surgical and chemotherapy treatment outcomes of goblet cell carcinoid: a tertiary cancer center experience. *Ann Surg Oncol*. 2006;13(3):370-6.
12. Clift AK, Kornasiewicz O, Drymoussis P, Faiz O, Wasan HS, Kinross JM, et al. Goblet cell carcinomas of the appendix: rare but aggressive neoplasms with challenging management. *Endocr Connect*. 2018;7(2):268-77.

UNDER PEER REVIEW