

Intramuscular Abdominal wall endometriosis: a case report

ABSTRACT

Abdominal wall endometriosis, is the commonest site of extra pelvic disease, which physiopathology remains unclear. Most of the cases are secondary to gynecologic surgery or obstetrical care. We report a case of a young woman suffering of cyclic right iliac fossa pain. Clinical finding are a deep hard and mobile nodule. Parietal ultrasound identified a hypoechogenic superficial nodule within the rectus muscle measuring 20x08mm. MRI confirmed parietal endometriosis diagnosis. Surgery has been performed with histologic confirmation of parietal endometriosis. The postoperative care were simple. Parietal endometriosis remains a rare entity that required an early diagnosis and management of this entity to prevent during each gynecological or obstetrical surgery.

INTRODUCTION

Endometriosis is defined as the presence of endometrial tissue outside the endometrium, which respond to hormonal demands of the ovaries. The most common locations are pelvic: ovaries, peritoneum, uterine ligaments, rectovaginal fascia. Other extra pelvic locations have been described, particularly in the bladder, the intestine, appendix, umbilicus, kidney and abdominal wall[1], this entity is constituting 1 to 2% of extra genital endometriosis, it occurs most often on abdominal and pelvic scars, uterine surgery scars, caesarean section scars, after amniocentesis [2-3], a laparoscopic surgery, but sometimes outside any context [4].

The incidence of parietal endometriosis after caesarean section varies between 0.03 and 0.4% according to the studies [1.5.6]

We report a case of parietal endometriosis of the abdominal wall, observed in a young woman, 38 years old; mother of two children, one of them was born by caesarean section.

Case Presentation

A 36-year-old married woman with two children presented with cyclic, catamenial pain in the right iliac fossa. The physical examination revealed a 2 cm nodule located in the right iliac fossa above the caesarean scar, while the rest of the examination was unremarkable.

In paraclinical exams, a pelvic parietal ultrasound presence at the right iliac fossa of a superficial nodule within the rectus muscle measuring 20x08 mm, hypoechogenic, well

limited, oval, located on the lateral side of the operative scar, its echo structure resembles uterine tissue. A Pelvic Parietal MRI (figure1) in favor of a muscular endometriotic nodule of the anterior wall.

The excision of the lesion discover a hard mass of 2/1.5 cm (figure 2), attached to the rectus abdominis muscle. The anatomopathological study confirmed the diagnosis of parietal endometriosis. The postoperative care was simple with a good evolution.

DISCUSSION

Endometriosis is a benign pathology but its consequences are variable, endometriosis of the abdominal wall affects women who are genitally active between 20 and 40 years of age [8,9]. For parietal endometriosis the most likely mechanism is local grafting of endometrial cells that will grow in the non-epithelialized areas [10]. Their development is also favored by secondary inflammation induced by immunological factors[11] , Catamenial pain is very suggestive even without in any palpable lesion [12]. Parietal endometriosis presents as nodules or microcystic lesions, red, blue, brown or black, whose size varies between 2 and 3 cm and can go up to 12 cm [13]. Ultrasound is a good method of investigation for tumour masses, given its practicality and low cost. It is not a specific examination for endometriosis, but it allows the following to be determined the parietal origin, size, contours and extension of the of the endometriosis[14] and finally to eliminate the differential diagnoses. The CT scan is not characteristic, classically it is a tissue mass taking the contrast after injection because of the vascular character of the lesion; in addition, it can be useful to specify the relationships of the nodule in depth. MRI is very specific; it can identify smaller lesions and distinguish signs of organized hemorrhage in endometriosis, which suggests this diagnosis. Medical treatment by medicated castration has been carried out based on powerful progestins "Danazol" and GnRH agonists [15], but the reference treatment remains the surgical removal of the lesion, however in cases of large defect in the anterior abdominal surface can required to be covered by reconstruction[16].

CONCLUSION

Parietal endometriosis is certainly a rare pathology, but its diagnosis should be considered, particularly in women who have undergone a gynaecological or obstetric surgery and who present pain, whether or not associated with menstrual disorders. The treatment is essentially surgical.

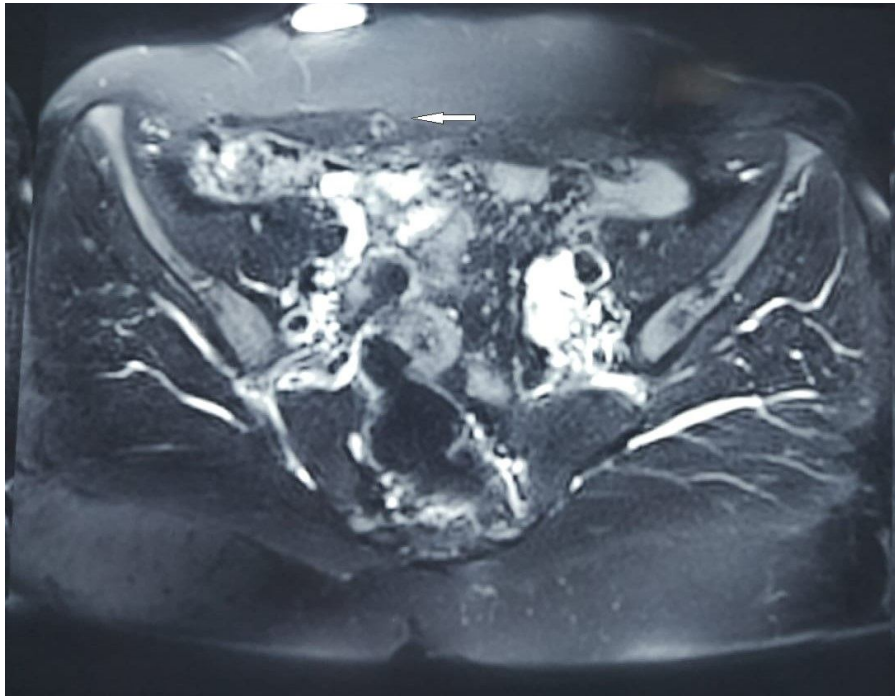


Figure 1: image of endometriotic image on MRI

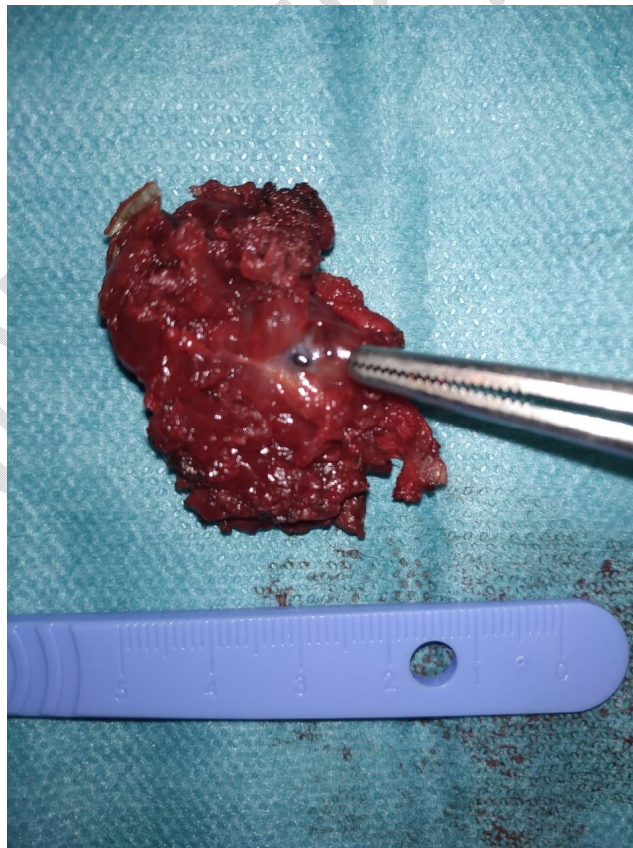


Figure 2: image showing the resected mass

REFERENCES

1. Kaunitz A, Di Sant'Agnes PA. Needle tract endometriosis: an unusual complication of amniocentesis. *Obstet Gynecol* 1979; 54: 753–5
2. Hughes ML, Bartholomew D, Paluzzi M. Abdominal wall endometriosis after amniocentesis. A case report. *J Reprod Med* 1997; 42: 597–9.
3. Abdominal wall endometrioma following cesarean delivery: a case report. *J Reprod Med*. 2008 Nov;53(11):881-2.
4. Tomas E, Martin A, Garfia C, Sanchez Gomez F, Morillas JD, Castellano Tortajada G, et al. Abdominal wall endometriosis in absence of previous surgery. *J Ultrasound Med* 1999; 18:373–4.
5. Abdominal wall endometrioma; a 10-year experience and brief review of the literature. Bektas H, Bilsel Y, Sari YS, et al. *J Surg Res*. 2010;164:0–81
6. Cesarean scar endometriosis: an uncommon surgical complication on the rise? Case report and literature review. Khachani I, Filali Adib A, Bezad R. *Case Rep Obstet Gynecol*. 2017;2017:8062924.
8. Blanco RG, Parithivel VS, Shah AK, Gumbs MA, Schein M, Gerst PH. Abdominal wall endometriomas. *Am J Surg* 2003; 185: 596-8
9. Zhao X, Lang J, Leng J, Liu Z, Sun D, Zhu L. Abdominal wall endometriomas. *Int J Gynaecol Obstet* 2005; 90: 218-22
10. Elabsi M, Lahlou MK, Rouas L, Essadel H, Benamer S, Mohammadine A, et al. L'endométriose cicatricielle de la paroi abdominale. *Ann Chir* 2002;127: 65–7.
11. Patterson GK, Winburn GB. Abdominal wall endometriomas: report of eight cases. *Am Surg* 1999; 65: 36–9.
12. Emre A, Akbulut S, Yilmaz M, Bozdog Z. Laparoscopic trocar Port site endometriosis: a case report and brief literature review. *Int Surg*. 2012 Apr-Jun; 97(2): 135-9
13. Bumpers HL, Butler KL, Best IM. Endometrioma of the abdominal wall. *Am J Obstet Gynecol* 2002; 187: 1709–10
14. Solak A, Genc B, Yalaz S, Sahin N, Sezer TO, Solak I. Abdominal wall endometrioma: ultrasonographic features and correlation with clinical findings. *Balkan Med J*. 2013;30(2): 155-60.
15. V Selak 1, C Farquhar, A Prentice, A Singla. Danazol for pelvic pain associated with endometriosis. *Cochrane Database Syst Rev*. 2000;(2):CD000068.
16. Collins AM, Power KT, Gaughan B, Hill AD, Kneafsey B. Abdominal wall reconstruction for a large caesarean scar endometrioma. *Surgeon* 2009;7:252–253.