

Atypical Presentation of Pleomorphic Adenoma: Case Report

ABSTRACT

Introduction: Salivary gland tumours are uncommon, accounting for less than 5% of all head and neck neoplasms. Most of the malignancies in this area are located in the major salivary glands, which include the parotid, submandibular, and sublingual glands. The numerous small salivary glands can be found under the mucosa all throughout the aerodigestive tract. They make up less than 5% of all tumours of the salivary glands.

Presentation of case: A 50-years old patient presented to our department for discomfort over the Right half of the head and giddiness intermittently for a period of about 13 months, pain over the right side of the neck, difficulty in swallowing, and swelling of the right tonsil for about four months. On examination of the throat, a moderately enlarged right tonsil with minimal congestion was seen. We performed a tonsillectomy and the anatomopathological examination concluded to pleomorphic adenoma.

Conclusion: Pleomorphic adenoma is a rare benign tumor of Salivary gland; it's exceptional to be located in the tonsil. The treatment choice of pleomorphic adenoma is wide surgical excision. Because of high recurrence rate after surgical excision, long-term follow-up is necessary

Keywords: Pleomorphic adenoma; tonsil; accessor salivary gland; tumor.

1. INTRODUCTION

“Salivary gland tumors are rare and represent less than 5% of all head and neck neoplasms. The major salivary glands, which include the parotid, submandibular and sublingual glands, account for most of the tumors in this region. The minor salivary glands are numerous and are scattered under the mucosa along the aerodigestive tract. They account for less than 5% of all salivary gland tumors” [1].

“The term pleomorphic shows the diversity of the histology of the tumor. The essential components are the capsule, epithelial and myoepithelial cells, and mesenchymal or stromal elements” [2].

“The treatment of pleomorphic adenoma is surgical excision. Enucleation of pleomorphic adenoma is not suitable because of the tumor relapse, which is due to incomplete surgical resection of the lesion” [2].

The following case describes a rare case of pleomorphic adenoma of the tonsil in a 50 year old man.

2. CASE PRESENTATION

A 50-years old patient presented to our department for discomfort over the Right half of the head and giddiness intermittently for a period of about 13 months, pain over the right side of the neck, difficulty in swallowing, intermittent regurgitation, deafness and blockage of the right ear and swelling of the right tonsil for about four months.

The patient had no pharmacological allergies, no psychosocial problems, smoking and no family genetic disease.

On examination of the throat, a moderately enlarged right tonsil with minimal congestion was seen. (Fig. 1) The right peritonsillar region was also congested. The rest of the oral cavity appeared normal. On palpation, the right tonsil was firm and mildly tender. There were no cervical nodes palpable. The rest of examination was normal.

In investigation of his medical history, the patient declares been treated one 4 months earlier by Antibiotic (amoxicillin 2G/day for 10 days); that failed to reduce the swelling either symptomatology of the patient.

We performed a tonsillectomy diagnostic under general anaesthesia with nasotracheal

intubation, during the operation we removed both palatine tonsils in monobloc each, the pillars were respected, there was no complication during the operation (Fig. 2).

The anatomopathological examination identified; at Microscopy a proliferation of glandular cells of polymorphic appearance arranged in clusters

with glandular tubes or trabecular formations. The stroma is fibro-hyaline and myxoid in places. In some areas there are chondroid patches and foci of calcification (Fig. 3).

At the one-month post-operative check-up, the patient was symptom-free and healing was complete.

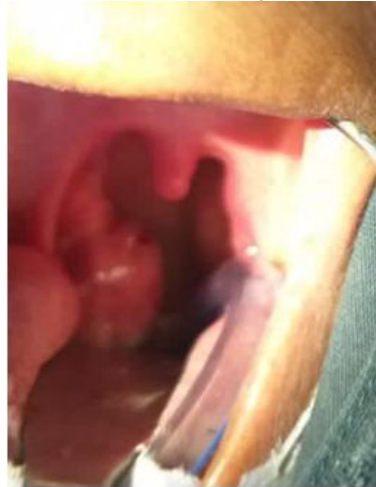

Fig. 1. Right tonsil hypertrophia with visible nodule

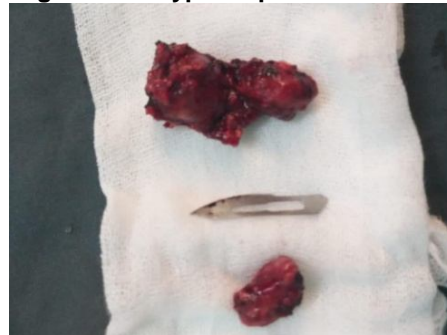

Fig. 2. Asymmetric size of tonsils

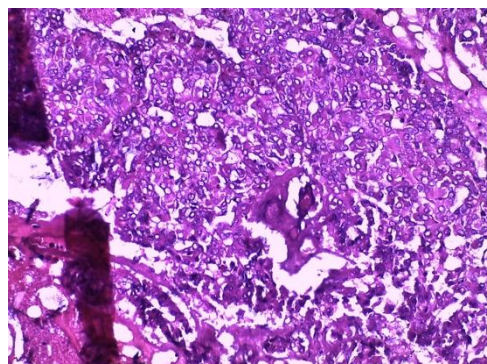


Fig. 3. A proliferation of glandular cells of polymorphic appearance

3. DISCUSSION

Pleomorphic adenomas of the accessory salivary glands are very common [3] According to Chaudhary et al, pleomorphic adenoma accounts

for more than 56% of all intraoral accessory salivary gland tumours [4]. The preferred location of pleomorphic adenomas of the accessory salivary glands is the palate, followed by the lip and cheek. Involvement of the tonsils is exceptional.

Pleomorphic adenoma of the accessory salivary glands affects women more often than men with ratios varying between 1:1.1 [5] and 1:3.2 [6]. In the paediatric age group, salivary gland tumours are extremely rare [7]. Indeed, palatal localisation in children under 14 years of age has been described in only five publications in the entire English literature, moreover only few reports have been published for tonsil localization of pleomorphic adenoma.

At the clinical stage, the differential diagnosis is with all benign tumours of the oral mucosa with a nodular appearance:

- Connective tumours: fibroma; lipoma; myxoma;
- Dysembryoplastic tumours: ectopic thyroid nodule; thyroglossal tract cyst; dermoid and epidermoid cysts; lymphoepithelial cyst ;
- Muscle tumours: leiomyomas; rhabdomyoma ;
- Nerve tumours: schwannomas; neuroma; amputation neuroma; Abrikossoff's tumour.

The definitive diagnosis is essentially based on the analysis of the surgical specimen.

On section, the tumour is round or ovoid and well limited. The appearance is whitish and inhomogeneous, slightly translucent in places. The consistency is sometimes soft, sometimes firm. The tumour is not surrounded by a true capsule but by a more or less thick and continuous layer of connective tissue condensed during tumour growth [8].

The tumor has a double contingent. It has epithelial cells in the form of solid lobules or grouped around glandular cavities. These cells can sometimes take on a squamous appearance [8]. In addition to the myoepithelial cells which are spindle-shaped or star-shaped and which are arranged in compact or scattered layers, some of them may have a plasmocytic appearance [9]. Finally, the stroma, which is very variable in appearance, is classically myxoid or chondroid [8].

The gold standard of treatment is surgery. in the accessory salivary glands salivary glands: removal should be complete, beyond the tumor

with a safety margin of 0.5cm [10]. The limits of the surgical specimen must be healthy on examination histopathology [11].

Complications that can be seen are mainly tumor recurrence and malignant transformation. Long-term clinical and radiological surveillance is required after treatment to monitor these complications.

The prognosis of pleomorphic adenoma in the accessory salivary glands is considered better than that of the parotid gland.

4. CONCLUSION

Pleomorphic adenoma is a rare benign tumor of Salivary gland; it's exceptional to be located in the tonsil. Pleomorphic adenoma can be treated with extensive surgical resection. Long-term follow-up is required since surgical excision has a high recurrence rate.

ETHICAL APPROVAL

As per international standard or university standard written ethical approval has been collected and preserved by the author(s).

CONSENT

As per international standard or university standard, patients' written consent has been collected and preserved by the author(s).

COMPETING INTERESTS

Authors have declared that no competing interests exist.

REFERENCES

1. Waldron CA, el-Mofty SK, Gnepp DR. Tumors of the intraoral minor salivary glands: A demographic and histologic study of 426 cases. *Oral Surg Oral Med Oral Pathol.* 1998;66:323–333.
2. Clauser L, Mandrioli S, Dallera V, et al. Pleomorphic adenoma of the palate. *J Craniofac Surg.* 2004;15:1026Y1029.
3. Frible WJ, Elzay RP. Tumors of minor salivary glands: A report of 73 cases. *Cancer.* 1970;25:932–41.
4. Chaudhry AP, Vickers RA, Gorlin RJ. Intraoral minor salivary glands tumors: An analysis of 1414 cases. *Oral Surg Oral Med Oral Pathol.* 1961;14:1194–226.

5. Eveson JW, Cawson RA. Tumours of the minor (oropharyngeal) salivary glands: A demographic study of 336 cases. *J Oral Pathol.* 1985;14(6):500-9.
6. Isacsson G, Shear M. Intraoral salivary gland tumors: A retrospective study of 201 cases. *J Oral Pathol.* 1983;12:57-62.
7. Pogrel A. The management of salivary and tumors of the palate. *J Oral Maxillofac Surg.* 1994;52(5):454-9.
8. Hernandez-Prera JC, Skálová A, Franchi A, Rinaldo A, Vander Poorten V, Zbären P, et al. Pleomorphic adenoma: The great mimicker of malignancy. *Histopathology.* 2021 Sep;79(3):279–90.
9. Lopes M A, Kowalski L P, Santos G C, Almeida O P. A clinicopathologic study of 196 intraoral minor salivary gland tumors. *J Oral Pathol Med.* 1999;28:264–7.
10. Loke WL, Rahimi S, Brennan PA. An update on extracapsular dissection for the management of parotid gland pleomorphic adenoma. *Journal of Oral Pathology & Medicine.* 2022 Mar;51(3):219-22.
11. Lazow SK, Colacicco L, Berger J, Gold B. An unusually large pleomorphic adenoma of the soft palate. *Oral Surg Oral Med Oral Pathol.* 1984;58:386.

© 2022 Dih et al.; This is an Open Access article distributed under the terms of the Creative Commons Attribution License (<http://creativecommons.org/licenses/by/4.0>), which permits unrestricted use, distribution, and reproduction in any medium, provided the original work is properly cited.

Peer-review history:
The peer review history for this paper can be accessed here: