

## Case study

### **Our initial experience with combined endo-laparoscopic surgery (CELS) for removal of a large benign colorectal polyp**

#### **Abstract**

Large benign-looking polyps that are not amenable to endoscopic polypectomy may require bowel resection for removal. Although laparoscopic resection of bowel has improved short term outcomes in patients, there are still risks associated with bowel resection. A combined approach using both endoscopy and laparoscopy in carefully selected patients with large benign polyps not amenable to endoscopic removal have been described to as an alternative. Studies have shown that both short term and long term outcomes are safe and effective as a technique to remove such polyps.

We present a case report of our initial experience with this technique, a summary of patient's selection for this technique as well as a review of the outcomes of this technique from available evidence.

*Keywords: Combined endo-laparoscopic surgery, laparoscopy, benign polyps, polypectomy*

#### **Introduction**

The adoption of colorectal cancer screening via colonoscopy has been successful in reducing the overall mortality from the disease, but has precipitated an increase in the detection of complex polyps which sometimes cannot be managed by simple endoscopic polypectomy. These patients are then referred for surgical management which traditionally meant undergoing segmental colonic resection.

In place of resection, combined endoscopic and laparoscopic surgery (CELS) has been described as an alternative in select patients. This method of polypectomy was first described in 1993 as a means to avoid the morbidities associated with a colectomy<sup>1</sup>, and subsequently other different approaches and techniques have been described including laparoscopic assisted polypectomy, full thickness **CELS**, full thickness laparoscopic endoscopic excision (FLEX) and endoluminal surgical intervention (ELSI)<sup>2</sup>. The safety and effectiveness of these procedures has been established in multiple retrospective and observational studies as well as systematic reviews demonstrating low complication rates, high rates of successful resection with colectomy as well as no malignant lesions developing in patients with completely resected benign polyps on histopathology.

One of the first papers described by Dirk Wilhem et al in 2008<sup>3</sup> describing his 10 year experience and follow-up in 146 patients who had undergone this combined technique

and showed that it is an efficient, safe and minimally invasive alternative to open resection for selected patients with difficult benign polyps.

From an economic perspective, the adoption of CELS shows potential cost savings for both the patient as well as healthcare systems. Most patients undergoing CELS can be discharged one day after the procedure which confers substantial savings from reduced inpatient hospital utilization<sup>4,5</sup>.

We describe a patient who underwent the CELS procedure at our institution. We aim to provide an overview of the techniques associated with CELS and proposed recommended pre-operative workup and intra-operative procedure and set-up for a surgeon attempting to embark on CELS.

### Case report

Patient A, is a 64 year old Chinese gentleman who underwent combined endoscopic/laparoscopic polypectomy (CELS) for a descending colon polyp in June 2016.

He underwent colonoscopy initially in April 2016 and was noted to have 15mm pedunculated friable colonic polyp 45cm from anal verge (Image 1). During the colonoscopy, it was deemed by the endoscopist to not be amenable to endoscopic removal due to the location of polyp and hence biopsies were performed. Tattoo of the polypectomy site was also performed. The histology then was tubo-villous adenoma with low grade dysplasia. He was then counselled on the various options for complete removal of the polyp and eventually underwent CELS procedure in June 2016.

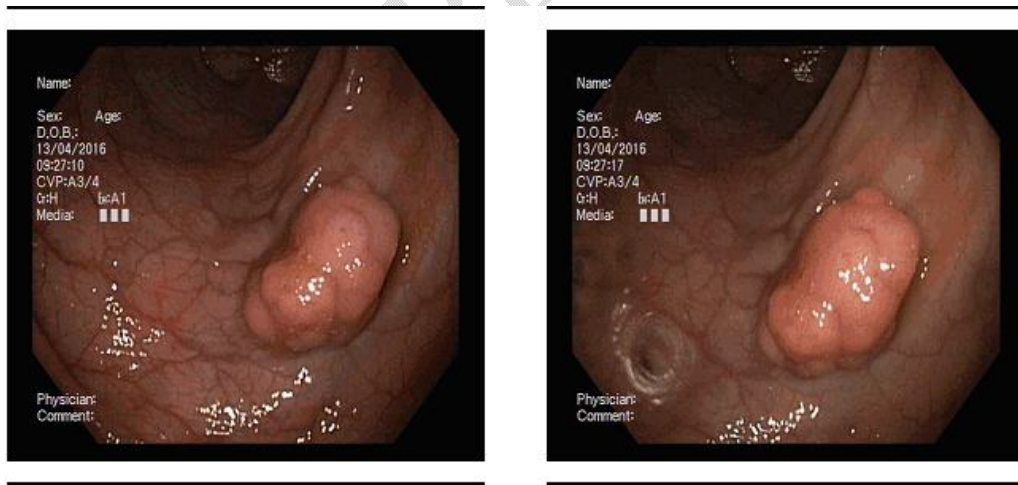
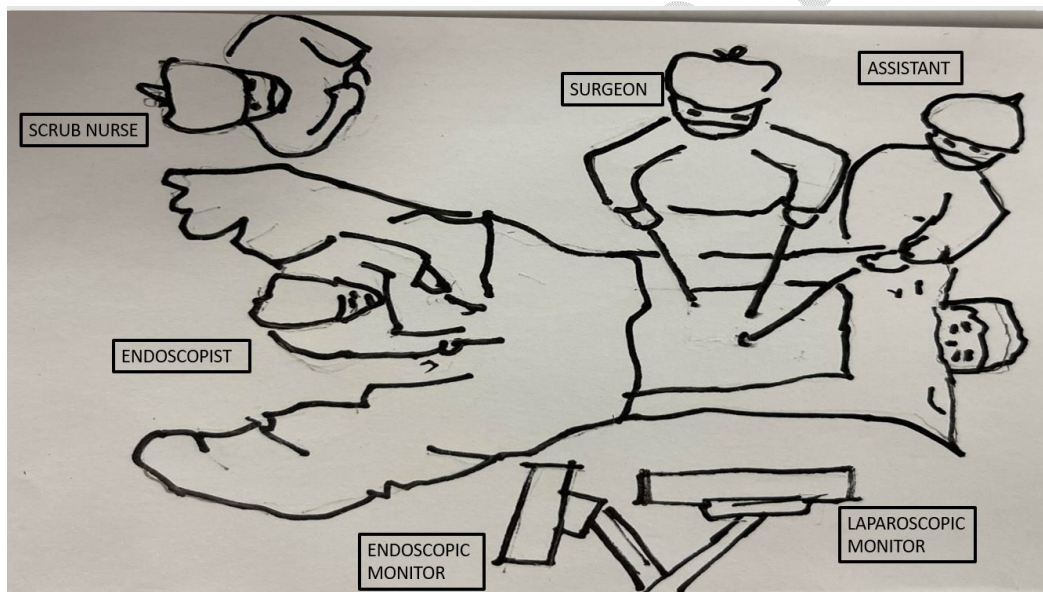


Image 1: Colonoscopy images of polyp

Prior to surgery, patient was given bowel preparation the night before, but did not require admission to hospital one night before. The surgery was performed under general anesthesia and the patient placed in a Lloyd-Davis position for the surgery. The laparoscopy monitor was placed on the patient's left while the colonoscopy monitor was

on the right to facilitate optimal view and positioning for both the endoscopist and the surgeon.

The surgery commenced by the introduction of pneumoperitoneum with CO<sub>2</sub> which was achieved by insertion of the 12mm Kii balloon port at the infra-umbilical region. The other laparoscopic port placements would include 5mm port in right iliac fossa (RIF), 12mm port in the right hypochondrium (RHC), and 5mm port in the left iliac fossa (LIF) (Illustration 1). After diagnostic exploration, the descending colon was then mobilized as if for a resection and the distal transverse colon then clamped using a deployable bull-dog clamp to prevent proximal distension. Colonoscopy using CO<sub>2</sub> insufflation was then performed next by another surgeon to confirm the presence of the polypectomy site by visualizing the area marked by the tattoo. The polyp was a 25mm broad-based polyp on the mesenteric border of the descending colon. The visualization of the polyp was aided by bowel manipulation by the surgeon with bowel graspers to optimize the position of the polyp. The polypectomy base was first injected with saline and then polyp was removed completely with a rigid snare and extracted transanally. The mucosal defect was then closed with multiple endoscopic clips. Prior to closure, a diagnostic laparoscopy was performed to ensure that no serosal defects were present. There were no immediate complications intra-operatively.



*Illustration 1 – Intra-operative set-up and positioning of equipment during surgery*

The patient recovered well and was discharged from the hospital on post-operative day 1. Final histology revealed tubovillous adenoma with high-grade dysplasia with no evidence of invasive carcinoma. Surveillance colonoscopy was performed at 3 and 5 year follow up with no evidence of recurrence.

### **Pre-operative work-up and patient selection**

Indications for CELS would include large benign colonic polyps that cannot be removed by endoscopic polypectomy. A polyp that has been incompletely removed via traditional methods may also be considered for CELS<sup>2,6</sup>. It should be not performed in patients with known malignancy, known polyposis syndrome or lesions with high risk features.

In addition to history and physical examination (paying attention to previous surgical scars), it is prudent to review the initial colonoscopy report and images prior to offering CELS. It would also be recommended that the performing surgeon repeat the colonoscopy to verify polyp location, size and absence of concerning features. During the consent taking session, patient should also be counselled that the surgeon may proceed with formal surgical resection if:

1. The lesion intra-operatively is not amenable to removal by CELS
2. There are features concerning for malignancy
3. The final histology reveals malignancy in the polyp requiring a formal resection

As there would potentially be a need to proceed for formal oncological resection in the same setting due to difficulty with removal of the polyp, the performing surgeon should also be one who is credentialed to perform a laparoscopic oncological resection.

### **Surgical Technique**

The technique used in our patient is known as the laparoscopic-assisted polypectomy. It is also the most widely employed CELS technique.

Our patient was placed in the Lloyd-Davis position to facilitate simultaneous operation by the endoscopist and the abdominal surgeon. This position is also optimal if we were to proceed with a formal oncological resection or resection should the CELS technique fail.

During the colonoscopy, the lesion should be re-examined to confirm the characteristics of the lesion. CO<sub>2</sub> insufflation is recommended as colonic distension is minimized, providing adequate simultaneous endoscopy and laparoscopic visualization. We would advise upon bowel clamping performed close to the intended polypectomy site (which is visualized also by the area of tattoo) to further minimize unnecessary bowel distension.

Abdominal access via laparoscopy is done via the standard technique. The use of combined laparoscopy with endoscopy overcomes the challenges of an inaccessible polyp location as well as examination of the serosal side of the polypectomy site for any injury which can then be reinforced with sutures or repaired. During laparoscopy, the abdominal surgeon can assist by manipulating the colon and straightening out the colon wall in order to for polyp to be removed endoscopically.

During sub-mucosal injection of the polyp, it is important to note if the lesion elevates or remains immobile which may then signify the presence of an occult invasive tumour. The removal of the polyp is then removed via a Roth net and extracted transanally.

After removal of the polyp, it should be examined prior to sending it to the pathology lab. Hard and firm lesions should raise suspicion of occult malignancy. Routine frozen sections are not necessary.

At the end of the endoscopic removal of the polyp, the serosal aspect of the polypectomy site must be closely examined for any serosal breach or thermal injury. Any areas of concern should be immediately reinforced or repaired with laparoscopic imbricating sutures<sup>8</sup>.

### **Post-operative care**

In our institution, we would recommend that the patient be routinely admitted for observation overnight. In the case where there is serosal injury or breach, it would certainly be advisable for in-hospital monitoring to ensure no immediate or delayed post-operative complications such as a leak.

There has been no consensus guiding the first interval colonoscopy after CELS procedure even in the reviewed literature. We would recommend repeat colonoscopy at 3 months post-resection. Subsequent interval of surveillance would be dependent on the final histology of the polyp which is guided by international guidelines.

### **Discussion**

Combined endoscopic and laparoscopic surgical techniques do facilitate successful removal of challenging and complex polyps without the need for colectomy. The largest study to date was reported by Franklin et al<sup>9</sup> who described this technique and successfully performed this in 80.9% of the patients in the study. Furthermore, these procedures are demonstrated to be safe and can be even be performed by surgeons who are fairly new to this technique. The post-operative morbidity is low as described in the literature. Franklin and Portillo reported a 9% post-operative complication rates with all complications being minor and consisting mostly of ileus, atelectasis and seroma whilst Garrett reported an overall rates of 4.2% including urinary retention and wound hematoma<sup>6</sup>. Only Wilhem et al did report a re-operation rate of 4% (n=7) due to post-operative complications from CELS such as delayed bleeding and wound infection leading to an intra-abdominal phlegmon.

The conversion rates to a formal resection due to technical difficulties from CELS is also low. Wilhem et al described the conversion rates of 5% due to bowel perforation during surgery (n=1), difficult closure of the colotomy (n=2) and incomplete resection of rectal lesion (n=1). Franklin and Portillo reported 8% of patients requiring resection in the same setting due also to technical difficulties such the location of polyp and problems with the technique.

It has also been described as a dynamic process as although the surgeons decide on one surgical technique prior to surgery, it may be changed as the procedure progresses

depending on the anatomy, and intra-operative proceedings. For example, 1) laparoscopic mobilization of flexures and angulated colon or adhesions can provide better access and exposure after laparoscopic visualization, 2) colon overlying the polyp can be invaginated to assist in snaring of a flat polyp during the endoscopic procedure or 3) serosal breach to the colon after polypectomy can be recognized and repaired immediately. As such, even though the surgeons are new to this combined endoscopic and laparoscopic technique, they should be skilled in both laparoscopic and endoscopic techniques. This can further circumvent the conversion of this CELS procedure to a formal resection due to technical difficulties.

The long-term outcomes, in particular the local recurrence rates, of patients who had gone through the CELS technique, are variable but considered low. Dirk et al<sup>3</sup>, reported the local recurrence rate of 0.9% (1 patient) which was detected 2.6 years from the index procedure, whilst Franklin reported no recurrences at the polypectomy site over a median follow-up of 65 months. Garrett and Lee<sup>6</sup> reported the highest recurrence rates of 10% over a median follow-up duration of 65 months, but did not state if it was local or metachronous polyp recurrence.

### **Conclusion**

In conclusion, this procedure is safe and effective for selected patients with difficult benign polyps not amenable to endoscopic polypectomy. It can be a suitable alternative to formal bowel resection in such instances. Our patient has had a good outcome 5 years from index surgery which is the first to be done in our institution. We will seek to embark on such a technique on more patients who are suitable and will benefit from such a procedure.

## References

1. Beck DE, Karulf RE. Laparoscopic-assisted full-thickness endoscopic polypectomy. *Dis Colon Rectum* 1993; 36: 693-5
2. Erik R. Noren, Carey Wickham, Sang W. Lee. Current techniques for combined endoscopic and laparoscopic surgery (CELS). *Annals of Laparoscopic and Endoscopic Surgery* 2019; 4:77.
3. Dirk W, Stefan Von D, Lars W et al. Combined laparoscopic-endoscopic resections of colorectal polyps: 10 year experience and follow-up. *SurgEndosc* (2009) 23: 688-693.
4. Sharma S, Xing J, Nakajima K et al. Combined endo-laparoscopic surgery is significantly less costly than traditional surgery. *J AM CollSurg* 2015; 221: S29
5. Jayaram A, Barr N, Plummer R et al. Combined endo-laparoscopic surgery (CELS) for benign colon polyps: a single institution cost analysis. *SurgEndosc* 2018.
6. Kelly A Garrett, Sang W Lee. Combined Endoscopic and laparoscopic surgery. *Clin Colon Rectal Surg* 2015; 28:140-145
7. Nakajima K, Lee SW, Sonada T, Milsom JW. Intra-operative carbon dioxide colonoscopy: a safe insufflation alternative for locating colonic lesions during laparoscopic surgery. *SurgEndosc*. 2005; 19:321-325
8. Yan J, Trecheva K, Lee SW et al. Treatment for right colon polyps not removable using standard colonoscopy; combined laparoscopic-colonoscopy approach. *Dis Colon Rectum* 2011; 54: 753-8
9. Franklin ME Jr, Leyva-Alvizo A, Abrego-Medina et al. Laparoscopically monitored colonoscopic polypectomy: an established form of endoluminal therapy for colonic polyps. *SurgEndosc* 2007; 21: 1650-1653
10. Franklin ME, Portillo G. Laparoscopic monitored colonoscopy polypectomy; long-term follow up. *World J Surg* 2009; 33 (6): 1306-1309