

LARGE RECURRENT DESMOID TUMOUR OVER ANTERIOR ABDOMINAL WALL: A CASE REPORT

ABSTRACT

Desmoid tumours are slow-growing tumours derived from musculo-aponeurotic tissue. Desmoid tumours are considered among the rarest of the soft tissue neoplasms and histologically benign with no metastatic potential but locally aggressive. They are known for recurrences. Here we are presenting a case of 30yr old female who presented with a recurrent swelling over abdomen and pain with decreased appetite. She was diagnosed to have extra-peritoneal desmoid tumour over anterior abdominal wall managed by radical resection with mesh repair. Patient recovered well and is on follow up since 3 years.

KEYWORDS: Desmoids tumours, Desmoid, extra-peritoneal tumour, extra-peritoneal swelling.

INTRODUCTION

"Muller coined the term Desmoid in 1838. It's derived from the Greek word desmos, which means tendon-like. A desmoid tumor is a type of neoplasm originating from the musculo-aponeurotic structures throughout the body. Desmoid tumors account for 0.03% of all neoplasms and 3% of soft tissue tumors" [1]. "They are most commonly seen in females than males, with a female to male ratio of 2:1 and in the range of 25-35 years" [2]. "They are frequent in the reproductive age. Desmoid tumors can arise in virtually any part of the body and are tumors that arise from cells called fibroblasts. Commonly they occur sporadically. Genetic associations with familial adenomatous polyposis (FAP) and Gardner syndrome also exist".[3] "They are benign neoplasms and often appear as infiltrative, well-differentiated overgrowth of fibrous tissue. They are locally aggressive. Desmoid tumors grow and invade surrounding tissues with negligible potential for metastasis. The tumors have a higher recurrence rate, especially, if excision is incomplete. There is no reported association with metastatic disease" [4].

CASE REPORT:

A 30-year-old woman presented with a recurrent swelling in the anterior abdominal wall and pain in abdomen. With decreased appetite and anorexia and repeated episodes of vomiting after food intake. Clinically it was a lump of size of around 20cm x 18cm on the anterior abdominal wall extending in the supra-umbilical, umbilical and infra-umbilical region which was non tender, non-pulsatile, irregular in shape and bosselated surface. There were multiple dilated veins on the skin over the

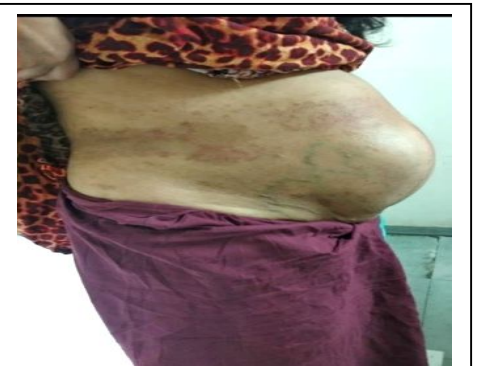

Figure 1. Anterior abdominal wall swelling before surgery showing dilated veins on the skin over the swelling.

lump. **[Figure 1]**. She was operated twice once in 2015 and other in 2017 respectively for similar complaints with small lumps with histopathology s/o desmoid tumor of the anterior abdominal wall.

Computerized Tomography of Chest, Abdomen and pelvis was done which was s/o large lobulated isodense lesion of size 11.9 x 19x18cm arising from the muscular layer of the anterior abdominal wall extending into the pelvis with maintained planes within the peritoneal cavity. No adhesion with bowel or any metastasis noted. **[Figure 2]**

Intra-operatively a lump of 30cm x25cmx18cm swelling arising from anterior abdominal wall muscles extending from epigastric region to inferior pubic symphseal joint was noted. No involvement of the bowel or any intra-peritoneal structures. Attachments to the bladder were separated easily. Wide excision of the mass with excision of the involved skin and muscles. **[Figure 3]**. The excised tumor weighted 4.5kgs. After excision there was a defect of size 24 x 18 cm in the anterior wall. Anterior and posterior compartment release was done to narrow down the defect to 18 x 15cm. Abdominal wall was reconstructed with two 20x15 cm dual mesh placed horizontally and fixed in midline with sutures and attached to the edges of remnant muscle with prolene sutures. **[Figure 4]**.

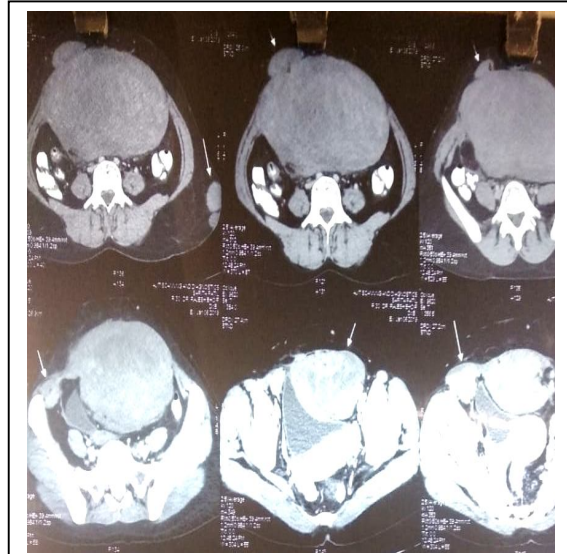


Figure 2. CT image showing the lump – coronal and sagittal sections

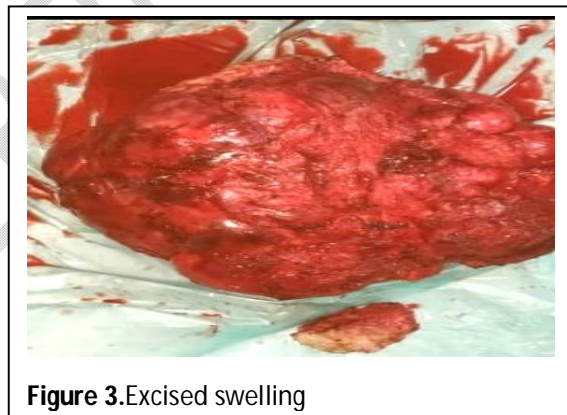

Figure 3. Excised swelling

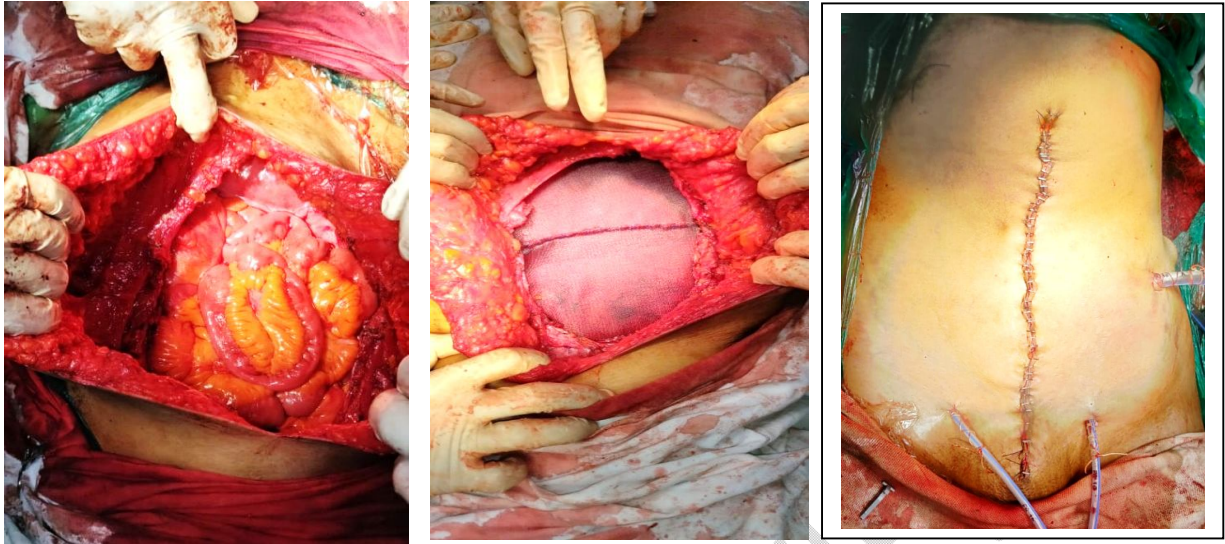


Figure 4.intra-op picture (A) After removal the swelling.(B)Two 20x15cm dual mesh placed horizontally fixed to the edges of remnant muscle.(C) Skin Closure.

We were able to save skin flaps which were then approximated to cover the mesh.The postoperative course was uneventful. Abdominal and subcutaneous drains were removed on POD 4 and 8 respectively. Patient was started on orals on POD 2 and she was discharged on POD 9. Suture removal was done after 13 days.

Histopathology report s/o -- show benign spindle cell lesion with the cells having elongated pointed nuclei, few show vesicular nuclei. The cells are separated by hyalinizedstroma with few inflammatory cells. The cell infiltrated the surrounding skeletal muscle and fat, focally stroma show myxoidchange [Figure 5](IHC positive for β -catenin (nuclear) & SMA (focal)).S/o Desmoid Fibromatosis.

Medical Oncology opinion taken post-operatively who advised for regular follow up, patient might need radiotherapy if there is recurrence. CECT abdomen and pelvis done after 6 months showed no recurrence. Patient is on regular follow up since last 3 years with no recurrence yet.

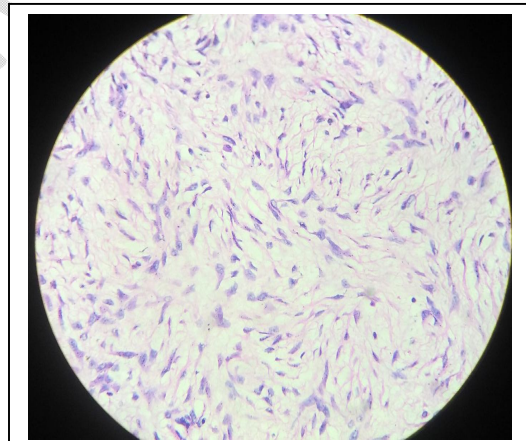


Figure5. Photomicrograph showing a proliferating spindle-shaped cells disposed within a myxoid background ($\times 100$)

DISCUSSION

“Desmoid tumors usually occur in young females who are in their reproductive ages, giving credence to the positive role of estrogen in tumor growth. The case reported also occurred in a young female. Abdominal desmoid tumors occur sporadically or are associated with some inherited syndromes, such as FAP. The reported case may have occurred sporadically as there was nothing clinically to suggest FAP in the patient” [2].Lefevre et al.[5]

reported that “37%–50% of desmoidtumors are initiated in the abdominal area. There are different stages of desmoidtumor and the treatment changes as per the stage of the tumor [Table 1]”.

Stage	Size	Symptoms	Growth	Treatment Recommendation
I	<10 cm	Asymptomatic	Stable	Observation ± NSAIDs
II	<10 cm	Mild Symptoms	Stable	NSAIDs ± anti-estrogen drugs, Resection
III	10–20 cm	Moderate Symptoms	Slow Growing	NSAIDs + anti-estrogen drugs, Cytotoxic Therapy
IV	>20 cm	Severe Symptoms / Complications	Rapid Growing	Resection

Table 1: Different stages and treatment recommendation of desmoidtumour.

“Surgery must be radical with the intent of achieving wide margins. This may leave extensive parietal loss of substance. However, it may not prevent recurrence which can occur in 20 to 30% of cases after complete resection. This necessitates the need for a regular follow-up strategy to be adopted after treatment. The recurrence rate can be more than 50% in resection R1 and R2” [6]. “The median time to recurrence reported in the literature is 14 to 17 months” [6]. “This situation leads to repeated operations. The quality of surgical excision is a major prognosis factor that influences tumor control and functional outcome, but not survival” [6]. “According to some authors, tumor stabilization or regression after the active phase of about 3 years is possible” [10]. In this regard, the aggressiveness of treatment must be taken into account and compared to the benignity of the disease.

“Radiotherapy can be used preoperatively for local control of the tumor or postoperatively to decrease local recurrence or as the main treatment option for nonsurgical patients. In recurrent or non-resectable cases where surgery is contraindicated, chemotherapy along with pharmacological agents (anti-estrogens and non-steroidal anti-inflammatory drugs) is the treatment of choice” [7].

“The differential diagnoses of an anterior abdominal wall mass include acute hematoma, fibrosarcoma, lymphoma, rhabdomyosarcoma, liposarcoma, leiomyosarcoma, neurofibroma, benign fibrous tumor, and primitive neuroectodermaltumor”. [8]

“The National Comprehensive Cancer Network’s Soft Tissue Sarcoma guideline (version 2.2012) [9] recommended history and physical examinations with appropriate imaging such as USG, CT scan, or magnetic resonance imaging every 3–6 months for 2–3 years, and then annually. This recommendation is what we have adopted in the follow-up”.

CONCLUSIONS

Desmoid tumor of the anterior abdominal wall are rare tumors with high rates of recurrence. This case was studied for its unusual occurrence and to know the progress and difficulties in the management and follow-up.

Ethical Approval:

As per international standard or university standard written ethical approval has been collected and preserved by the author(s).

Consent

As per international standard or university standard, patients' written consent has been collected and preserved by the author(s).

REFERENCES

1. Sakorafas GH, Nissotakiss C, Peros G. Abdominal desmoids tumours. *Surg Oncol* 2007;16:131-42. [[Google Scholar](#)]
2. Eastley NC, Hennig IM, Esler CP, Ashford RU. Nationwide trends in the current management of desmoids (aggressive) fibromatosis. *Clin Oncol (R Coll Radiol)* 2015;27:362-8. [[Google Scholar](#)]
3. Caspari R; Olschwang S; Friedl W; Mandl M; Boisson C; Böker T; Augustin A; Kadmon M; Möslein G; Thomas G. Familial adenomatous polyposis: desmoid tumours and lack of ophthalmic lesions (CHRPE) associated with APC mutations beyond codon 1444. *Hum Mol Genet.* 1995; 4(3):337-40.
4. Leon, M.G. Moussa, H.N. Movahedian, M. Viteri, O.A. Longo, M. M. Sibai. B.M. A rapidly growing abdominal mass: desmoid tumour in pregnancy. *AJP Rep*, 5 (2015), pp. e14-e17 <http://dx.doi.org/10.1055/s-0034-1396028> | Medlin
5. Lefevre JH, Parc Y, Kernéis S, Goasguen N, Benis M, Parc R, *et al.* Risk factors for development of desmoid tumours in familial adenomatous polyposis. *Br J Surg* 2008;95:1136-9.
6. Stoeckle E, Coindre JM, Longy M, *et al.* A critical analysis of treatment strategies in desmoid tumors: a review of a series of 106 cases. *EJSO.* 2009;35:129–134. [[PubMed](#)] [[Google Scholar](#)]
7. Spear MA, Jennings LC, Mankin HJ, Spiro IJ, Springfield DS, Gebhardt MC, *et al.* Individualizing management of aggressive fibromatosis. *Int J Radiat Oncol Biol Phys* 1998;40:637-45.
8. Nuyttens JJ, Rust PF, Thomas CR Jr., Turrisi AT 3rd. Surgery versus radiation therapy for patients with aggressive fibromatosis or desmoid tumors: A comparative review of 22 articles. *Cancer* 2000;88:1517-23. [[Google Scholar](#)]
9. National Comprehensive Cancer Network (NCCN) Clinical Practical Guidelines in Oncology: Soft Tissue Sarcoma. Fort Washington, PA: NCCN; 2012. Ver. 2.2012. [Current Version]. (Free registration required). Available from: <http://www.nccn.org/professional/physiangles/pdf/sarcoma.pdf>. [[Google Scholar](#)]

UNDER PEER REVIEW