

The Impact of Point of Care tests in early diagnosis of Ruptured Ectopic Pregnancy in Emergency Department – A Case Report

ABSTRACT

Pregnancy in which the fertilized egg gets implanted in a site other than the uterine cavity is called Ectopic Pregnancy, the most common site of implantation being the fallopian tube. Abdominal or pelvic pain in the first trimester with or without vaginal bleeding with a history of amenorrhea is the commonest presentation. A ruptured ectopic pregnancy is a feared complication that requires speedy diagnosis and management. Here we present a case of 35 years old female presenting with breathing difficulty, easy fatiguability, and giddiness with a history of two months of amenorrhea. On examination, the patient was hemodynamically unstable with a tense and rigid abdomen. Point-of-care urine pregnancy test and point-of-care ultrasound (POCUS) had been essential in making the diagnosis of ruptured ectopic pregnancy in this patient. This case report reiterates the importance of Point-of-care tests such as UPT and POCUS in early diagnosis, resuscitation, and surgical intervention of Ruptured ectopic pregnancy, even in patients with atypical presentation.

INTRODUCTION

Ectopic pregnancy is a term used when a fertilized egg gets implanted at any site other than the uterine endometrium. The most common site of implantation is the fallopian tube which accounts for 95 %, whereas the least common is the abdominal cavity accounting for 1% of cases [1]. Ectopic pregnancies occur in 1.3–2.4% of all pregnancies and are the leading cause of first-trimester maternal pregnancy-related mortality and causing 10% of all pregnancy-related maternal deaths [2,3].

According to the World Health Organization (2007), in developed countries, ectopic pregnancy is the cause of 5% of maternal mortality. Half of the deaths related with ectopic pregnancy are due to hemorrhage and infection [4,5].

The classical triad of symptoms of ectopic pregnancy includes abdominal pain or Pelvic pain, bleeding per vagina, and a history of amenorrhea or positive urinary pregnancy test. The signs and symptoms of an ectopic pregnancy can vary depending on whether it is ruptured or not [6]. Approximately 43-55% of ectopic pregnancies do not present with classical symptoms, and also early symptoms of pregnancy, aren't exclusive to ectopic pregnancy. About 9-30% of women might not present with abdominal pain [7]. Therefore, ectopic pregnancy should be suspected in women of childbearing age with atypical or nonspecific symptoms. With a strong suspicion, ectopic pregnancies can be diagnosed quickly and therefore preventing further complications. Here we report a case that demonstrates how point-of-care ultrasound (POCUS) helped to diagnose a patient with a ruptured ectopic pregnancy with atypical presentation quickly who underwent laparotomy.

CASE REPORT:

A 35 years old female G2P1L1 presented to Emergency Department with complains of breathing difficulty, easy fatiguability and giddiness since five days associated with history of amenorrhoea for two months and spotting ten days prior to admission which lasted for two to three days. Patient did not have any co morbidities. Past obstetric history included a normal

uneventful vaginal delivery twelve years back. There was no history of allergy to any medication and was not on any regular contraceptive. On clinical examination, patient looked very pale and distressed. Her pulse rate was documented 140 beats per minute and blood pressure of 80/60 mm of hg. Her Abdominal examination revealed the abdomen was uniformly distended with diffuse tenderness on superficial and deep palpation and guarding rigidity present. No palpable mass or organomegaly was found. Chest auscultation was normal and auscultation of the heart sounds showed tachycardia without any murmur or added sounds.

The patient's rectal and vaginal examinations didn't show any blood or discharge. A Complete blood count evaluation showed Haemoglobin of 6.2mg/dl.

Patient's point of care Urine Pregnancy Test was POSITIVE and a quick POCUS in the Emergency Department was performed and it showed free fluid in hepatorenal pouch and splenorenal pouch with heterogenous content in Pouch of Douglas, raising the suspicion of Ruptured ectopic pregnancy causing anaemia with hypovolemic shock (Fig1).

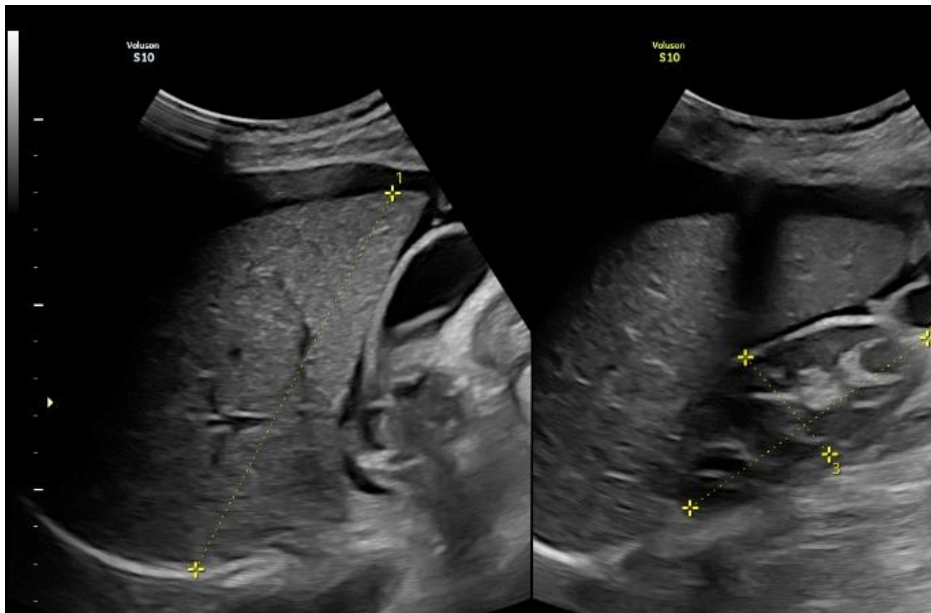


Figure 1 showing free fluid in hepatorenal pouch and splenorenal pouch.

Blood grouping and cross matching was sent and patient started on blood transfusion immediately. OBG team was consulted and formal USG scan was done by Radiologist which showed gestational sac with evidence of an embryo corresponding to nine weeks and two days in right adnexa with non visualisation of ovaries separately. The patient was immediately shifted to Operation Room on Emergency basis for Explorative Laparotomy. In the Operation Room, Intra op findings were:

Right Tubal ectopic pregnancy – Isthmic region, ruptured

Right side ovary bulky 4 cm X 4 cm - ? Corpus luteal cyst rupture

Massive Intra peritoneal haemorrhage – 400gm clots with 750 ml blood in suction, Total 1950ml

Right Salpingo-oophorectomy done, Peritoneal wash given, Haemostats achieved.

Patient was stable at the end of procedure and shifted to post op. The patient had no further complications post operatively and was discharged home after 3 days with outpatient follow up.

Discussion

The most dreaded complication of ectopic pregnancies is ruptured ectopic pregnancy which can lead to hemodynamic instability, and death if left untreated [8]. So, early diagnosis and effective treatment are of utmost importance to reduce morbidity and mortality. But not all patients present with the classical signs and symptoms of ectopic pregnancy. Approximately 43-55% of ectopic pregnancies don't occur with the classic signs and symptoms of abdominal pain, bleeding per vaginum, and amenorrhea. The more varied presentation includes nausea, heavy cramping, fatigue, shoulder pain, breast fullness, and recent dyspareunia. At initial presentation, approximately 20% of patients with ectopic pregnancies are hemodynamically unstable, which is suggestive of ruptured ectopic pregnancy. The differential diagnosis is broad, including both obstetric and non-obstetric causes, therefore, it is necessary to suspect an ectopic pregnancy in women of childbearing age presenting even with nonspecific symptoms. Hence the diagnosis of Ectopic pregnancy is challenging in an emergency department setting.

For any woman of childbearing age presenting to the ED with symptoms that raise suspicion of ectopic pregnancy, a point-of-care urine pregnancy test should be done. Serum β -human chorionic gonadotropin (β -hCG) is a more sensitive test than urinary hCG for confirming pregnancy, and negative serum β -hCG essentially excludes a live pregnancy [9]. Patients with a positive pregnancy test and symptoms suggestive of an ectopic pregnancy should be immediately evaluated with Point-of-care ultrasound to determine the presence or absence of an intrauterine pregnancy and the presence of free fluid in the abdomen. The presence of free intraperitoneal fluid in patients with a positive pregnancy test and empty uterus has 69% specificity and 63% sensitivity for ectopic pregnancy [10].

Thus, Point-of-care ultrasonography is an important tool for Emergency Physicians to use in assessing a patient's risk for potential ectopic pregnancy as early diagnosis can be valuable in reducing morbidity and mortality. Studies have shown that Emergency Department patients with a ruptured ectopic pregnancy who received a POCUS first, had a significantly shorter time to diagnosis, obstetric consultation, and operation theatre (OT) arrival compared with those who received ultrasound performed in Radiology.

In the case described above, the patient has diagnosed with a ruptured ectopic pregnancy by a positive urine pregnancy test and the presence of free fluid in the intraperitoneal cavity. Fortunately, her diagnosis was made quickly, and she was taken to the operation theatre (OT) for definitive care.

It is of utmost importance to rule out ruptured ectopic pregnancy because it is life-threatening to the mother if the proper diagnosis and management are delayed.

Conclusion

In women of childbearing age, ectopic pregnancy must be considered due to its varied presentation. Point-of-care Ultrasound plays a critical role in the work-up and diagnosis of ectopic pregnancy in the Emergency Department. In this case report, we try to bring to light the importance of using bedside tests like a urine pregnancy test and POCUS in the Emergency Department as it enables the clinicians to treat patients faster, more accurately, and in a non-invasive manner especially ruptured ectopic pregnancy.

Conflict of interest

No conflict of interest was declared by the authors.

References

1. Poole A, Haas D, Magann EF. Early abdominal ectopic pregnancies: a systematic review of the literature. *Gynecol Obstet Invest.* 2012;74(4):249–60.
2. Taran F, Kagan K, Hübner M, et al. The diagnosis and treatment of ectopic pregnancy. *DtschArztebl Int.* 2015;112(41):693-703.
3. Corrigan KJ, Kowalzyk DR. Ectopic ovarian pregnancy in a second-trimester patient. *Am J Emerg Med.* 2007;25(9):185.e3-4.
4. Clark SL, Belfort MA, Dildy GA, Herbst MA, Meyers JA, Hankins GD. Maternal death in the 21st century: causes, prevention, and relationship to cesarean delivery. *Am J Obstet Gynecol.* 2008;199(36):e1–5. doi: 10.1016/j.ajog.2008.03.007. discussion 91-2 e7-11.
5. Lang CT, King JC. Maternal mortality in the United States. *Best Pract Res Clin Obstet Gynaecol.* 2008;22:517–31. doi: 10.1016/j.bpobgyn.2007.10.004.
6. Ranji GG, Usha Rani G, Varshini S. Ectopic Pregnancy: Risk Factors, Clinical Presentation and Management. *J Obstet Gynaecol India.* 2018 Dec;68(6):487-492. doi: 10.1007/s13224-017-1075-3. Epub 2017 Nov 18. PMID: 30416277; PMCID: PMC6207546.
7. Aboud E. A 5 year review of ectopic pregnancy. *ClinExpObstetGynecol* 1997; 24: 127-9. PMID: 9478294.
8. Hendriks E, Rosenberg R, Prine L. Ectopic Pregnancy: Diagnosis and Management. *Am Fam Physician.* 2020 May 15;101(10):599-606. PMID: 32412215
9. Levine D. Ectopic pregnancy. *Radiology.* 2007 Nov;245(2):385-97. doi: 10.1148/radiol.2452061031. PMID: 17940301.

10.Kaakaji Y, Nghiem HV, Nodell C, Winter TC. Sonography of obstetric and gynecologic emergencies: Part I, Obstetric emergencies. *AJR Am J Roentgenol* 2000;174:641-649.