

Fannyhessea vaginae (Atopobium vaginae) bacteraemia in puerperal fever: A Case report and review

Abstract

Fannyhessea vaginae, formerly *Atopobium vaginae*, is a slow-growing anaerobic bacterium that frequently causes bacterial vaginosis and, rarely, bacteraemia and invasive infection. Published cases of bacteraemia are associated with childbirth or gynecological procedures that can lead to invasive infections such as endocarditis, peritonitis, and arthritis. In this study we present the case of a woman with puerperal fever caused by this microorganism and a brief review of other published cases.

Keywords: Fannyhessea vaginae, bacteraemia, gynecological procedures, hypogastrium

Introduction

Bacterial vaginosis (BV) is one of the most frequent female lower genital tract infections, not only in pregnancy but throughout the reproductive life. Studies from Europe and the USA have found prevalence between 4.9% and 36.0% [13]. Although the pathogenesis of BV remains unclear, alternatively, it represents a dysbiosis, an imbalance of the vaginal microbiota rather than an infection. BV is characterized by a shift from the predominance of lactobacilli in the vaginal microbiota to a higher concentration of other organisms [14]. The severity of the consequences of such sequelae asks for an adequate treatment of bacterial vaginosis. Currently the preferred antibiotic treatment regimen consists of clindamycin or metronidazole (oral or intravaginal). During the last decade, the interest for bacterial vaginosis increased because of reports of adverse sequelae of this disorder, such as preterm birth [15,16].

Clinical case

A 25-year-old woman with a 38-week pregnancy was admitted to our hospital due to a ruptured amniotic sac that preceded delivery by 48 hours. A few hours after it, she began with fever of 38.6°C and pain in the hypogastrium. The patient had a history of twin births and asthma on treatment with salbutamol, and presented cough attributable to an influenza A infection diagnosed by PCR two weeks earlier treated with oseltamivir. Screening for *S. agalactiae* was negative. The patient did not present voiding syndrome or breast focality. On examination, the abdomen was soft, painful on deep palpation in the hypogastrium without signs of peritoneal irritation. Closed cervix, no smelly lochia, no bleeding. On ultrasound, the puerperal uterus was normal with a 15mm endometrium.

Blood cultures were sent to the laboratory. After 31 hours of incubation, the auto-analyzer indicated positive growth exclusively in the anaerobic vials. Gram stain revealed Gram-positive cocci in chains (Figure 1). An unsuccessful attempt to identify it by mass spectrophotometry (MALDI-TOF) directly from the blood culture vial was made. However, it was transferred from the vial to blood agar plates in which,

after 42 hours of incubation in anaerobiosis, small white colonies grown (Figure 2). Colonies were identified as *Atopobium vaginae* by mass spectrophotometry with a score of 1,8. Three independent identification attempts were performed with consistent results. Antibiogram was carried out by epsilometry (E-test) with the following results: Metronidazole R (Figure 3), Penicillin S, Moxifloxacin S, Amoxicillin-clavulanate R.

Additionally, the patient presented isolates of *Prevotella melaninogenica* in endometrial aspirate and *Escherichia coli* in urine culture.

The final diagnosis was puerperal fever due to probable flora of vaginosis. Treatment was started with Ceftriaxone IV 2g/24h + Metronidazole IV 500mg/8h + Doxycycline IV 100mg/12h. Upon discharge, Cefixime 400 mg orally every 24 hours + Metronidazole 500 mg orally every 8 hours for a further 12 days was prescribed.

Discussion

Fannyhessea vaginae is a rare cause of bacteraemia and invasive disease. Although this fastidious, anaerobic bacterium is a common cause of bacterial vaginosis [1]. The few published cases of bacteraemia are associated with childbirth or gynecological interventions [2]. It can also cause invasive infections such as endocarditis, peritonitis, and arthritis [3].

Atopobium vaginae was defined as a new species in 1999 [4]. Earlier, in 1992, the genus *Atopobium* had been proposed to accommodate the species *Atopobium rimae* (formerly *Lactobacillus rimae*), *Atopobium parvulum* (formerly *Streptococcus parvulus*), and *Atopobium minutum* (formerly *Lactobacillus minutum*) [5]. In 2018 it was classified in the new genus *Fannyhessea* [6]. It currently belongs to the class Choriobacteria, order choriobacteriales, family Atopobiaceae.

Microscopically, they are small and elongated Gram-positive cocci alone or in chains. Initially considered saprophytic, it has been implicated in bacterial vaginosis, which in turn is associated with preterm delivery [7]. More rarely, it has been isolated in association with tubo-ovarian abscesses after transvaginal retrieval of oocytes and uterine endometritis [8].

Bacteraemia due to this germ is infrequent and can appear after chorioamnionitis. To date, only 5 cases have been described in the literature [9-11], although intrauterine infection by microorganisms that cause vaginosis is well known and can lead to maternal sepsis. Other species of *Atopobium* that have produced invasive pathology are *A. detroiti* and *A. rimae*.

Regarding sensitivity, *F. vaginae* is an anaerobe traditionally considered resistant to metronidazole and sensitive to clindamycin, which is consistent with our results. However, it has recently been shown that it is not intrinsically resistant to metronidazole, showing variable sensitivity between 2 and >256 mg/L [12].

In conclusion, we suggest that *F. vaginae* may be capable of causing maternal bacteraemia during the puerperium. In this case, the microorganism passed into the blood after chorioamnionitis caused by multiple flora from the vagina and commonly associated with bacterial vaginosis. Because they are slow-growing microorganisms, it is not easy to detect them using automated blood culture systems, which could be causing a situation of under-diagnosis and an underestimation of their clinical role.

REF
ERE

NCI

AS

1. Onderdonk AB, Delaney ML, Fichorova RN (2016) The human microbiome during bacterial vaginosis. *Clin Microbiol Rev.* <https://doi.org/10.1128/CMR.00075-15>
2. Chan JF, Lau SK, Curreem SO et al (2012) First report of spontaneous intrapartum *Atopobium vaginae* bacteremia. *J Clin Microbiol.* <https://doi.org/10.1128/JCM.00212-12>
3. Massa Bo, De Laere E, Raes R, Vervaeke S, Van Hoecke F (2022) First report of a prosthetic joint infection with *Fannyhessea vaginae*. *EJCMID* <https://doi.org/10.1007/s10096-022-04461-0>
4. Rodriguez, J. M., Collins M, Sjoden B, and Falsen E.(1999).Characterization of a novel *Atopobium* isolate from the human vagina: description of *Atopobium vaginae* sp. nov. *Int. J. Syst. Bacteriol.* 49:1573–1576.
5. Collins MD, Wallbanks S. Comparative sequence analyses of the 16S rRNA genes of *Lactobacillus minutus*, *Lactobacillus rimae* and *Streptococcus parvulus*: proposal for the creation of a new genus *Atopobium*. *FEMS Microbiol Lett.* 10.1016/0378-1097(92)90435-q. PMID: 1382033.
6. Nouioui I, Carro L, García-López M, Meier-Kolthof JP, Woyke T, Kyrpides NC, Pukall R, Klenk HP, Goodfellow M, Göker M (2018) Genome-based taxonomic classification of the phylum Actinobacteria. *Front Microbiol.* <https://doi.org/10.3389/fmicb.2018.0200>
7. Bretelle F, Rozenberg P, Pascal A, Favre R, Bohec C, Loundou A, Senat MV, Aissi G, Lesavre N, Brunet J, Heckenroth H, Luton D, Raoult D, Fenollar F; Groupe de Recherche en Obstetrique Gynecologie. High *Atopobium vaginae* and *Gardnerella vaginalis* vaginal loads are associated with preterm birth. *Clin Infect Dis.* 2015 Mar 15;60(6):860-7. doi: 10.1093/cid/ciu966. Epub 2014 Dec 1. PMID: 2545259
8. Yamagishi Y, Mikamo H, Tanaka K, Watanabe K. A case of uterine endometritis caused by *Atopobium vaginae*. *J Infect Chemother.* 2011 Feb;17(1):119-21. doi: 10.1007/s10156-010-0100-6. Epub 2010 Aug 14. PMID: 20706763.
9. Dauby N, Martiny D, Busson L, Cogan A, Meghraoui A, Argudín MA, Nonhof C, Hallin M, Konopnicki D (2019) *Atopobium vaginae* intrapartum bacteremia: a case report with a literature review. *Anaerobe.*
10. Solobodanka BS, Ljubinka IN et al (2018) Transient bacteremia caused by *Atopobium vaginae* after caesarean delivery: case report. *Hosp Pharm.* <https://doi.org/10.5937/hpimj1802654S>
11. Jacqmin H, deMunter P, Verhaegen J, Lewi L (2018) *Atopobium vaginae* bacteremia associated with a subchorionicematoma. *Clin Biol N*
12. Knoester M, Lashley LE, Wessels E, Oepkes D, Kuijper EJ (2011) First report of *Atopobium*
- 13 Polatti F. Bacterial vaginosis, *Atopobium vaginae* and nifuratel. *Current clinical pharmacology.* 2012 Feb 1;7(1):36-40.
14. Rosenfeld WD, Clark J. Vulvovaginitis and cervicitis. *Pediatric Clinics of North America.* 1989 Jun 1;36(3):489-511.
15. Hay P: Recurrent bacterial vaginosis. *Curr Infect Dis Rep.* 2000, 2: 506-512.
16. Larsson PG, Forsum U: Bacterial vaginosis, a disturbed bacterial flora and treatment enigma. *APMIS.* 2005, 113: 305-316. 10.1111/j.1600-0463.2005.apm_113501.x

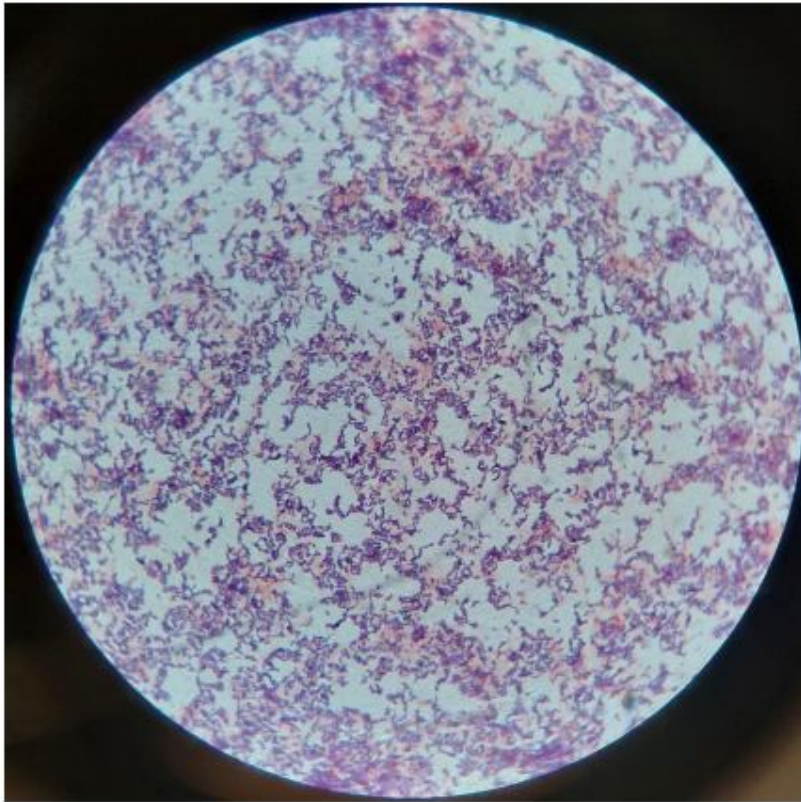


Figure 1. Gram staining of *F. vaginae* direct from the blood culture vial.



Figure 2. Detail of *F. vaginae* colony in Columbia blood-agar.

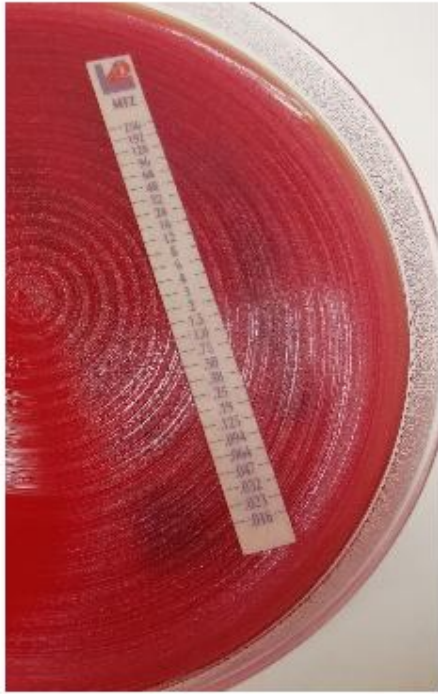


Figure 3. Epsilometry test of *F. vaginae* growing in Mueller-Hinton Agar supplemented with blood. The microorganism is able to grow all along the stripe containing metronidazole (resistant, CMI >256)

UNDER PEER REVIEW

UNDER PEER REVIEW