

HAEMORRHAGIC STROKE COMPLICATING SYSTEMIC ENVENOMATION IN SNAKE BITE: A CASE REPORT AND LITERATURE REVIEW.

ABSTRACT

Introduction: Snakebite is a neglected tropical public health problem that is common in Nigeria. The occurrence of haemorrhagic stroke following snakebite envenomation is a rare medical emergency.

Aim: To describe the neurological complications that occurred after snakebite envenomation.

Methodology: This is a hospital-based case report of a 17-year woman who presented at the Emergency unit of Benue State University Teaching Hospital Makurdi Benue State Nigeria 18 days after snake bite with 10 days of progressive loss of consciousness and associated difficulty in opening the right eye, weakness of the left hemi-body, weeping spells and difficulty in swallowing with no background cardiovascular risk factor. She had been managed by a traditional medicine healer immediately after the snakebite.

Result: At presentation she had GCS of 7/15, restless, and mildly pale with weeping spell and a healed scar on her right leg. Other neurological examination revealed right ptosis, right oculomotor nerve palsy, upper motor neuron type of left facial nerve palsy (multiple cranial nerve palsies), aphasia and crossed hemiplegia indicating Weber's syndrome (midbrain stroke syndrome). She made good clinical recovery of her neurologic deficits.

Conclusion: Our report highlights the need to suspect and exclude haemorrhagic stroke in victims presenting with loss of consciousness and lateralizing signs using brain CT scan. Public enlightenment is needed to enhance early presentation following snakebite

Key words: Haemorrhagic Stroke, snakebite, neurological complications, Nigeria

Introduction:

Snakes are cold blooded reptiles that live on the land, in the sea, forests, lakes, and in deserts.

Snake bite injuries could be simple like a puncture wound at the site or could be severe complicated illness including neurological and haematological disorders and even death.

Venomous bites could be asymptomatic implying no-toxic bite or symptomatic which could manifest immediately or after a long-time interval that may reach up to 36 hour or even more after exposure. The manifestations can be misleading. A victim may have no initial significant symptom, and then suddenly after hours or even days manifest with varying symptoms like breathing difficulty with shock ¹

Toxic snake venoms can be vasculo-toxic, neurotoxic or myotoxic. The vasculo-toxic bite (mostly by viperidae family of snakes) causes manifestations ranging from local pain and swelling at the site of bite, to coagulopathy, bleeding and cardiac arrest. Neurotoxic snakes (e.g. Cobra) produce descending cranial nerve paralysis manifesting as ptosis, dysphonia, dysphagia, dysarthria, difficult breathing up to respiratory failure and death. The myotoxic snakes (mostly the hydrophidae) produce tissue damage, muscles swelling and pain, muscles destruction and myoglobinuria leading finally to renal failure. ² Venomous snakes can cause stroke due to either their neurotoxic or hemotoxic enzymes. ³ Ischemic strokes account for 77.1% of the cases while primary intracerebral hemorrhage (ICH) account for 20.5% ⁴ ICH after snake bite is associated with high mortality. ⁵

Even though snake bites remain a major medical problem in West Africa, hemorrhagic stroke following snakebite has emerged as a rare secondary condition. ⁶ Hemorrhagic stroke is a complication that may be more frequent in patients with pre-existing risk factors, such as hypertension, diabetes mellitus, smoking, and cardiovascular diseases. ⁷ Although snake bite is rampant in Nigeria, however occurrence of haemorrhagic stroke following snakebite is very uncommon necessitating this case report. The objective of this study was to describe the neurological complications that occurred following snakebite and systemic envenomation in a tertiary hospital in Makurdi Benue state, north central Nigeria.

Case Report:

A patient 18-year-old right-handed Tiv woman who is a farmer and presented to the Accident and Emergency unit of Benue State University Teaching Hospital, Makurdi on 18/07/2022 with 18 days history of snake bite on her right leg. It was a single bite but they could not identify the snake. There was subsequent pain and swelling of the entire leg with spontaneous bleeding from puncture site. She had no history of vomiting, abdominal pain, passage of melena, haematochezia, hematemesis, passage of coke coloured urine, reduction in urine volume and frequency or orofacial bleed and initially there was no symptom suggestive of neurologic deficit. They sought treatment with a traditional healer who made incisions and applied local concoctions to the wound.

About 10 days later, she developed progressive loss of consciousness with associated difficulty in opening the right eye, weakness of the left hemi-body, weeping spells and difficulty in swallowing. There was no history of fever, vomiting or seizures. She had no premorbid cardiovascular risk factors like hypertension, diabetes, cigarette smoking or alcohol use. Patient was admitted at a peripheral hospital where 6 units of anti-snake venom, 2 units of blood and antibiotics was administered, however patient failed to improve necessitating referral to our facility.

Physical examination revealed a young woman that was restless with weeping spells, pale but afebrile with approximately 1.5cm healed scar at the puncture site on the medial aspect of the leg below her right knee. The neurological examination showed Glasgow coma score (GCS) of 7/15, right sided ptosis with dilated pupil (anisocoria) which indicates right oculomotor nerve palsy, upper motor neuron type left facial nerve palsy and aphasia. Motor examination showed left

flaccid hemiplegia with Medical Research Council (MRC) score of 0/5 in both left upper and lower limbs with absent plantar reflex. National Institute of health Stroke severity (NIHSS) Score was 25/42 which indicates a severe stroke. Cardiovascular examination was essentially normal with pulse rate of 92 beats per minute, blood pressure was 130/80 mmHg with normal first and second heart sounds. Her respiratory examination was unremarkable with respiratory rate of 20 cycles per minute; oxygen saturation was 98% in room air while the lung fields were clear with vesicular breath sounds. Abdominal examination showed no significant finding.

Results of the investigations showed that her bedside 20-minute whole blood clotting test (20 WBCT) and other coagulation tests were essentially normal. She had moderate anaemia with a packed cell volume of 25% with normal range of full blood count and total platelet count. Her biochemical tests showed deranged aspartate aminotransferase and alanine aminotransferase which were 6 times and 7 times upper limit of normal respectively while the total protein, albumin, bilirubin and electrolyte, urea and creatinine were all unremarkable. The brain computed tomography scan showed Similar but less lesions were noted on the left (Figures below). The diagnosis of acute right hemispheric primary intracerebral hemorrhage complicating systemic envenomation in snake bite was made. She received 1 unit of blood and was commenced on intravenous (IV) ceftriaxone, normal saline and decompressed with 20% mannitol alongside with frusemide. Nasogastric tube was passed for her feeding as well as tablet haloperidol 10mg twice daily, benzhexol 5mg twice daily. She was also commenced on physiotherapy. Patient made good clinical recovery and was discharged after 34 days on admission conscious with residual expressive aphasia with MRC power of 2/5 in the left upper limb and 4/5 in the lower limb.

DISCUSSION

According to WHO, snake bite is a neglected public health problem in many tropical and subtropical countries with about 5.4 million snake bites occurring each year, resulting in 1.8 to 2.7 million cases of envenomation.⁸ There is high rate of mortality and morbidity associated like amputations and other permanent disabilities each year from it.⁸ The incidence of snake bite in Nigeria has been reported as 496/100000 population per year.⁹ Snake bite as a cause of stroke is not common but when it occurs it usually indicates poor prognosis especially haemorrhagic type.¹⁰

The index case was a young lady who was bitten by a snake in the month of July as this agrees with the peak period of snake bite reported by previous researchers.¹⁰ She is a farmer with no previous medical history who resides in a rural area working in her farm. This case corroborated with findings in previous studies on snake bite which showed that most victims of snake bites are young active individuals usually less than 65 years⁶ with no sex preference¹¹ who are mostly agro-pastoralists, living in rural areas with little or no previous cardiovascular risk factors⁴

The patient in this study had a bite on her right lower limb below the knee while working in the farm though could not identify the specie of the snake. This was in agreement with previous studies in which people engaged in farming, hunting, fishing and other rural activities are at highest risk, mostly bitten on their limbs during work.¹² Similarly, the type of snake was unknown to the patient or her caregivers in this case; as at least 75% of snakebite victims present to hospital with an unknown bite or with a bite from an unidentified species¹³

Esiéné, *et al.* in Cameroon, reported a case of a severe vasculo-toxic snake envenomation in a female farmer that resulted in cardiogenic shock, acute kidney injury and gangrene of the entire right upper limb; the bitten limb. There was delay in taking the patient to the Emergency Unit,

septic shock supervened that led to death ¹⁴. The majority of our patients had consulted a traditional healer, as in the study of Somé in the southwest of Burkina Faso in 2002.¹⁵ Delayed treatment can be fatal, especially beyond six hours after the bite.¹⁶ This is similar to the patient in this study who was first attended to by a traditional healer who made incisions and applied local concoctions to the wound thus delaying early commencement of appropriate management like anti-snake venom (ASV) with consequent neurological complication.¹⁵ Our patient received ASV about 10 days after the snakebite. It has been reported that one of the factors that contribute to the predisposition for seeking help through traditional medicine in many regions, and particularly sub-Saharan Africa is the lack of access to safe and effective anti-snake venom treatment.¹ However poverty, ignorance and poor health seeking behavior, could have been responsible for the delayed presentation in the index case.

The neurological deficits in this patient include ptosis, right oculomotor nerve palsy; upper motor neuron type of left facial nerve palsy (multiple cranial nerve palsies), aphasia and crossed hemiplegia indicating Weber's syndrome (midbrain stroke syndrome). A prospective study in Sri Lanka had reported the frequency of neurological disorder as follows; ptosis in (85.7%) followed by ophthalmoplegia (75.0%), limb weakness (26.8%), respiratory failure (17.9%), palatal weakness (10.7%), neck muscle weakness (7.1%), and delayed sensory neuropathy (1.8%).¹⁷ In their cohort neurological symptoms were experienced usually within 6 hours after the snakebite while ours occurred about 10 days later.

Neurological manifestations of snakebite envenomation have been classified as direct neurotoxicity that usually manifest acutely like neuromuscular paralysis and indirect neurotoxicity such as cerebral haemorrhage and infarction which occurs due to coagulopathy and myotoxicity.¹⁸ Although haemorrhagic stroke is uncommon in snakebite envenomation but most

cases reported have been linked with viper bite attributable to the snake-venom metalloproteinases (SVMPs) and haemotoxins (anticoagulants) in their venom.¹⁹ Persons bitten by vipers are likely to suffer from a severe cerebral hemorrhage due to vascular endothelial damage and coagulation disorder. The proposed mechanism is due to proteolytic destruction of the basal membrane and extracellular matrix around the capillary and vessels.²⁰

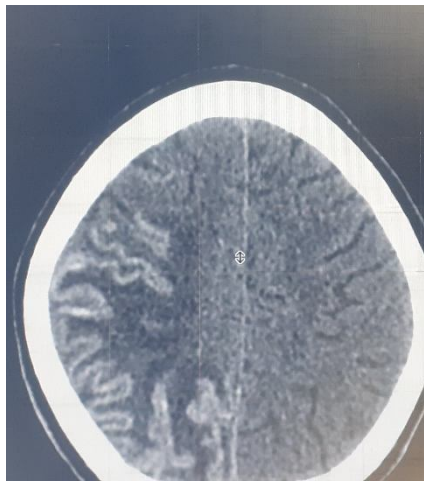
Regarding the bleed location on CT scan in patients with haemorrhagic stroke from snakebite envenomation, previous reports have shown varying location. The study from Burkina Fasso reported 3 cases of which one was in the basal ganglia affecting the internal capsule and lenticular nuclei while the second case involved bilateral frontal and cerebellar regions and lastly a temporal haemorrhage.⁶ A recent study in Morocco had shown a parietal cortex bleed¹¹ while our study revealed bilateral gyriform hyperdensities predominantly on the right cerebral hemisphere involving the frontal, parietal, occipital and temporal lobes and extending above the level of the lateral ventricles associated with perilesional oedema.

Conclusion: Snakebite envenomation is common in our environment but occurrence of haemorrhagic stroke following it is rare. Our report highlights the need to suspect and exclude haemorrhagic stroke in victims presenting with loss of consciousness and lateralizing signs using brain CT scan. Public enlightenment is needed to enhance early presentation following snakebite.

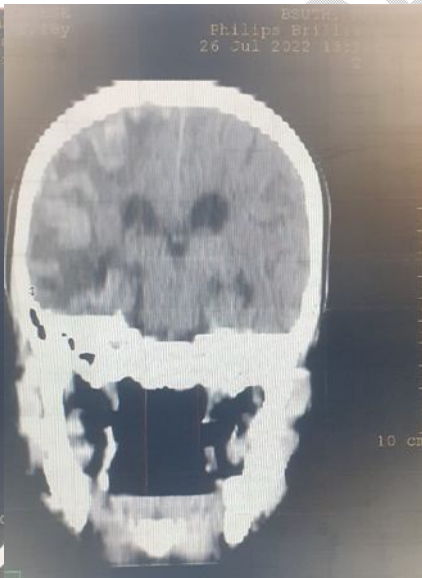
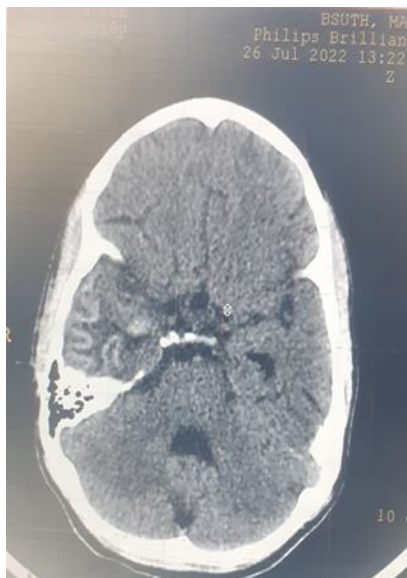
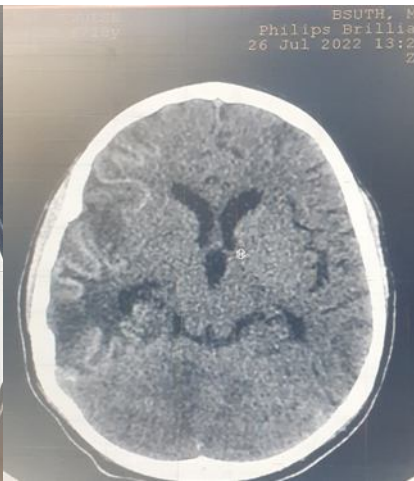Competing interest: The authors state there was no competing of interest in this case report.

Fig.1: NCCT showing extensive gyriform hyperdensities predominantly on the right cerebral hemisphere involving the frontal, parietal, occipital and temporal lobes and extending above the level of the lateral ventricles. There is associated marked perilesional edema but no midline shift.

A.



B.



C.

D.

References

1. Gutiérrez JM, Calvete JJ, Habib AG, Harrison RA, Williams DJ, et al. Snakebite envenoming. *Nat Rev Dis Primers*.2017; 3: 17063.
2. Domanski K, Kleinschmidt KC, Greene S, Ruha AM, Berbata V, et al. Cottonmouth snake bites reported to the Toxic North American snakebite registry 2013-2017. *Clin Toxicol (Phila)* 2019;13: 1-5.

3. Warrell DA. Animal toxins. In: Cook GC, ed. *Manson's tropical diseases*. 20th ed. London: Saunders; 1996.
4. Al-Sadawi M, Mohamadpour M, Zhyvotovska A, et al. Cerebrovascular Accident and Snake Envenomation: A Scoping Study. *Int J Clin Res Trials*. 2019; 4:133.
5. Tibballs J, Henning RD, Sutherland SK, Kerr AR. Fatal cerebral haemorrhage after tiger snake (*Notechis scutatus*) envenomation. *Med J* 1991;154(4):275–276.
6. Alfred AD, Apoline S, Alassane D, Ismael D, Julie MA, Christian N, and Jean K. Hemorrhagic stroke following snake bite in Burkina Faso (West Africa). A case series. *Trop Dis Travel Med Vaccines*. 2021; 7: 25.
7. de Oliveira Pardal PP, Pinheiro AC, Silva CT, Santos PR, Gadelha MA. Hemorrhagic stroke in children caused by *Bothrops marajoensis* envenoming: a case report. *J Venom Anim Toxins Incl Trop Dis*. 2015;14:21:53
8. WHO. Snakebite Envenoming. 17th May 2021. In <https://www.who.int/news-room/fact-sheets/detail/snakebite-envenoming>. Accessed on 13/08/22
9. Habib AG, Gebi UI, GC. Snake bite in Nigeria. *Afr J Med Med Sci* 2001; 30:171-8
10. Ansoumane HK, Mhaili J, Boutakioute B, et al. Hemorrhagic Stroke Revealing a Snake Bite: A Case Report. *Cureus* 2022;14(1): 20935.
11. Kumako VK, N'Timon B, Apetse K, et al. Two cases of hemorrhagic stroke following Snake bite in Kara teaching Hospital in a Semi Rural Area in Togo. *Sci J Neurol Neurosurg*. 2018;4(1):001–004.
12. Harrison RA, Hargreaves A, Wagstaff SC, Faragher B, Laloo DG. Snake envenoming: a 489 disease of poverty. *PLoS Negl Trop Dis*. 2009;3(12):569
13. Peter G, Georgy PI. A life-threatening scratch on little toe- at most clinical suspicion the essential key in management of snake bite. *Asian Pac J Trop Biomed*. 2012;2(2):163–165.
14. Esiéné A, Etoundi PO, Tochie JN, Metogo AJM, Minkande JZ (2019) Severe Viperidae envenomation complicated by a state of shock, acute kidney injury, and gangrene presenting late at the emergency department: a case report. *BMC Emerg Med* 19: 26.
15. Somé N, Poda JN, Guissou IP. Epidemiology and management of snakebites in the medical district of Dano, province of Ioba (Burkina Faso) from 1981 to 2000. *Bull Soc Pathol Exot*. 2002; 95:163
16. Sharma SK, Koirala S, Dahal G, et al. Clinico-epidemiological features of snakebite: a study from eastern Nepal. *Trop Doct*. 2004; 34:20–22.
17. Seneviratne U, Dissanayake S. Neurological manifestations of snake bite in Sri Lanka. *J Postgrad Med*. 2002;48(4):275-8; discussion 278-9.
18. Ranawaka UK, Laloo DG, de Silva HJ. Neurotoxicity in snakebite--the limits of our knowledge. *PLoS Negl Trop Dis*. 2013;7(10):e2302
19. Waiddyanatha S., Silva A., Siribaddana S., Isbister G.K. Long-term Effects of Snake Envenoming. *Toxins*. 2019; 11:193.
20. Gutierrez J.M., Escalante T., Rucavado A., Herrera C. Hemorrhage Caused by Snake Venom Metalloproteinases: A Journey of Discovery and Understanding. *Toxins*. 2016; 8:93.