

Case report

A CASE OF BILATERAL DEEP VEIN THROMBOSIS WITH BILATERAL PULMONARY EMBOLISM AFTER MILD COVID INFECTION

ABSTRACT

AIM: Bilateral thromboembolic manifestations in mild COVID infection.

CASE PRESENTATION: 64-year-old male with no known comorbidities presented to OPD with pain and swelling of the right lower limb, and chest pain. He was found to have bilateral lower limb deep vein thrombosis in venous Doppler and bilateral pulmonary embolism in CT pulmonary angiogram. He improved with medical management.

CONCLUSION: COVID-COVID-19 infection is associated with thromboembolic complications. High-A high index of suspicion of thromboembolic manifestations secondary to COVID infection even in mild cases should be considered after ruling out other possibilities.

KEYWORDS: COVID infection, thromboembolic manifestations.

1. INTRODUCTION

The coronavirus SARS CoV-2 causing COVID-COVID-19 has led to an unprecedented global health crisis. It presents as sore throat, fever, and cough to severe forms like breathlessness and desaturation resulting in multisystem failure and death¹. This virus can trigger an inflammatory response, especially in vascular endothelium, and increase the risk of thrombosis. Most-The most common thrombotic complications are venous thromboembolism manifesting as deep vein thrombosis and pulmonary embolism. Disseminated intravascular coagulation was also reported in a few cases². Hence prophylactic use of anticoagulants in COVID patients can be done, especially in the elderly, with comorbid illnesses and moderate to severe COVID pneumonia.

2. CASE PRESENTATION

A 64-year-year-old gentleman, with no known comorbidities, was diagnosed with mild COVID infection (mild disease as per Ministry of Health guidelines—uncomplicated upper respiratory tract infections without shortness of breath or hypoxia). He came to the Internal medicine outpatient department, 8 days later, with complaints of right calf pain and swelling which was exacerbated on-by walking. He also had complaints of mild chest pain in the left infraaxillary area, acute in onset, catching type of pain, non-radiating, exacerbated on-by taking deep breaths. He had no history of breathlessness, fever, or trauma. On examination, he was moderately built, his vitals were pulse rate of 100/min, regular, blood pressure of 120/70mmHg, respiratory rate of 20/min, and saturation of 96% in room air. Respiratory system examination revealed normal vesicular breath sounds with diminished breath sounds and crepitations in the left infra-axillary region. Local examination showed swelling of the right calf, with tenderness and intact peripheral pulses. Initial blood investigations are given below in table 1. X-X-Ray Chest taken showed left lower zone non-homogenous opacity. Venous ultrasound doppler of bilateral lower limb veins revealed deep vein thrombosis in right calf veins and also in left calf veins. He was started on Enoxaparin and other supportive medications. Computed-A computed tomography pulmonary angiogram (CTPA) was done which showed a filling defect in the right middle

lobe and descending sub segmental pulmonary arterial branches and left descending pulmonary artery segmental and subsegmental branches-suggestive of pulmonary thromboembolism (figure 1). Echodone was normal. As a part of the evaluation of deep vein thrombosis, Factor V ~~Leiden-Leiden~~ mutation, prothrombin gene mutation, and anti-Beta-2 glycoprotein IgG and IgM and anticardiolipin IgM and IgG were sent. All of them were negative. His lab parameters were serially monitored and ~~it~~ they showed down trending inflammatory markers. He improved both clinically and ~~lab-lab~~-wise with the above line of management and hence was discharged.

He was reviewed after 14 days on an Outpatient basis and his symptoms had resolved. Bilateral lower limb venous doppler taken after 4 months showed no evidence of deep vein thrombosis. He was given rivaroxaban for 6 months and stopped. He was followed up for another month and he remained asymptomatic. He was advised to review in case of any issues.

3. DISCUSSION

Though the lungs are the target organs for ~~COVID-COVID~~-19 infection, it also causes inflammatory changes in the endothelium resulting in the release of cytokines and other inflammatory mediators which lead to various complications resulting in coagulopathy and multiorgan dysfunction syndrome. The inflammatory response produced by COVID causes activation of neutrophils and macrocytes and they produce neutrophil extracellular traps (NETs) causing platelet activation and adhesion, resulting in thrombosis³. D dimer is formed from the degradation of fibrinogen to fibrin. This D dimer in turn causes platelet activation and results in thrombosis. A study from Wuhan found that 26% of the patients admitted ~~in-to~~ICU had elevated D dimer⁴. This increase in D dimer was found to be proportional to the rise in inflammatory markers such as C-reactive protein. This results in various thromboembolic manifestations, the most common being deep vein thrombosis and pulmonary embolism. In a meta-analysis published in Lancet, the incidence of deep vein thrombosis and pulmonary embolism was 20% and 13% and their respective counterparts in ICU were 28% and 19%⁵. Hence US guidelines for COVID had advised ~~for~~ prophylactic anticoagulation admitted in ward or ICU. Lin et al states that a rise in inflammatory markers from 7-14 days of the disease warrants therapeutic anticoagulation⁶.

In this case, the patient had presented with bilateral deep vein thrombosis and bilateral pulmonary embolism in post COVID period, though the severity of COVID infection was mild. On retrospective analysis, the patient only had a mild COVID infection and his D dimer at the time of COVID admission was normal ~~and~~ hence he was not prescribed ~~with~~ anticoagulants on discharge. When he was readmitted, he had elevated D dimer secondary to pulmonary embolism and deep vein thrombosis.

4. CONCLUSION

~~COVID-COVID~~-19 infection is notorious ~~in-for~~ causing various complications secondary to hyperinflammation and coagulopathy, most commonly deep vein thrombosis and pulmonary embolism. Hence adequate anticoagulation should be prescribed, in prophylactic or therapeutic dosage based on severity, during and post COVID infection to prevent the incidence of thrombotic complications.

CONSENT

Written informed consent was obtained from the patient and patient's bystander for publication of this case report.

ETHICAL APPROVAL

Ethics committee approval was obtained from the Amrita institute of medical science and research centre.

REFERENCES:

1. Luis F Garcia, Front. Immunol., 16 June 2020 Sec. Viral Immunology, <https://doi.org/10.3389/fimmu.2020.01441>, Immune response, Inflammation and the clinical spectrum of COVID-19
2. Hanny Al-Samkari , Rebecca S Karp Leaf, Walter H Dzik, Jonathan C T Carlson, Annemarie E Fogerty, Anem Waheed. COVID-19 and coagulation: bleeding and thrombotic manifestations of SARS-CoV-2 infection. 2020 Jul 23;136(4):489-500. doi: 10.1182/blood.2020006520.
3. Richard C. Becker, COVID-19 update: Covid-19-associated coagulopathy. 2020 May 15. doi: 10.1007/s11239-020-02134-3
4. Wang D, Hu B, Hu C, et al. Clinical Characteristics of 138 Hospitalized Patients With 2019 Novel Coronavirus-Infected Pneumonia in Wuhan, China. JAMA. 2020;323(11):1061-1069. doi:10.1001/jama.2020.1585
5. Mahmoud B. Malas¹, Isaac N. Naazie¹, Nadin Elsayed, Asma Mathlouthi, Rebecca Marmor, Bryan Clary. Thromboembolism risk of COVID-19 is high and associated with a higher risk of mortality: A systematic review and meta-analysis. DOI: 10.1016/j.eclinm.2020.100639, Epub 2020 Nov 20
6. Lin L, Lu L, Cao W, Li T. Hypothesis for potential pathogenesis of SARS-CoV-2 infection—a review of immune changes in patients with viral pneumonia. *Emerging Microbes & Infections*. 2020;9(1):727–732. doi: 10.1080/22221751.2020.1746199.

Table 1: Initial blood investigations

TOTAL COUNT	NEUTROPHILS	PLATELET	C-REACTIVE PROTEIN	ASPARTATE TRANSAMINASE(AST)	ALANINE TRANSAMINASE (ALT)	D-DIMER
11,000/microL	67%	348ku/ml	144mg/dl	37mg/dl	55mg/dl	2.91mcg/ml

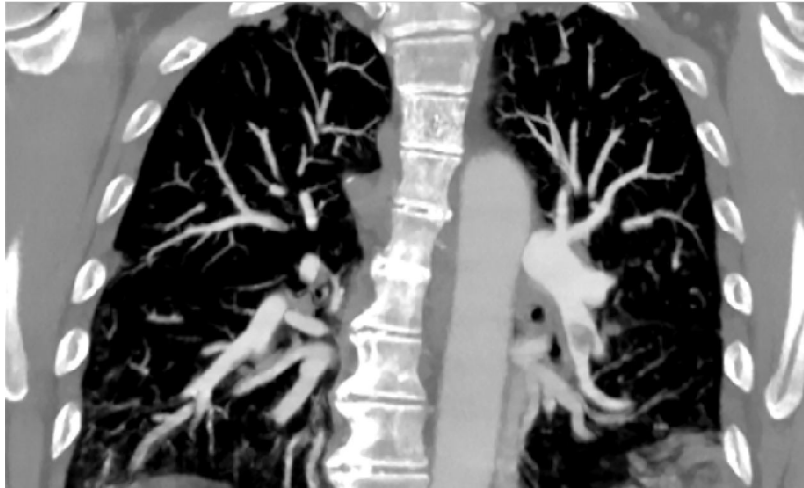


Figure 1. Bilateral pulmonary thromboembolism

UNDER PEER REVIEW