

Case study

Fusion of the sixth and seventh cervical vertebra: A case report

ABSTRACT

Aim: To report a rare fusion of the 6th and 7th cervical vertebra in a cadaver specimen.

Presentation of case: A fused C6-C7 vertebra was discovered during maceration in the Anatomy laboratory in a South-Eastern Nigerian University. The lamina and pedicles were completely fused while their bodies, transverse processes and spinous processes were fused partially.

Discussion: Block vertebra is the fusion of one or more adjoining vertebrae in which they act as one, both structurally and functionally. These fusions, although present in other regions, is more common in the cervical region. Among the reported cases, there is a higher incidence of fusion between C2-C3 with only few reported cases of fusion between C6-C7. Fused cervical vertebra impact biochemical and mechanical stress on the adjoining vertebra which results in various neurological and physical problems, hence the report could create an insight that could aid researchers and medical diagnoses.

Conclusion: This unusual fusion of C6-C7 vertebra reported provides basis of anatomical variations in which proper documentation of incidence and knowledge will be beneficial to anatomists, orthopaedic surgeons, radiologists and other medical personnel.

Keywords: Block vertebra, fusion, cervical vertebra, anatomical variations.

INTRODUCTION

The cervical vertebra, seven in number (C1-C7), makes up the bony framework of the neck. They develop from paraxial mesoderm and then differentiate into dermomyotome and sclerotome, with the sclerotome involved in the formation of the vertebra column [1]. Interruption in this process may lead to the formation of congenital fused vertebra also known as block vertebra in which they act structurally and functionally as one. This fusion can occur in any region of the vertebral column but is more commonly seen in the cervical region [2]. Fusion in the cervical region has been associated with disturbance in the expression of the PAX-1 gene and also with decrease in blood flow during development [3].

Block vertebra may be congenital as seen in chorda dorsalis [4, 5] or acquired in relation to conditions like juvenile rheumatoid arthritis, infection or trauma [6]. In some individuals, the condition may remain asymptomatic while some may manifest clinically with associated syndromes like Klippel-feil [7]. Knowledge of block vertebra is important to medical practitioners during intubation to avoid hyperextension of the neck.

PRESENTATION OF CASE

During maceration procedure on an anonymous male cadaver, carried out in the Anatomy Department laboratory of the College of Medicine and Health Sciences of Gregory University Uturu, Abia State, Nigeria, a fused C6 and C7 vertebra was discovered. The following features were observed;

1. The bodies were partially fused anteriorly and completely fused posteriorly (Fig. 1b)
2. The transverse processes were fused unilaterally (Fig.1b)
3. The lamina were completely fused bilaterally (Fig.1d)
4. The spinous processes were fused partially (Fig.1c)
5. The transverse foramina were patent (Fig 1a)

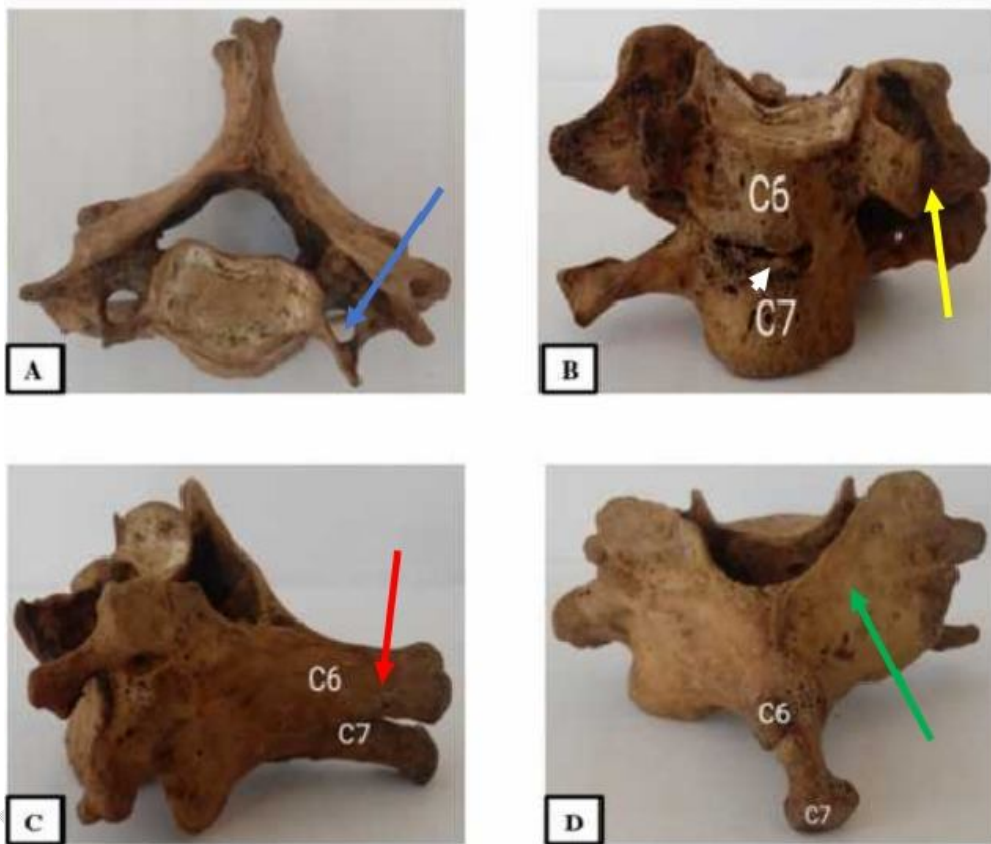


Figure 1 Fused C6-C7 cervical vertebrae: [A] Superior view [B] Anterior view [C] Lateral view [D] Posterior view. Blue arrow- patent transverse foramen; yellow arrow- transverse process; red arrow- spinous process; green arrow- lamina; white arrow head- partially fused vertebral body

DISCUSSION

Block vertebra, although present in other segments, are more common in the cervical region. Fused cervical vertebrae have been demonstrated between C2 and C3 [2, 3, 7], C6 and C7 [5], and between typical cervical vertebrae [1, 8]. Fusion between C2-C3 is the most common with an incidence of 0.4-0.7% [9]. A case of block vertebrae of C2-C6 with anterior longitudinal ligament calcification has also been reported [10]. Most of these reported cases have been on cadaveric osteology specimens but there are also reported cases of incidental findings during radiological procedures [6, 11]. In the discovered fused cervical vertebra, the vertebral bodies were partially fused anteriorly and completely fused posteriorly and the laminae were fused bilaterally. This is in contrast with the report of [5] where the vertebral bodies were completely fused anteriorly and partially fused posteriorly and the laminae were not fused bilaterally.

Congenital fusion of the vertebrae can cause stress on the adjoining parts of the vertebral column which may result in degenerative changes, vertebral discs tear and spondylosis [8]. People with block vertebra exhibit features or clinical signs such as short neck with restricted movements, webbed neck, low hair line and torticollis which usually develop in the third decade of life. [12]. Knowledge and proper documentation of the incidence of fused cervical vertebra is needed for early diagnosis of block vertebra which will be beneficial to both individuals with the condition, anatomists and to the medical personnel.

CONCLUSION

In conclusion we report a case of a complete fusion of C6-C7 vertebrae and knowledge of these fusions is important to anatomists, radiologists, anaesthesiologists, orthopaedics and neurosurgeons.

Ethical Approval:

As per international standard or university standard written ethical approval has been collected and preserved by the author(s).

REFERENCES

1. Singh A, Sekhon J, Abhilasha, Kaur C. Congenital fusion of typical cervical vertebrae. *MOJ Anat. Physiol.* 2016;2(6):166-68
2. Yadav Y, Goswami P, Bharihoke V. Cervical Vertebra Synostosis (C2-C3) - a case report. *American J Med Case Reports.* 2014;2(6):120-22
3. Kaushal P, Bhukya S. Fusion of C2 and C3: embryological and clinical perspective. *Anat J Africa.* 2018;7 (2):1281-83
4. Sutton D. *Textbook of radiology and medical imaging.* 5th ed. Edinburgh: Churchill Livingstone; 1993.
5. Vanitha, Teli C, Kadlimatti HS. Congenital fusion of C6 and C7 vertebra- a case report. *Journal Clin Dia Res.* 2015;9(8):1-2
6. Sarah Samson R, Varghese E, Kumbargere SN, Chandrappa PR. Fused cervical vertebrae: a coincidental finding in a lateral cephalogram taken for orthodontic diagnostic purposes. *BMJ case reports.* 2016; doi:10.1136/bcr-2016-217566
7. Ahmad T, Sultana A. fused second and third cervical vertebrae: case report. *J Med Eru.* 2013;

8. Anandaramajayan N, Mallikarjuna KC. Fused typical cervical vertebra- A case report. *J Curr Tre Clin Med Lab Biochem*. 2014;2(4):62-4
9. Soni P, Sharma V, Sengupta J. Cervical vertebral anomalies: incidental findings on lateral cephalogram. *Angle orthodontist*. 2008; 78:178-80.
10. Anathi SK, Agrawal R, Agrawal S. Case report: Multiple cervical vertebral fusion with ossification of anterior longitudinal ligament. *Anat J Africa*. 2013;2(2):128-29
11. Adeleye OA, Akinyemi OR. Cervical Kippel-Feil syndrome predisposing an elderly African man to central cord myelopathy following minor trauma. *African H Sci*. 2010;10(3):302-04
12. Imran SS, Dinanath P, Uzair SH. Congenitally fused cervical vertebra. *Anat Karnataka* 2012;6(3):73-5

UNDER PEER REVIEW