

Case study

Hormone positive HER2 negative breast cancer metastatic to the rectum: a case report

Abstract

Background: The rectum is an uncommon site for metastases from Invasive Ductal Carcinoma (IDC) of the breast, and it poses risks such as perforation and obstruction.

Case report: A 50-year-old non-diabetic, non-alcoholic, and nonsmoker premenopausal female patient diagnosed with rectal metastasis primarily originating from breast cancer.

In 2009, the patient was diagnosed with stage IV hormone positive, Her-2 (+2) negative, FISH positive right breast cancer with cervical (C6) vertebrae metastasis seen on PET scan. As she had oligo metastasis with a single bony focus, she was treated with intent to cure. For this purpose, she received radiation therapy to the cervical vertebrae, resulting in a complete response. This was followed by pseudo-neoadjuvant chemotherapy with six cycles of Docetaxel and trastuzumab. The patient then underwent a right-modified radical mastectomy. The pathology showed no complete response with residual 2.5 cm invasive carcinoma (PT2), and 4 out of 25 Axillary lymph nodes were positive for metastases (PN2). She was given (pseudo) adjuvant radiotherapy to the chest wall and lymphatics and was started on (pseudo) adjuvant tamoxifen. Trastuzumab was completed for one year as a (pseudo) adjuvant setting.

Her disease seemed to be cleared up as no new cancer signs were reported by follow-up full body scans (CT/PET). After seven years, in May 2016, her PET-CT scan showed multiple new hypermetabolic osseous lesions, in keeping with metastasis involving the right shoulder, mid-thoracic spine, left aspect of L5, right sacrum, and the greater trochanteric region of the left

femur and left ischium. She also presented a new hypermetabolic retroperitoneal paracaval lymph node, in keeping with metastasis. The new ill-defined hypodensity in the left hepatic lobe was associated with increased FDG uptake, which is suspicious for early metastasis. She also presented a tiny right lung peri-fissural nodularity that was too small to be characterized by PET. She was treated with Zoladex 3.6 mg injection monthly, Femara 2.5 mg daily, Palbociclib 125 mg PO daily for 21 days over a 28-day cycle, and Denosumab 120 mg monthly. The treatment was initiated in Singapore. As previously stated, Her-2 testing was reported as negative. The patient went into complete remission for more than six years, as documented by the PET scan conducted on January 19, 2022. Later, in June 2022, the patient developed signs and symptoms of intestinal obstruction (abdominal pain, nausea, and vomiting) and was diagnosed with rectal cancer metastases of breast origin.

Conclusion: As the patient first developed breast cancer with oligo-bony metastasis, which was successfully treated with chemotherapy and radiotherapy, but later relapsed in the lung, liver, lymph nodes, and multiple bony sites. She was treated successfully via hormonal and targeted therapy. Finally, she relapsed in the form of rectal metastasis.

Keywords: Breast cancer, rectal carcinoma, lung metastases, liver metastasis, bone metastasis, rectal metastases

Introduction

Breast cancer is the most frequently occurring cancer among women, affecting one in eight women over the course of their lives (1). Although the mortality rates are declining in Western countries, breast cancer remains the number one cause of cancer death among women globally (2). After ductal adenocarcinoma, Invasive Lobular Carcinoma (ILC) is the second most frequent

kind of invasive breast cancer. ILC accounts for 5 to 15% of invasive breast carcinomas, and its incidence is rising (3).

Furthermore, according to reports, metastatic breast cancer usually affects the lymph nodes, liver, brain, lungs, and bones (4), and approximately less than 1% of breast cancers spread to the gastrointestinal system (GIT). Therefore, the diagnosis is often missed in cases where the GIT is the only place where cancer has spread or when there is no history of breast cancer. Although GIT metastases are rare in clinical practice, metastasis from the breast to the GIT has been documented in autopsy data with rates ranging from 8 to 35 percent (5). Additionally, it has been reported that overall, 0.03 % and 0.05 % of all metastases are upper and lower GIT metastases, respectively (6). The rectum is a relatively uncommon site for metastasis and is susceptible to hazards such as blockages or perforations (7).

Moreover, in the past few decades, the prognosis for breast cancer has improved as a result of several medical advancements. However, the prognosis for systemic recurrence remains poor (8). The only available treatment options for cancer include radiotherapy, chemotherapy, targeted and hormonal therapy, and surgery performed according to the patient's condition. Therefore, early detection procedures and advanced treatment methods to improve patients' quality of life is vital issue. This case report describes the unique presentation of a patient who first developed breast cancer but was later diagnosed with breast cancer metastasis to the rectum.

Case Report

A case report was investigate it on a 50-year-old non-diabetic, non-alcoholic, nonsmoker premenopausal female with a known history of breast cancer. The woman was recently diagnosed with rectal metastasis primarily originating from breast cancer. In 2009, she first presented to the emergency department with complaints of neck pain. At that time, she was

diagnosed with stage IV right breast cancer with cervical vertebrae metastasis (C7). For this purpose, she received radiation therapy to the vertebrae, resulting in a complete response. By September 16, 2010, she completed six cycles of pseudo-neoadjuvant chemotherapy with docetaxel and trastuzumab at Mafraq hospital. On November 8, 2010, a right RMM was performed. The histopathology profile revealed pT2 (post-treatment 2.5 cm), IDC, pN2 (4/28), M1(bone), ER positive, PR positive, Her- 2 (+2) FISH positive. For this purpose, she received pseudo-adjuvant radiotherapy to the chest wall and lymphatics completed on January 27, 2010. She was also given pseudo-adjuvant Trastuzumab (Herceptin) for a year. Additionally, pseudo-adjuvant Tamoxifen was started after the completion of radiotherapy on February 1, 2011.

In May 2012, she underwent PET, which did not indicate any evidence of metastases/recurrences. Her mammogram was also performed on March 23, 2016, and showed no marked mammographic evidence of focal suspicious lesions. All findings were normal, indicating BI-RADS 1. This showed that her disease was cleared up, as no new cancer signs were reported. Moreover, after four years, on March 23, 2016, she underwent a CT scan of the lung which showed right upper lobe posterior segment new lung metastatic nodules. No marked evidence of newly distal metastasis was found. Later that year, she also complained about bony pains of increased severity.

A PET scan was performed on May 23, 2016. The findings revealed multiple new hypermetabolic osseous lesions in relation to metastasis, a new hypermetabolic retroperitoneal paracaval lymph node associated with metastasis, and a new ill-defined hypodensity in the left hepatic lobe associated with increased FDG uptake, which is suspicious for early metastasis. Additionally, there were signs of tiny right lung peri-fissure nodularity that were too small to be characterized by a PET scan. Therefore, the doctors suggested that this finding be followed with

a serial diagnostic CT chest. Moreover, there were signs of multiple foci of increased FDG uptake near the costochondral cartilage of the right chest wall, which could be inflammatory in nature. However, there was marked evidence of metastasis, which confirmed the diagnosis of a progressive disease.

The patient went to Singapore to seek a second medical opinion. There, she underwent a bone biopsy which confirmed the metastatic disease. However, HER-2 was found to be negative. ER+VE, PR-VE. Therefore, she was treated with Zoladex 3.6 mg injection monthly, Femara 2.5 mg daily, Palbociclib 125 mg PO daily for 21 days over a 28-day cycle, and Denosumab 120 mg monthly. Palbociclib started on April 30, 2017.

On January 15, 2018, the PET scan undergone at the Gulf International Cancer Center, in Abu Dhabi, UAE, showed the interval normalization of FDG-avid osseous lesions. Additionally, there were signs of multiple sclerotic lesions in the axial and proximal appendicular skeleton, which didn't show any abnormal FDG uptake associated with treated metastases either. There was also no visible evidence of FDG-avid or destructive osseous lesion. However, there was FDG-avid subcutaneous stranding in the bilateral buttock, suggestive of an inflammatory lesion. The PET scan findings also revealed FDG-avid maxillary sinus mucosal thickening, most likely indicative of sinusitis. However, no significant evidence of FDG-avid malignancy was found. On July 16, 2019, a bone scan was performed and showed stable responding multiple bone metastasis. Additionally, the left mammogram findings were reported as BI-RADS 1. Another PET scan performed on December 15, 2019, showed no evidence of FDG-avid malignancy and sinusitis, similar to the previous findings. The treatment was well tolerated, except that she developed drug-induced neutropenia, probably due to Palbociclib. The PET scan performed in December 2019 did not indicate any abnormal signs of FDG avid lesions.

Furthermore, she also saw an ophthalmologist on July 1, 2020, due to complaints of itching and epiphora. On October 15, 2020, a CT brain was performed. The findings revealed normal grey-white matter differentiation of both cerebral hemispheres, the absence of focal lesions, no sign of acute territorial infarction, and the normal size and symmetry of the ventricular system and basal cisterns. No abnormal intracranial enhancement, no evidence of metastatic deposits, or mucosal thickening of the right maxillary sinus were found. Additionally, there was no visible intracranial hemorrhage, no midline shifts, no skull vault or base abnormality, or abnormal intracranial enhancement. Moreover, no mass effect was seen in the scan. Furthermore, on November 22, 2020, a mammogram and ultrasound of the breasts were performed, and the findings were reported as stable findings - BI-RADS 2.

Later on, on March 1, 2021, the patient presented to the emergency department with major complaints of dizziness. The CT brain revealed a normal study of the brain. On August 31, 2021, a PET scan was performed, and the findings revealed a new tiny FDG-avid lytic lesion in the anterior right second rib. The doctors suggested that the presence of tiny lesions, in the absence of trauma, suggested possible metastasis. However, the rest of the study did not indicate any evidence of FDG-avid malignancy.

Later on, September 4, 2021, a bone mineral density scan was performed and showed Osteopenia T SCORE -1.7. Additionally, an ultrasound of the thyroid performed on September 9, 2021, showed the abnormal size of the thyroid gland, with altered echotexture with no discrete masses. Findings revealed benign lesions. At that time, the patient was seen by a pulmonologist in a private facility due to a persistent cough. To rule out any lung infection, on November 13, 2021, the patient underwent lung testing, which indicated normal findings. Moreover, on January 19, 2022, a re-evaluation PET scan was performed. It did not indicate any evidence of FDG avid

activity. This finding suggested that the patient was completely responding to the treatment. As the patient also developed hypertension, she was referred to the internal medicine department. After a year, an annual left mammogram and left breast ultrasound were performed. The findings were reported as BI-RADS 2. After two weeks, the patient started developing abdominal pain, nausea, and vomiting. For this purpose, she went to a private hospital. An upper endoscopy testing was conducted on June 22, 2022, and showed pan gastritis and a helicobacter infection, for which she received treatment.

Additionally, a lower endoscopy performed on June 22, 2022, showed strictures in the rectal region. At the end of the month, an MRI of the pelvis revealed isocentric wall thickening and enhancement involving the wall of the rectum, 7 cm away from the anal verge, the tumor infiltration in the muscular propria, the involvement of the mesorectum, as manifested by spiculated enhancing lesions measuring 18 x 12 mm beyond the confines of the rectal wall, tumor extension for an approximate segment of 3 cm involving the mid rectum. The most invasive part of the mass involved the right lateral aspect with thickening and enhancement of the mesorectal fascia. However, no evidence of regional lymphadenopathy was found. The patient was admitted to the hospital and seen by a surgeon. A rectal stent was inserted. Additionally, she underwent a repeated biopsy which showed adenocarcinoma of breast origin, ER + PR negative, Her-2 negative. This case was discussed in the tumor board on July 1, 2022. The multidirectional team decided to go for systemic chemotherapy and re-evaluate the patient's condition. The Palbociclib, Femara, and Zoladex therapy was discontinued. The surgical option was not feasible due to the lower location of the tumor and the very high associated comorbidity. The patient was also suggested to receive docetaxel as she did receive first-line therapy in 2007 and responded very well to it. Cycle 1 started on July 21, 2022.

Furthermore, on July 7, 2022, a lower endoscopic ultrasound was performed. The findings revealed an extrinsic traversed moderate stenosis measuring 6 cm (in length) x 1 cm (inner diameter) in the mid-rectum. The endosonographic findings revealed diffuse wall thickening found in the rectum. This was encountered 8 to 14 cm from the anal verge. Additionally, the site of thickening was circumferential. This finding appeared to be primarily due to the increased thickness of the submucosa (Layer 3), muscularis propria (Layer 4), and perirectal fat (Layer 5). Moreover, the thickness of the abnormal layer(s) measured 6 mm, while the rectal wall was up to 10 mm thick. A fine needle biopsy was also performed. Furthermore, Color Doppler imaging was used prior to needle puncture to confirm a lack of significant vascular structures within the needle path. The cellularity of the specimen was found to be adequate. However, the results of the final cytology were non-conclusive. Later, a rectal biopsy consisting of multiple intertwined pieces of brownish-colored tissue cores was performed. Additionally, the section showed invasive malignant tumor cells arranged in small fragments and focal acinar patterns. The tumor cells showed a high NC ratio and enlarged irregular nuclei with dense chromatin. The immunohistochemistry profile revealed that the tumor cells are strongly and diffusely positive for epithelial marker Cytokeratin LMW CAM5.2 antibody stain and EMA. Additionally, the protein markers CK7 GATA3 were found to be diffusely positive. However, CK20, CDX2, TTF1, and neuroendocrine markers, including synaptophysin and chromogranin, were all found to be negative.

The immunophenotype was suggestive of breast primary (CK7 positive, CDX2 negative, Ck 20 negative, GATA3 positive). The rectal biopsy revealed invasive adenocarcinoma originating from the breast. (Pictures 1,2,3).

So far, the patient has completed six cycles of docetaxel chemotherapy. The re-evaluation CT scan after Cycle 4 showed stable disease. The plan is to repeat the PET scan, as if there is persistent activity, it will add loco-regional radiotherapy to the pelvis.

Discussion

As the number of breast cancer survivors continues to increase, metastatic breast cancer presentations are predicted to rise. Breast cancer is the most common primary cancer to spread to the gastrointestinal tract (9). Breast cancer that has spread to the GIT outside of the liver usually starts in the lobular carcinoma subtype, which makes up 8–14% of all breast adenocarcinomas. This is different from invasive ductal carcinoma, which is more common (10). This may be due to a specific tropism of lobular cells towards the gastrointestinal tract. In our case, ductal carcinoma of the breast was found to be responsible for the metastatic spread to the rectum. Additionally, large retrospective research on the examination of the patterns of metastatic dissemination of breast carcinoma revealed that the small intestine is the most frequent site in the gastrointestinal tract, followed by stomach cancer (11). However, metastases to the rectum were found to be extremely uncommon. Recent research revealed that only 7 % of 206 breast cancer patients with known GIT involvement had rectum metastases (12).

Clinical symptoms of breast cancer metastasized to the rectum include bowel obstruction, constipation, abdominal pain, and bloody stools. Hence, it is easily mistaken for helicobacter infection or primary rectal cancer (8). Our patient also presented with complaints of abdominal pain, nausea, and vomiting, which was initially thought to be caused by gastritis and helicobacter infection. However, endoscopic and pathologic findings revealed that it was due to metastatic rectal cancer.

Additionally, as patients with primary rectal carcinoma present with similar features of metastatic rectal carcinoma, more imaging testing might be necessary to distinguish these conditions. On colorectal endoscopy, rectal metastatic lesions typically have an infiltration pattern, as demonstrated in our instance, as opposed to the mass-like lesions that protrude into the lumen in most initial rectal tumors (13).

As patients with breast cancer live longer after diagnosis and receiving a treatment, the rate of recurrence and metastasis increases gradually over time. Even if the patient's disease is detected at an early stage, rectal metastases from breast cancer may not manifest for several years following therapy (need a reference). Notably, GI metastases could develop after a 30-year latency period (14). The median time for metastasis was six years (0.25–12.5 years), which corresponds to our 11-year experience. Therefore, oncologists and gastroenterologists should be aware of the relatively high incidence of late disease metastasis in breast cancer patients, especially those with an uncommon location, such as the rectum.

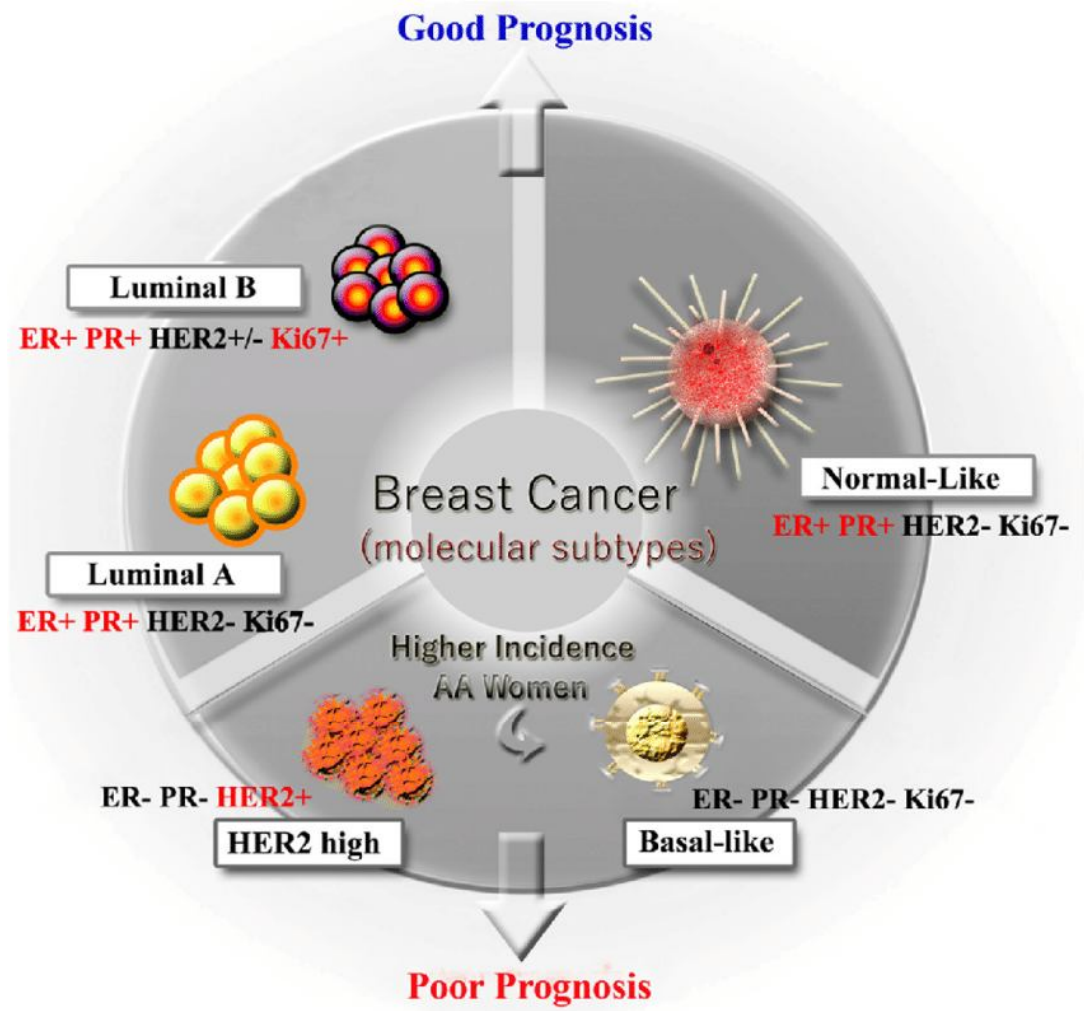


Figure 1. Different molecular subtypes of breast cancer.

Charan M, Verma AK, Hussain S, Misri S, Mishra S, Majumder S, Ramaswamy B, Ahirwar D, Ganju RK. Molecular and Cellular Factors Associated with Racial Disparity in Breast Cancer. *International Journal of Molecular Sciences*. 2020; 21(16):5936. <https://doi.org/10.3390/ijms21165936>

Conclusion: There is a very high likelihood of the development of rectal metastatic disease in a patient with breast cancer, particularly stage IV, who has developed new gastrointestinal tract (GIT) symptoms. The patient under this investigation was developed breast cancer, which later

progressed to the lung, and later, to the rectum. In cases of colorectal mass with a prior history of breast cancer, a thorough examination and thoughtful treatment plan are required.

Ethical Approval:

As per international standard or university standard written ethical approval has been collected and preserved by the author(s).

Consent

As per international standard or university standard, patient(s) written consent has been collected and preserved by the author(s).

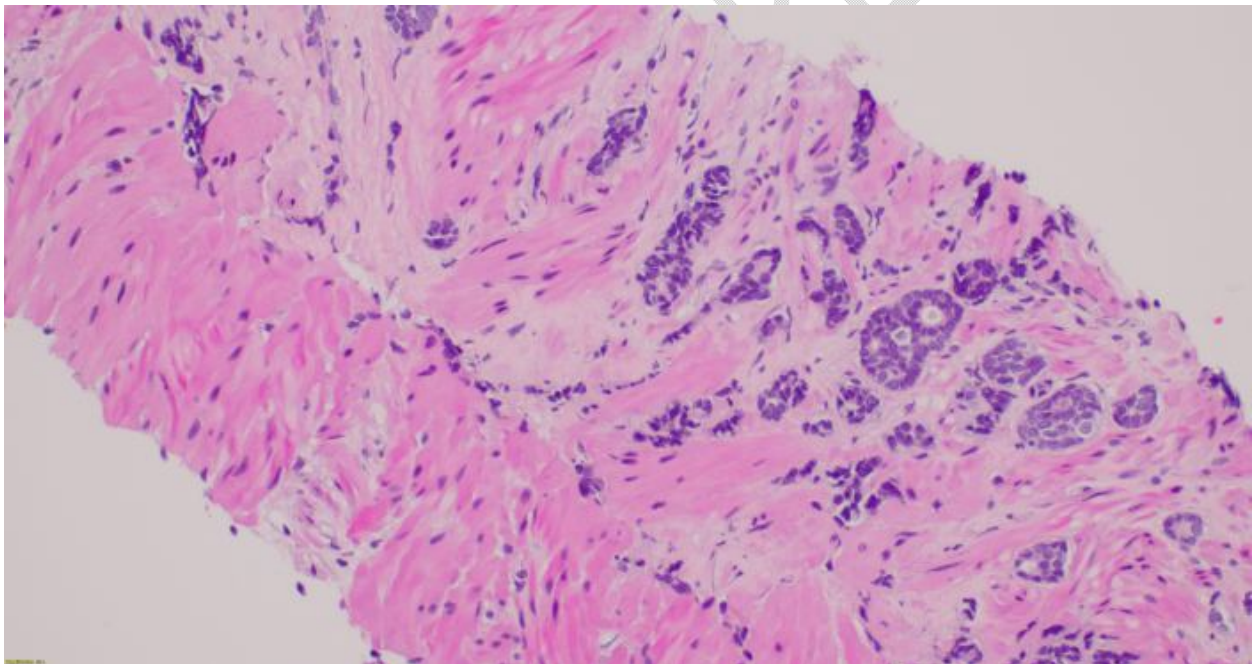


Figure 2: Core biopsy showing infiltrative adenocarcinoma arranged in glands and single cells. 20x Hematoxylin and Eosin stain.

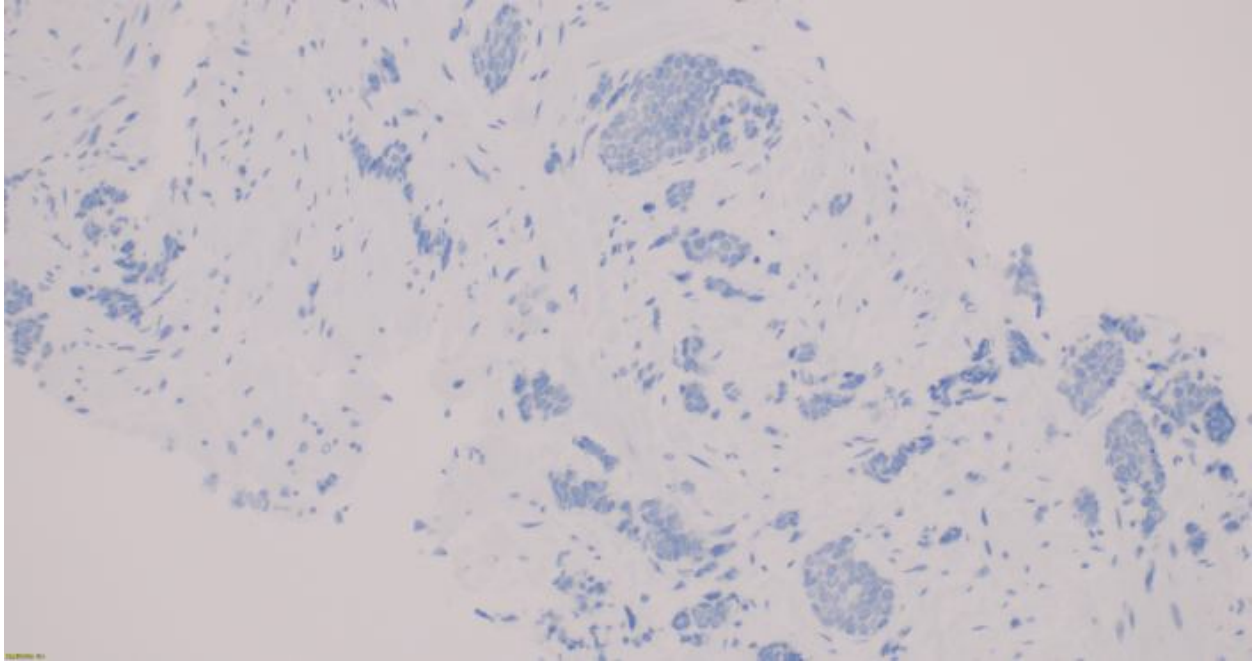


Figure 3: The tumor cells showing negative CDx2 immunostain (20x CDX2 IHC).

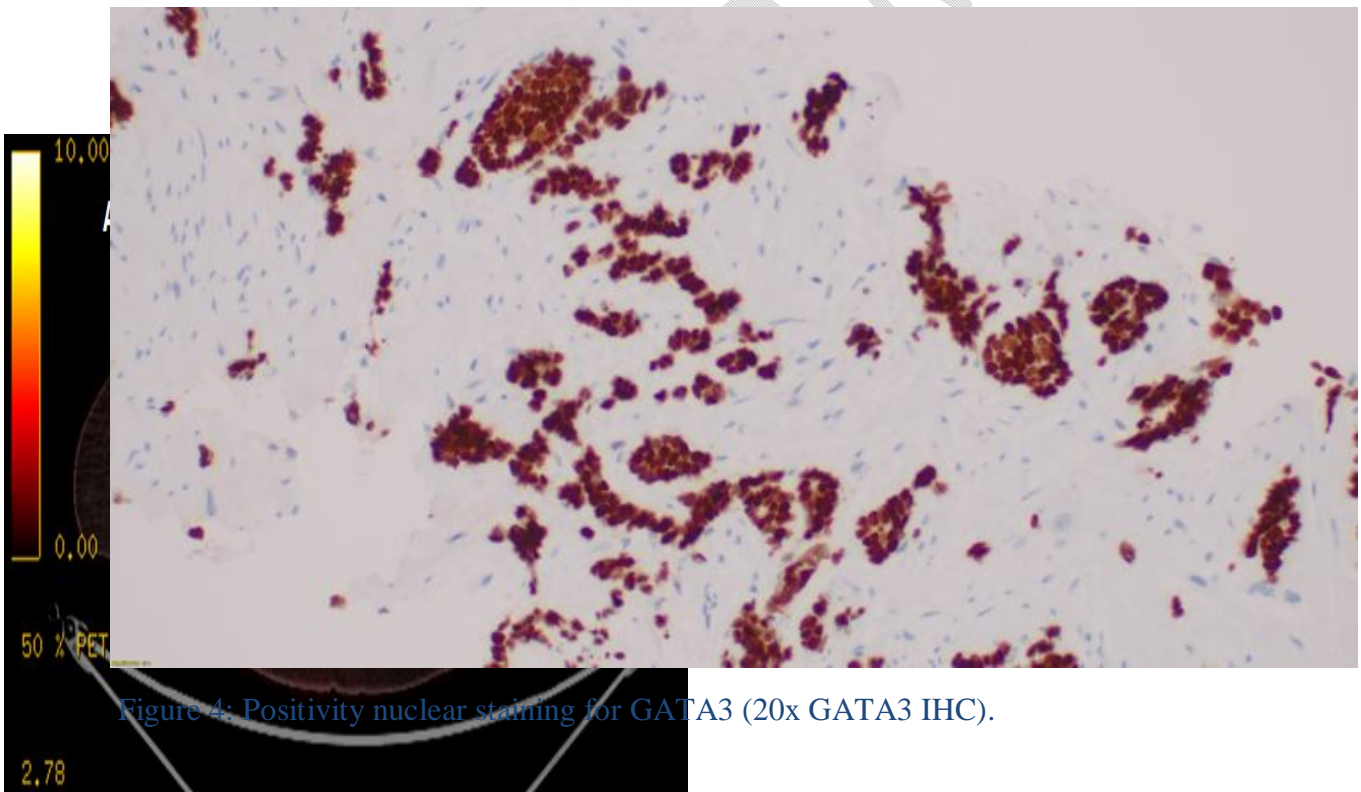
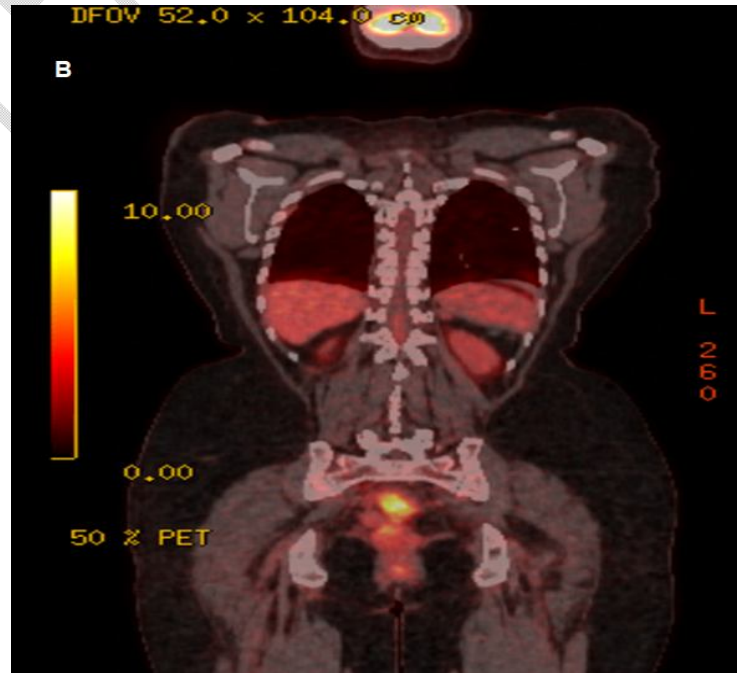


Figure 4: Positivity nuclear staining for GATA3 (20x GATA3 IHC).

Figure 5 (A-B): The PET scan showed FDG uptake in the upper rectum region.



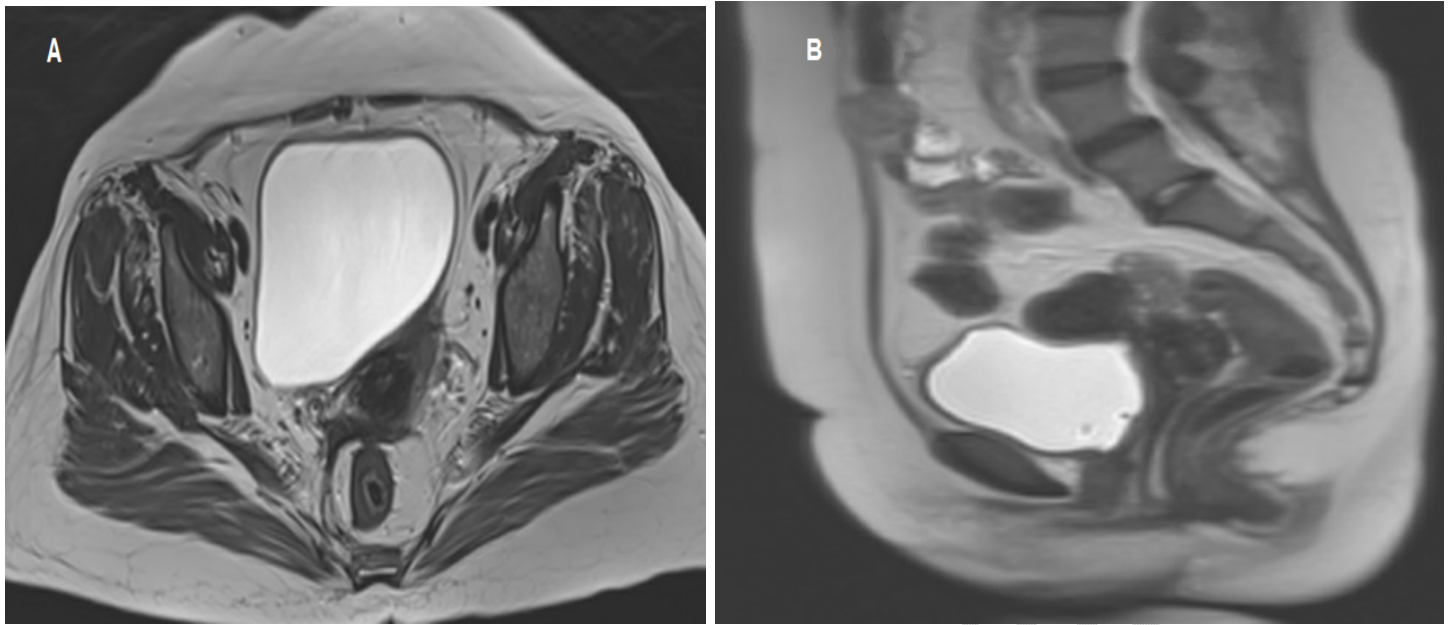


Figure 6 (A-B): The MRI of the pelvis showed thickening with enhancement of the rectum.

References

1. Lau LC, Wee B, Wang S, & Thian YL. Metastatic breast cancer to the rectum: A case report with emphasis on MRI features. *Medicine (Baltimore)*. 2017;96(17):e6739.
2. Torre LA, Bray F, Siegel RL, Ferlay J, Lortet-Tieulent J, & Jemal A. Global cancer statistics, 2012. *CA Cancer J Clin*. 2015;65(2):87-108.
3. Ruymbeke H, Harlet L, Stragier B, Steenkiste E, Ryckx M, & Marolleau F. Anorectal metastasis from breast carcinoma: a case report and review of the literature. *BMC Research Notes*. 2018;11(1):268.
4. Miller KD, Siegel RL, Lin CC, Mariotto AB, Kramer JL, & Rowland JH, et al. Cancer treatment and survivorship statistics, 2016. *CA: A Cancer Journal for Clinicians*. 2016;66(4):271-89.
5. Ambroggi M, Stroppa EM, Mordenti P, Biasini C, Zangrandi A, & Michieletti E, et al. Metastatic Breast Cancer to the Gastrointestinal Tract: Report of Five Cases and Review of the Literature. *International Journal of Breast Cancer*. 2012;2012:439023.
6. Algethami NE, Althagafi AA, Aloufi RA, Al Thobaiti FA, & Abdelaziz HA. Invasive Lobular Carcinoma of the Breast With Rectal Metastasis: A Rare Case Report. *Cureus*. 2022;14(3).

7. Abbas TO, Al-Naimi AR, Yakoob RA, Al-Bozom IA, & Alobaidly AM. Prostate cancer metastases to the rectum: A case report. *World Journal of Surgical Oncology*. 2011;9(1):56.
8. Hoang DA, Nguyen AQ, Nguyen KT, & Pham MD. Rectal metastasis originating from breast cancer: A rare case report. *Annals of Medicine and Surgery*. 2022;78:103841.
9. INOUE H, ARITA T, KURIU Y, SHIMIZU H, KIUCHI J, & YAMAMOTO Y, et al. Colonic Metastasis from Breast Cancer: A Case Report and Review of the Literature. *In Vivo*. 2022;36(1):522-7.
10. Lau LC, Wee B, Wang S, & Thian YL. Metastatic breast cancer to the rectum: A case report with emphasis on MRI features. *Medicine*. 2017;96(17):e6739.
11. Ambroggi M, Stroppa EM, Mordenti P, Biasini C, Zangrandi A, & Michieletti E, et al. Metastatic breast cancer to the gastrointestinal tract: report of five cases and review of the literature. *International Journal of Breast Cancer*. 2012;2012.
12. Galanopoulos M, Gkeros F, Liatsos C, Pontas C, Papaefthymiou A, & Viazis N, et al. Secondary metastatic lesions to colon and rectum. *Annals of gastroenterology*. 2018;31(3):282.
13. Lau LC, Wee B, Wang S, & Thian YL. Metastatic breast cancer to the rectum: a case report with emphasis on MRI features. *Medicine*. 2017;96(17).
14. Benfiguig A, Anciaux M, Eugène C, Benkemoun G, & Etienne J. Gastric metastasis of breast cancer occurring after a cancer-free interval of 30 years. *Annales de Gastroenterologie et d'Hepatology*; 1992.

UNDER PEER REVIEW