

**Evaluation of Predictive Factors Associated With Resolution of Acute
Central Serous Chorioretinopathy**

Abstract

Background: Central serous Chorioretinopathy (CSC) is characterized by serous subretinal fluid (SRF) leakage and accumulation with subsequent serous retinal detachment. We conducted this study to study the predictive factors associated with resolution of the non-treated, first episode of acute CSC including systemic factors and ocular factors using different imaging modalities.

Methods: This prospective, observational study of 30 affected eyes and 30 fellow eyes of 30 consecutive patients with non-treated, first episode of acute CSC and age and sex matched control group of 30 eyes were also studied. Detailed history taking including: name, age, residence, previous and present ocular or systemic diseases, previous ocular trauma, previous ocular surgery, assessment of systemic factors including, smoking, hypertension, Helicobacter pylori infection, pregnancy, sleeping disturbance, autoimmune diseases and psychological factors, history of intake of ocular or systemic medications especially corticosteroid and psychopharmacological medications, best corrected visual acuity (BCVA).

Results: The baseline BCVA of the "Improvement" group was lower than that of "No Improvement" group and the difference was statistically significant (p. value 0.014*). On the other hand, the final BCVA of the "Improvement" group was higher than that of "No Improvement" group and the difference was also statistically significant (p. value 0.005*). There was a statistically significant decrease of the mean automated central retinal thickness (ACRT) (P-value 0.004*), mean vertical SRF dimension (VD) (P-value 0.012*), mean horizontal SRF dimension (HD) (P-value 0.022*) and mean SRF height (P-value 0.002*).

There was a statistically significant negative correlation between age (years) and the mean baseline SFCT (um) in both affected and fellow eyes (P-value 0.013* and 0.014* respectively). In other words, the older the patient was, the thinner the baseline SFCT in both eyes (affected and fellow) will be measured.

Conclusions: Proper assessment of systemic factors associated with CSC and ocular factors using multimodal ocular imaging help us in predicting the course and visual prognosis of CSC cases. We depended on evaluating the difference of all variables between the "improvement group, n=22 cases" (decreased SRF height after 3 months) and "no improvement group, n=8 cases" (persistent/increased SRF height after 3 months).

Keywords: Resolution, Central serous Chorioretinopathy, Best corrected visual acuity

Introduction:

Central serous Chorioretinopathy (CSC) is characterised by serous subretinal fluid (SRF) leakage and accumulation with subsequent serous retinal detachment due to hyperpermeability of the choroidal vessels and failure of the retinal pigment epithelium (RPE) in resorbing the excessive fluid accumulation, causing vision loss, metamorphopsia, and changes in colour and contrast sensitivity ^[1].

Acute CSC, which is characterised by serous retinal detachment with limited focal or multifocal RPE alterations that typically recovers within a few months without treatment, and non-resolving CSC, which presents with more extensive macular abnormalities without spontaneous recovery, have been described in the literature, but their overlap is currently unclear ^[2].

Observation without therapy is commonly advised as the initial treatment for patients with acute CSC ^[2].

Several treatment options are available for patients with photocoagulation of extramacular leaking points by direct argon or micro pulse laser can reduce the duration of single episodes, and half-dose or half-fluence verteporfin photodynamic therapy (PDT) may contribute to shorten episode duration in cases of non-resolving serous retinal detachment or severe vision loss ^[3], Moreover, mineralocorticoid-receptor (MR) antagonists administered orally have demonstrated positive benefits ^[4].

The key mechanisms leading to CSC are choroidal vasodilatation and leakage through RPE; Furthermore, SRF resorption depends primarily on the pumping capacity of RPE cells; thus, several characteristics involving the choroid/RPE may impact acute episode duration, including subfoveal choroidal thickness (SFCT), elevation of PED, intensity of RPE leakage and choroidal hyperpermeability, initial SRF volume, time-dependent fluid resorption pattern, patient age, history of steroid intake, and arterial blood pressure ^[2].

The better the understanding of systemic and ocular factors influencing episode duration and enhanced different imaging modalities of CSC, the greater the capability to diagnose and treat earlier instances at risk for persistence prior to photoreceptor and RPE damage ^[5].

We conducted this study to study the predictive factors associated with resolution of the non-treated, first episode of acute CSC including systemic factors and ocular factors using different imaging modalities.

Patients and Methods:

This prospective, observational study of 30 affected eyes and 30 fellow eyes of 30 consecutive patients with non-treated, first episode of acute CSC and age and sex matched control group of 30 eyes were also studied. A CSC episode is defined as the presence of visual symptoms (vision impairment, metamorphopsia, micropsia, dyschromatopsia or central scotoma) associated with presence of SRF in optical coherence tomography (OCT) with a leaking site on fluorescein angiography (FA).

A written informed consent was received from the patient or the patient's family. The study was conducted between January 2019 and September 2021 at the outpatient retina clinic of the Ophthalmology Department, Faculty of Medicine, Tanta University, Egypt, with clearance from the Ethical Committee of Tanta University Hospitals.

Exclusion criteria included patients who presented more than 30 days after the onset of symptoms, pigmentary changes on fundoscopy indicating previous CSC episodes or chronicity, significant media opacity affecting the quality of imaging, and SRF secondary to other retinal pathologies such as dome-shaped macula and dystrophies.

All patients were submitted to the following:

Full data taking including: name, age, residence, previous and present ocular or systemic diseases, previous ocular trauma, previous ocular surgery, assessment of systemic factors including, smoking, hypertension, Helicobacter pylori infection, pregnancy, sleeping

disturbance, autoimmune diseases and psychological factors, history of intake of ocular or systemic medications especially corticosteroid and psychopharmacological medications, BCVA. (Snellen visual acuities were converted to logMAR for the purposes of statistical analysis), Serum cortisol level (morning and night), Analysis of H. pylori antibodies in the stool, Comprehensive eye examination involving evaluation of the anterior and posterior segments (Dilatation of the pupils using tropicamide 1 percent to facilitate examination and imaging was done for all cases).

Baseline and after 3 months of observation, multimodal imaging was obtained.

Baseline multimodal retinal imaging:

- **Fundus Fluorescein Angiography (FFA):**

FFA was performed via intravenous injection of 10% sodium fluorescein dye using the Heidelberg Retinal Angiogram-2 (Heidelberg Engineering, Germany). For patients who had undergone FFA using other angiographic devices within the previous few days (up to seven days), we did not perform another angiogram and relied on the printed FFA images and reports. Using FFA, leakage sites (single or multiple) at the RPE level may be discovered in up to 95% of all CSC types. The source of a leak might be: Macular or Extra-macular

Patterns seen in FFA in acute CSC cases:

Pinpoints of increasing fluorescence along the phases of the angiogram.

Ink-blot pattern with progressive circular expansion of the hyper fluorescence.

Smokestack pattern in which the hyper fluorescence ascend before lateral diffusion of the dye (mushroom-like image).

FAF was used to detect alterations in RPE cells.

FAF imaging was done using Spectralis SD-OCT (Heidelberg Engineering, Heidelberg, Germany)

An aberrant FAF was characterised as either an increased or reduced FAF signal relative to the normal FAF background outside of lesions.

Patterns seen in FAF in acute CSC cases;

- ✓ **Average FAF;** if there is no difference can be detected between it and normal.
- ✓ **Hypo FAF (diminished);** if there uniform decreased AF where SRF exists.
- ✓ **Hypo FAF associated with hyper AF dots.**

Optical coherence tomography (OCT):

The OCT imaging was performed using DRI-OCT Triton, Swept source OCT (SS-OCT) (Topcon Corp., Japan). SS-OCT is considered the primary imaging modality for diagnosis and follow up of CSC as it provides quick, non-invasive, reproducible and high-definition images for retinal layers, subretinal space and choroid. It has a high imaging speed (100,000 A-scan/s), SS-OCT uses long wavelength (1050 nm) with bandwidth of 100 nm which allows better penetration into tissue with imaging through optical opacities and is invisible to the subject.

OCT parameters:

A. Choroid

- ✓ SFCT measured manually using caliber.
- ✓ Evaluation of presence of dilated choroidal vessels (Pachyvessels).
- ✓ Evaluation of inner choroidal layers.
- ✓ Evaluation of presence of focal choroidal excavation.

B. Retinal pigment epithelium (RPE)

- ✓ Evaluation of pigment epithelial detachment (PED).
- ✓ Leakage site; in the form of PED, RPE elevation, hyper reflective area suggesting fibrinous exudate in the subretinal space or sagging of posterior retinal layers.
- ✓ Evaluation of presence of RPE micro rip.
- ✓ RPE hypertrophy/atrophy.

C. Serous retinal detachment:

- ✓ SRF dimensions; in both vertical and horizontal meridians and height.
- ✓ Evaluation of photoreceptors outer segment elongation.
- ✓ Evaluation of presence of hyper reflective subretinal deposits.

D. Retinal layers:

- ✓ Integrity of external limiting membrane (ELM) and IS/OS line.
- ✓ Evaluation of presence of intraretinal hyper reflective deposits.
- ✓ Evaluation of cystoid macular degeneration.
- ✓ Central foveal thickness measurement.

• ***Optical coherence tomography angiography (OCTA):***

The OCTA imaging was performed using DRI-OCT Triton, Swept source OCT (SS-OCT) (Topcon Corp., Japan).

OCTA imaging:

OCTA imaging utilises 6x6 mm scanning regions focused on the fovea. Within the macular region, the retina and choroid were segmented into four areas:

1. Superficial capillary plexus (SCP): includes the space from the inner border of ILM to the inner border of IPL. 2. Deep capillary plexus (DCP): comprises the region between the outer borders of IPL and INL. 3. Outer retina: It generally stretches from OPL to RPE and is avascular. 4. Choriocapillaris (CC): a 20- μ m-thick slab positioned beneath the RPE-membrane Bruch's (BM) complex.

Slabs and slices are terms that are used to refer to tissue volumes, slabs refer to thick tissue sections such as outer retina, whereas slices refer to thin sections of few microns used to examine fine details. In order to quantify the OCTA findings within the macula, 2 parameters were used: Foveal avascular zone (FAZ) area in mm² and Vessel area density (VAD) (%). The parameter used to measure FAZ dimensions was its area in square millimeters. This was done by outlining the FAZ in both SCP and DCP images by the observer and the area was then estimated by the device. In order to achieve a higher level of valid assessment of FAZ and to assess the reproducibility of FAZ measurement, 2 different measurements were performed outlining and measuring FAZ area and the average (mean) of the measurements of the 2 measurements was used in the subsequent analysis.

VAD is defined as the proportion of the segmented region occupied by vessels, which is the fovea-centered 6x6 millimetre square scanned area. After transforming the collected pictures into binary forms using ImageJ software, it was manually quantified and its particles were analysed (ImageJ 1.50; National Institutes of Health, Bethesda, Maryland, USA).⁽⁸⁹⁾

OCTA is prone to image artifacts. In case of segmentation errors, manual correction of segmentation was done. The presence of other artifacts was accepted but images that showed severe degrees of artifacts of different forms that prevented proper interpretation were excluded.

OCTA parameters: FAZ area in mm² for both SCP and DCP, VAD % for SCP, DCP and CC, Choriocapillaris features:(Dark areas; that may be SRF, irregular flat PED, intraretinal hyper reflective deposits or OS elongation, Dark spots; that may be PED, intraretinal hyper reflective deposits or pigment migration, Abnormal vessels; dilatation, indistinct tangled, tangled (ball of wool) or pruned tree).

Retinal imaging after observation period (3 months):

OCT and OCTA imaging were repeated by DRI-OCT Triton, Swept source OCT (SS-OCT) (Topcon Corp., Japan) using the same previous image analysis done in baseline retinal imaging. The patients of the study were divided based on the change of SRF height into 2 groups: **Group 1 "Improvement group"**, showing decreased SRF height after 3 months of observation by more than 10% of its baseline value. **Group 2 "No improvement group"**, showing persistent SRF (change in the SRF height within 10% of its baseline value) or increased SRF height by more than 10% of its baseline value after 3 months of observation.

Statistical analysis

SPSS v26 was used for the statistical analysis (IBM Inc., Armonk, NY, USA). Comparisons between the two groups were made using the unpaired Student's t- test, and numerical variables were reported as means and standard deviations (SDs). Quantitative variables were displayed as frequencies and percentages, and were analysed with the Chi-squared test or

Fisher's exact test, respectively, for qualitative data. Coefficient of correlation in a linear relationship: A correlation between two quantitative variables within the same group was investigated using this method. Using a regression analysis with several predictors: formula is, Y is equal to $mx_1+mx_2+mx_3+b$.

Results:

Table 1 shows Baseline characteristics, prevalence of systemic factors and antibodies for *Helicobacter pylori* of the studied patients. The improvement occurred in younger age significantly higher than old age. This study concluded a statistically significant relationship between tendency for self-resolution in acute CSC cases and being negatively tested for *H.pylori* antibodies in the stool. Serum cortisol level either at morning was insignificantly different between the two groups (P-value 0.820) or at night (P-value 0.418). **Table 1**

Table 1: Baseline characteristics, prevalence of systemic factors, antibodies for *Helicobacter pylori* and serum cortisol of the studied patients (n = 25)

		Improvement (n=22 cases)		No Improvement (n=8 cases)		p. value			
		Mean ± SD		Mean ± SD					
Age (years)		36.05 ± 6.27		41.50 ± 7.07		0.049*			
Sex	Male (%)	18 (81.8%)		8 (100%)		0.195			
	Female (%)	4 (18.2%)		0 (0%)					
		Hypertension		Steroid intake		Smoking		Stress or psychiatric medications	
		Present	Absent	Present	Absent	Present	Absent	Present	Absent
Improvement (decreasing SRF)		2	20	2	20	13	9	15	7
No improvement (persisting/increasing SRF)		3	5	1	7	5	3	6	2
Total		5	25	3	27	18	12	21	9
P-value		0.123		0.647		0.276		0.221	
		H.pylori Abs. Positive		H.pylori Abs. Negative		P-value			
		N	%	N	%				
Improvement (decreasing SRF)		2	25	20	90.9	0.001*			
No Improvement (persisting/increasing SRF)		6	75	2	9.1				
Total		8	100	22	100				
		Mean cortisol-Morning (mcg/dL)		Mean cortisol-Night (mcg/dL)					

Improving (decreasing SRF)	14.26 ± 2.50	6.57 ± 1.02
Not improving (persisting/increasing SRF)	14.49 ± 2.10	6.90 ± 0.79
P-value	0.820	0.418

The baseline BCVA of the "Improvement" group was lower than that of "No Improvement" group and the difference was statistically significant (p. value 0.014*). On the other hand, the final BCVA of the "Improvement" group was higher than that of "No Improvement" group and the difference was also significant (p. value 0.005*). No FFA pattern is more related to resolution and the difference was insignificant. No FAF pattern is more related to resolution and the difference was insignificant (p. value 0.642). **Table 2**

Table 2 :BCVA, patterns of Fundus Fluorescein Angiography and patterns of Fundus auto-fluorescence (FAF) and their relation to resolution in the studied groups

		Improvement (n=22 eyes)		No Improvement (n=8 eyes)		p. value	
BCVA (log MAR)	Baseline	0.50	± 0.20	0.30	± 0.12	0.014*	
	After 3 M.	0.26	± 0.24	0.53	± 0.13	0.005*	
		Ink-Blot (IB)		Smoke-stack (SS)			
		N	%	N	%	Total	
Improvement (Decreased SRF)		14	63.6	8	36.4	22 cases	
No improvement (persistent/increased SRF)		6	27	2	25	8 cases	
P-value		0.571				30 cases	
		Average AF		Hypo AF		Hypo AF + Hyper AF dots	
		N	%	N	%	N	%
Improvement (decreasing SRF)		3	13.6	10	45.5	9	40.9
No Improvement (persisting/increasing SRF)		2	25	4	50	2	25
P-value		0.642				30 cases	

SRF :subretinal fluid, BCVA :best corrected visual acuity.

There was a significant decrease of the mean automated central retinal thickness (ACRT) (P-value 0.004*), mean vertical SRF dimension (VD) (P-value 0.012*), mean horizontal SRF

dimension (HD) (P-value 0.022*) and mean SRF height (P-value 0.002*), but the decrease in the mean SFCT was no significant (P-value 0.340) at the end of observation period. **Table 3**

Table 3: SS-OCT data in "Improvement" and "No improvement" groups.

		Improvement group (n=22 cases)		No Improvement group (n=8 cases)		p. value
ACRT (um)	Baseline	461.18	± 126.57	393.63	± 141.61	0.220
	After 3 M.	303.32	± 71.55	466.50	± 137.77	0.001*
VD (um)	Baseline	2987.68	± 1088.75	2952.88	± 847.08	0.936
	After 3 M.	1932.36	± 1132.29	3092.63	± 893.70	0.014*
HD (um)	Baseline	3082.91	± 1075.52	2815.00	± 803.53	0.528
	After 3 M.	2107.50	± 1206.38	3018.00	± 768.56	0.057
Height (um)	Baseline	258.18	± 111.29	203.63	± 122.32	0.054
	After 3 M.	109.91	± 76.73	279.75	± 102.75	0.001*
SFCT (um)	Baseline	402.39	± 50.92	367.13	± 87.08	0.179
	After 3 M.	369.45	± 51.82	346.50	± 88.09	0.384
SRF clarity	Clear (%)	17 (77.3%)		8 (100%)		0.140
	Turbid (%)	5 (22.7%)		0 (0%)		
RPE Irregularity	Present (%)	17 (77.3%)		7 (87.5%)		0.536
	Absent (%)	5 (22.7%)		1 (12.5%)		

ACRT, automated central retinal thickness, *VD*, vertical subretinal fluid dimension. *HD*, horizontal subretinal fluid dimension. *SFCT*, subfoveal choroidal thickness. *SRF*, subretinal fluid. *RPE*, retinal pigment epithelium.

There was a significant positive correlation between the baseline BCVA (log MAR units) and the baseline ACRT (um) (P-value 0.001*) and the baseline SRF height (um) (P-value 0.002*). This means that the higher baseline ACRT or SRF height (um) are associated with worse baseline BCVA. There was a significant positive correlation between the change BCVA (log MAR units) and the change in both ACRT (um) (P-value 0.001*) and the SRF height (um) (P-value 0.001*) after 3 months of follow up.

There was a significant negative correlation between age (years) and the mean baseline SFCT (um) in both affected and fellow eyes (P-value 0.013* and 0.014* respectively). In other words, the older the patient was, the thinner the baseline SFCT in both eyes (affected and fellow) will be measured. **Table 4**

Table 4: Correlation between baseline BCVA (log MAR units) and baseline ACRT (um) and baseline SRF height (um) and between change in BCVA (log MAR) and change in both ACRT (um) and SRF height (um) after observation period and effect of age on the mean baseline SFCT (um) in both affected and fellow eyes.

	Baseline BCVA (log MAR units)	
	R	P-value
Baseline ACRT (um)	0.572	0.001*
Baseline SRF height (um)	0.533	0.002*
	Change in BVCA	
	R	P
Change in ACRT	0.786	0.001*
Change in SRF height	0.633	0.001*
	Age (years)	
	R	p. value
The mean baseline SFCT (um) (Affected eyes)	- 0.446	0.013*
The mean baseline SFCT (um) (Fellow eyes)	- 0.426	0.014*

There were no statistically significant differences in the mean baseline VAD (%) of the SCP between affected eyes, fellow eyes and control eyes (P-value 0.383). Also, there were no statistically significant differences in the mean baseline VAD (%) of the DCP between affected eyes, fellow eyes and control eyes (P-value 0.839). The mean baseline VAD (%) of the CC is statistically significant lower than that of the fellow eyes (P-value 0.001*) and that of control eyes (P-value 0.005*), meanwhile, there was no statistically significant difference between fellow eyes and control eyes (P-value 0.330). The previous table demonstrated that there were no statistically significant differences in the mean baseline FAZ area (mm²) of the SCP (FAZ-SCP) between affected eyes, fellow eyes and control eyes (P-value 0.760). Also, there were no statistically significant differences in the mean baseline FAZ area (mm²) of the DCP (FAZ-DCP) between affected eyes, fellow eyes and control eyes (P-value 0.679).

Table 5: Swept Source SS-OCT Angiography baseline data of the vessel area density (VAD) and foveal avascular zone surface area (mm²) (FAZ) (%) of SCP, DCP and CC in the affected eyes, fellow eyes and control group.

Baseline VAD (%)		Range	Mean ± S. D	p. value		
SCP	Affected	35.4 – 46	39.16 ± 2.50	0.383	P1	0.189
	Fellow	35.9 – 47.6	38.35 ± 2.44		P2	0.302
	Control	35.7 – 43.5	38.53 ± 2.10		P3	0.776
DCP	Affected	36.7 – 41.6	38.89 ± 1.56	0.839	P1	0.872
	Fellow	36.5 – 41.5	38.83 ± 1.51		P2	0.567
	Control	35.9 – 41.6	38.66 ± 1.70		P3	0.680
CC	Affected	40.9 – 49.8	46.95 ± 2.13	0.001*	P1	0.001*
	Fellow	45.7 – 52.7	48.54 ± 1.33		P2	0.005*
	Control	45.4 – 50.4	48.14 ± 1.20		P3	0.330
Baseline FAZ surface area (mm ²)		Range	Mean ± S. D	P-value		
FAZ-SCP	Affected	0.19 – 0.43	0.31 ± 0.07	0.760	P1	0.462
	Fellow	0.18 – 0.43	0.30 ± 0.07		P2	0.752
	Control	0.2 – 0.4	0.31 ± 0.05		P3	0.674
FAZ-DCP	Affected	0.33 – 0.62	0.46 ± 0.08	0.679	P1	0.848
	Fellow	0.34 – 0.6	0.46 ± 0.07		P2	0.518
	Control	0.34 – 0.58	0.45 ± 0.07		P3	0.402

P1, p. value between affected and fellow groups. *P2*, p. value between affected and control groups. *P3*, p. value between fellow and control groups.

There was no statistically significant difference between the two groups regarding baseline SS-OCT Angiography data. The previous table demonstrated no statistically significant change occurred in the **affected** eyes regarding VAD of the SCP, DCP and CC at the end of observation period. The previous table demonstrated no statistically significant change occurred in the **fellow** eyes regarding VAD of the SCP, DCP and CC at the end of observation period. **Table 6**

Table 6: SS-OCT Angiography data in "Improvement" and "No improvement" groups.

		Improvement (n=22 cases)		No Improvement (n=8 cases)		p. value
VAD-CC %	Baseline	46.60	± 2.21	47.89	± 1.66	0.148
	After 3 M.	47.48	± 1.84	47.94	± 1.46	0.529
VAD-SCP %	Baseline	38.64	± 2.17	40.58	± 2.94	0.059
	After 3 M.	38.50	± 1.82	39.91	± 1.56	0.061
VAD-DCP %	Baseline	38.76	± 1.54	39.26	± 1.63	0.443
	After 3 M.	38.70	± 1.50	39.31	± 1.48	0.328
FAZ-SCP (mm ²)	Baseline	0.31	± 0.07	0.31	± 0.08	0.997
	After 3 M.	0.30	± 0.06	0.32	± 0.08	0.617
FAZ-DCP (mm ²)	Baseline	0.45	± 0.07	0.47	± 0.11	0.594
	After 3 M.	0.46	± 0.07	0.46	± 0.11	0.770
Affected eyes		Range		Mean ± S. D	t. test	P- value
VAD-SCP (%)	Baseline	35.4	- 46	39.16 ± 2.50	0.500	0.619
	After 3 M.	35.6	- 42.2	38.87 ± 1.84		
VAD-DCP (%)	Baseline	36.7	- 41.6	38.89 ± 1.56	0.076	0.939
	After 3 M.	36.6	- 41.3	38.86 ± 1.49		
VAD-CC (%)	Baseline	40.9	- 49.8	46.95 ± 2.13	1.303	0.198
	After 3 M.	43.9	- 50	47.60 ± 1.73		
Fellow eyes		Range		Mean ± S. D	t. test	P- value
VAD-SCP (%)	Baseline	35.9	- 47.6	38.35 ± 2.44	0.728	0.469
	After 3 M.	35.8	- 42.9	38.77 ± 1.93		
VAD-DCP (%)	Baseline	36.5	- 41.5	38.83 ± 1.51	0.078	0.938
	After 3 M.	36.6	- 41.3	38.80 ± 1.48		
VAD-CC (%)	Baseline	45.7	- 52.7	48.54 ± 1.33	0.572	0.569
	After 3 M.	45	- 52.1	48.74 ± 1.33		

VAD; vessel area density. FAZ, foveal avascular zone. SCP, superficial capillary plexus. DCP; deep capillary plexus. CC; choriocapillaris.

The correlations between baseline BCVA and VAD of SCP, DCP and CC were negative and not significant (P-value 0.369, 0.439 and 0.268 respectively).

The correlations between baseline BCVA and FAZ area of SCP and DCP were positive and not significant (P-value 0.956 and 0.495 respectively). **Table 7**

Table 7: Correlations between the mean baseline OCTA data and the mean baseline BCVA.

Baseline OCTA data	Baseline BCVA	
	R	P
VAD-SCP (%)	-0.170	0.369
VAD-DCP (%)	-0.147	0.439

VAD-CC (%)	-0.209	0.268
FAZ-SCP (mm²)	0.011	0.956
FAZ-DCP (mm²)	0.130	0.495

A multiple regression analysis was carried out to investigate different factors that could significantly predict resolution of acute CSC. The results of Univariate regression indicated that the age (p. value 0.038*), baseline BCVA (p. value 0.005*) and H. pylori antibodies (p. value 0.001*) were significant predictors of resolution in this study. While in Multivariate regression, the results indicated that baseline BCVA (p. value 0.037*) and H. pylori antibodies (p. value 0.018*) were significant predictors of resolution in this study. **Table 8**

Table 8: Multiple regression analysis of different possible predictive factors associated with resolution of acute serous chorioretinopathy.

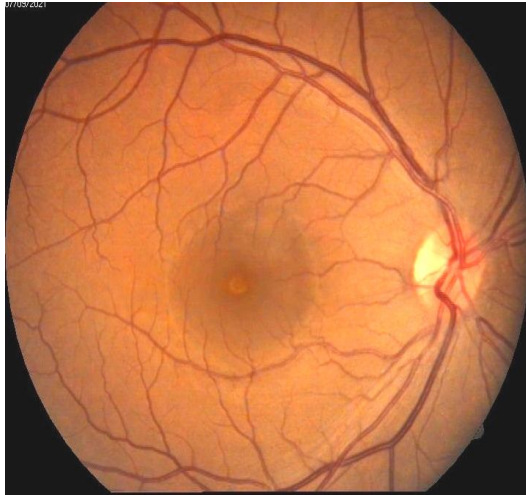
	Univariate		Multivariate	
	OR (95% CI)	P value	OR (95% CI)	P value
Age	1.521 (1.124 – 2.635)	0.038*	2.514 (0.597 – 5.632)	0.138
Baseline BCVA	0.624 (0.241 – 0.754)	0.005*	0.751 (0.524 – 0.867)	0.037*
Baseline ACRT	0.834 (0.348 – 2.516)	0.169		
Baseline SRF height	0.715 (0.547 – 1.854)	0.102		
Baseline SFCT	0.468 (0.304 – 2.054)	0.137		
Baseline VAD-CC	1.521 (0.635 – 2.367)	0.193		
Baseline VAD-SCP	2.634 (0.748 – 5.631)	0.097		
Sex	1.974 (0.637 – 3.527)	0.207		
H. pylori	1.824 (1.068 – 3.205)	0.001*	1.632 (1.149 – 3.149)	0.018*
SRF clarity	2.374 (1.157 – 4.215)	0.117		

BCVA; best corrected visual acuity. **ACRT**; automated central retinal thickness. **SRF**; subretinal fluid. **SFCT**; subfoveal choroidal thickness. **VAD**; vessel area density. **CC**; choriocapillaris. **SCP**; superficial capillary plexus. **H. pylori**; helicobacter pylori.

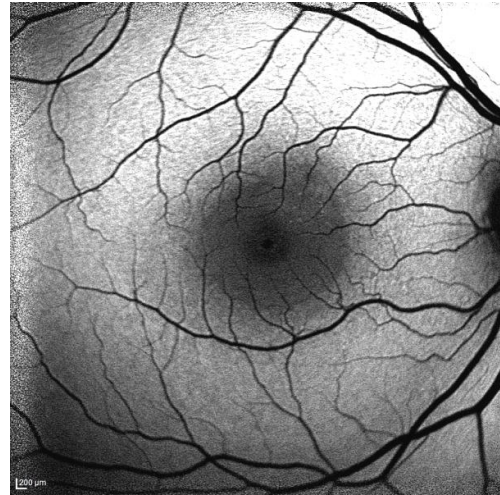
Cases:

A male farmer aged 42 years, known to be smoker for more than 10 years, complained of blurring of vision in his right eye since 2 weeks. His baseline BCVA (log MAR) was 0.3, serum cortisol level at the morning was 11 mcg/dL and at night was 6.5 mcg/dL, negatively tested for H. pylori antibodies in the stool. By clinical examination and investigation, he

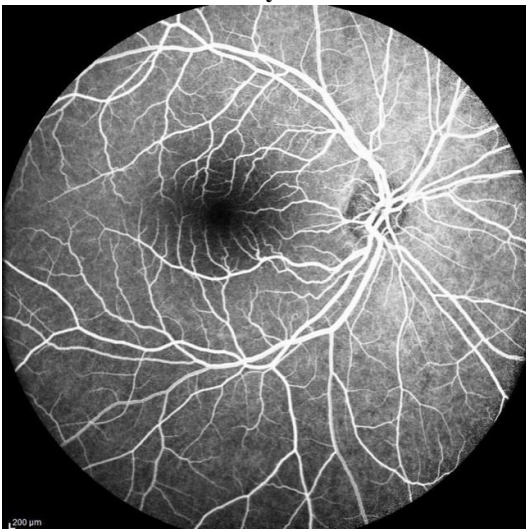
was diagnosed as acute CSC and was observed for 3 months waiting for spontaneous resolution. After observation period, the subfoveal SRF height decreased by 57.7% of its baseline value with improvement of BCVA (logMAR) to 0 (6/6).



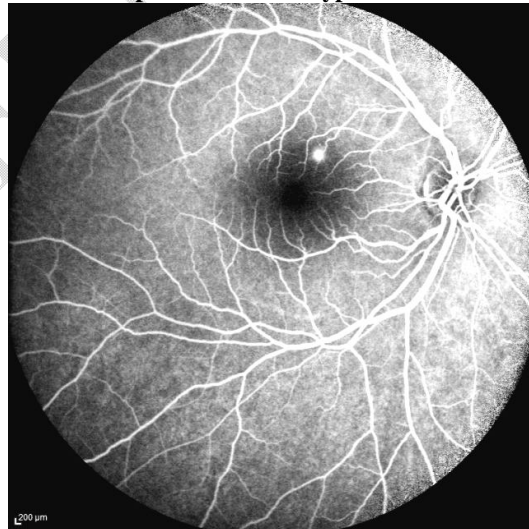
Color fundus photo showing blister-like macular neuro-sensory detachment



FAF showing diminished macular AF associated with presence of fine hyper AF dots

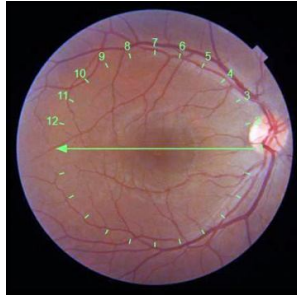


Early phase of FFA showing leaking point at the level of RPE superior to the fovea

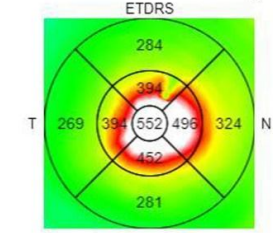


Late phase of FFA showing ink-blot pattern of leakage superior to the fovea

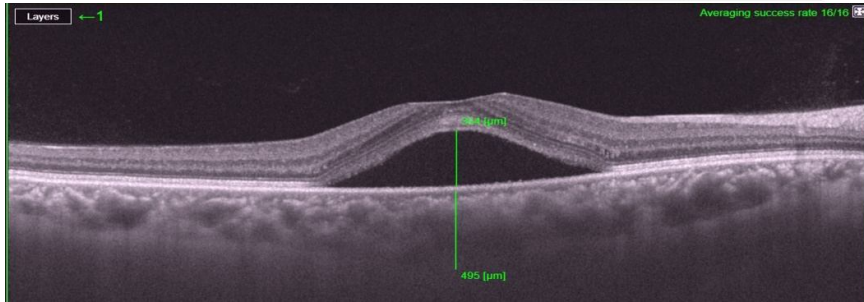
Figure 1. Baseline multimodal images



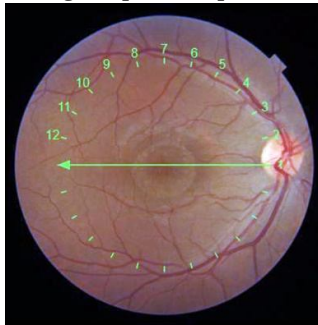Retinal thickness ILM-OS/RPE(μm)



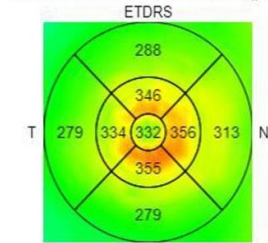
Average Thickness (μm) 328.9



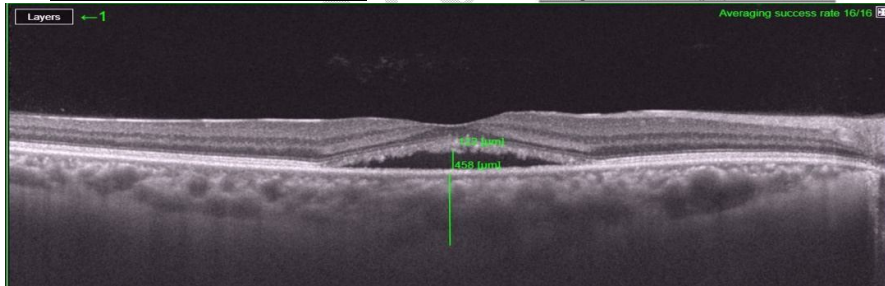
Baseline OCT image (scan 1) showing; SRF height = 354 μm, intact ELM, clear SRF, SFCT = 495 μm, elongated photoreceptors outer segment, choroidal thickening and pachyvessels are seen



Retinal thickness ILM-OS/RPE(μm)

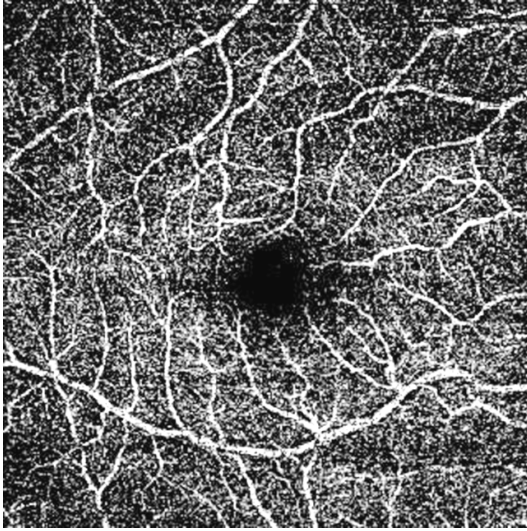


Average Thickness (μm) 304.0

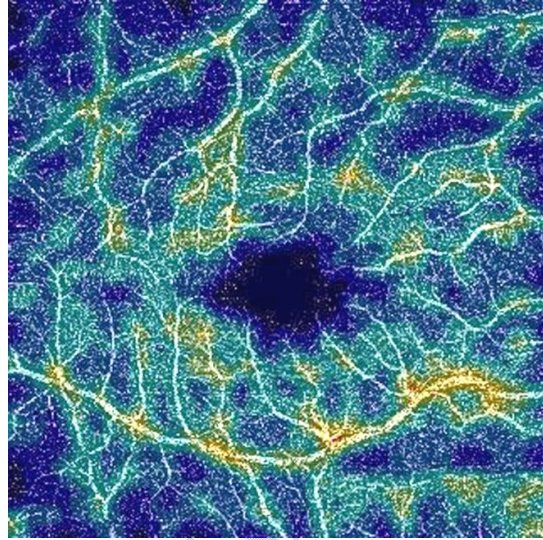


Final OCT image (scan 1) showing; SRF height = 122 μm, intact ELM, clear SRF, SFCT = 458 μm, elongated photoreceptors outer segment, choroidal thickening and pachyvessels are seen


Figure 2. Baseline & follow up OCT images



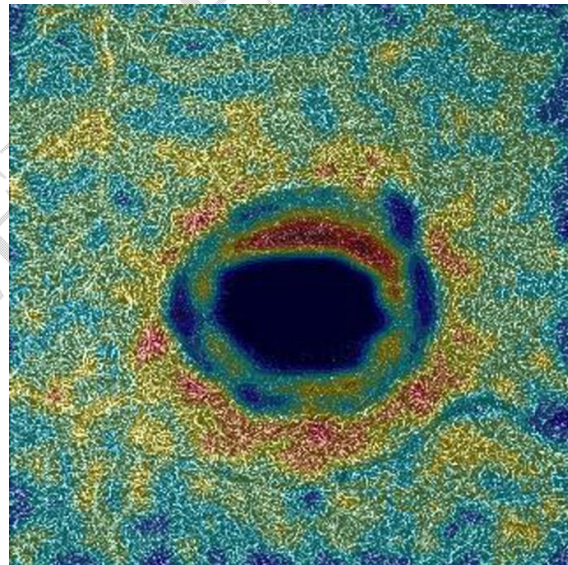
OCTA 6x6 mm – SCP (Grayscale image)




**OCTA 6x6 mm – SCP (density map)
VAD = 35.70% & FAZ = 0.324 mm²**




OCTA 6x6 mm – DCP (Grayscale image)



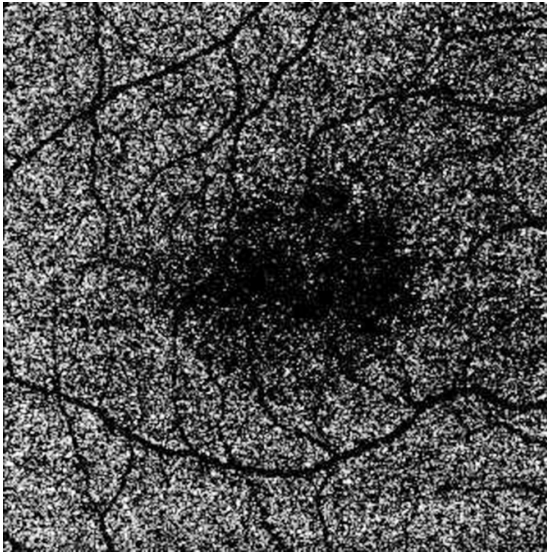
**OCTA 6x6 mm – DCP (density map)
VAD = 37.60% & FAZ = 0.502 mm²**



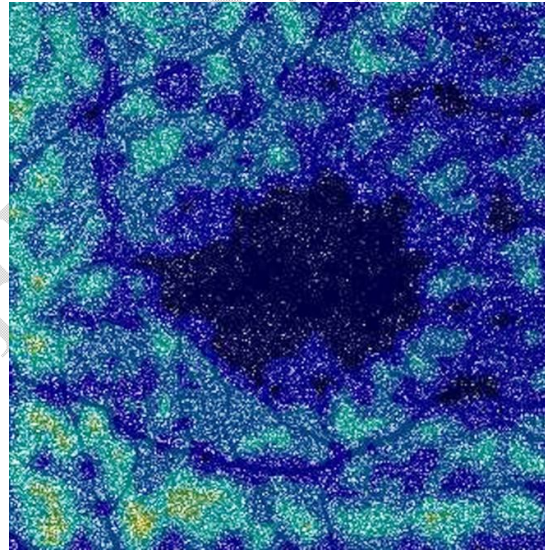
OCTA 6x6 mm – Outer retina (Grayscale image); note the central masking effect of the SRF



OCTA 6x6 mm – Outer retina (density map); note the central masking effect of the SRF



OCTA 6x6 mm – CC (Grayscale image); note the central masking effect of the SRF and scattered dark spots



OCTA 6x6 mm – CC (density map); note the central masking effect of the SRF and scattered dark spots
VAD = 40.90%

Figure 3. Baseline OCT Angiography

Discussion

Among the nonsurgical retinal illnesses, CSC is the fourth most frequent, behind AMD, diabetic retinopathy, and branch retinal vein occlusion ^[2]. CSC is characterized by serous retinal detachment with or without pigment epithelial detachment and considered one of pachychoroid disorders ^[1].

We conducted a prospective study to evaluate the factors associated with resolution of acute CSC cases and included 30 eyes of 30 patients fulfilling the inclusion criteria.

There was a statistically significant difference between "Improvement" and "No improvement" groups regarding the result of screening test for H. pylori antibodies in the stool (P-value 0.001*). *Rahbani-Nobar et al.*,^[6] conducted a randomized, controlled trial comparing treatment using triple therapy versus observation for acute CSC patients with proven infection with H.pylori that concluded faster resolution in the treatment group and the difference in the time needed for complete fluid resolution was statistically significant (9.3 versus 11.6 weeks, p=0.015*) but without visual acuity benefit.

Our findings revealed that, there was no statistically significant difference between two groups regarding the mean serum cortisol level at morning or at night (P-value 0.820 and 0.418 respectively). In agreement with that, *Chalisgaonkar et al.*,^[7] , *Tufan et al.*,^[8] and *Tanie et al.*,^[9] did not find a definite correlation of the serum cortisol level with CSC

On the other hand, *Garg et al.*,^[10] and *Kapetaniotis et al.*,^[11] compared serum and urine levels of endogenous cortisol for patients suffering from acute CSC with those of age and sex matched control group and found a significant difference. Also, *Zakir et al.*,^[12] reported that CSC is associated with elevated morning serum cortisol levels.

Measurement of BCVA was done using Snellen visual acuity chart and acuities were converted to log MAR for statistical analysis. Our findings revealed that there was an improvement of the mean final BCVA when compared to the baseline value.

These findings agree with nature of acute CSC which is usually a self-limiting condition and recovery of the visual acuity typically occurs within four months associating the SRF resolution as what was concluded by *Mudvari SS. Et al.*,^[13] and *Yannuzzi LA.*,^[14]

No statistically significant difference seen between "Improvement" and "No Improvement" groups regarding FFA pattern (P-value 0.571) was found in our study.

According to *Shahin MM.*,^[15], 53% of eyes in the study showed the ink-blot leakage pattern in FFA, 79% of eyes showed macular leakage sites while the remaining 21% of eyes were divided between peripheral and peripapillary sites.

Spitznas M. et al.,^[16] and *How AC. Et al.*,^[17] in their studies had reported a relatively more common incidence of ink-blot pattern than smoke-stack one ranging from 80-93%. This difference can be explained by different environmental factors, ethnic group variation or age of the studied sample.

Regarding fundus auto-fluorescence (FAF) patterns of the macular areas of the studied eyes, Average AF (16.6%) can be explained in early cases where the RPE cells are still completely intact or small amount of SRF not enough to produce a significant masking effect. *Peng Zhang et al.*,^[18] observed that 6.64% of eyes in the study had average AF in the area of serous retinal detachment.

The mean final vertical SRF dimension (VD) was lower than baseline one and the difference was statistically significant (P-value 0.012*). The mean final horizontal SRF dimension (HD) was lower than baseline one and the difference was statistically significant (P-value 0.022*). The mean final SRF height was lower than baseline one and the difference was statistically significant (P-value 0.002*).

Tom OAR et al.,^[19] in their study done in Rotterdam, The Netherlands found that the mean CFT was significantly reduced after 3 months in both study groups either observation one or that group received PDT therapy.

The results revealed thicker choroid in the affected eyes and their fellows when compared to the control group. the mean SFCT is higher in the affected and fellow eyes than control and the differences were statistically significant between the affected eyes and control (P-value 0.001* for both).

In agreement with that, *Imamura et al.*,^[20] *Yang et al.*,^[21] and *Goktas A.*,^[22] reported thicker choroid in the affected and fellow eyes in comparison to healthy people.

There was a significant negative correlation between the baseline SFCT of the affected (P-value 0.013*) and fellow (0.014*) eyes and the age of the patient. This means, the higher the age, the lower the SFCT. *Hao Zhou et al.*,^[23] agreed with these data and reported a significant decrease of choroidal thickness with age.

On the other hand, *Karahan et al.*,^[24] disagreed with that and concluded that age and spherical equivalent were not significantly correlated with choroidal thickness.

No statistically significant difference between "Improvement" and "No improvement" groups regarding SRF clarity. This may be due to large difference between number of eyes with clear SRF and those with turbid SRF (25 versus 5) (P-value 0.140). There was no statistically significant relationship between possibility of improvement and presence or absence of RPE changes (P-value 0.536).

Ahlers et al.^[22], and *Yang et al.*,^[21] reported 53-100 % overall incidence of PEDs in CSC cases in general with more frequency in chronic type either inside or outside the SRF area.

The mean baseline VAD (in %) in the SCP (VAD-SCP) was measured in the **affected** eyes, **fellow** eyes and eyes of **control** group; with no statistically significant difference between the three groups (P-value 0.383). The mean baseline VAD (in %) in the DCP (VAD-DCP) was measured in the **affected** eyes, **fellow** eyes and eyes of **control** group; with no statistically significant difference between the three groups (P-value 0.839). The mean baseline VAD (in %) in the CC (VAD-CC) was measured in the **affected** eyes, **fellow** eyes and eyes of **control** group; the VAD-CC in the affected eye is statistically significant less than the fellow eye (P-value 0.001*) and the control group (P-value 0.005*) while there was no statistically significant difference between the fellow eyes and the control group (P-value 0.330).

In agreement with that, *Cakir et al.*,^[25] , *Wang et al.*,^[26] , *Han et al.*,^[27] and *Lu et al.*,^[28] concluded that the vessel density of superficial CC was significantly lower in eyes with acute CSC than in fellow eyes and in age and refractive error matched normal eyes.

On the other hand, *Nicolo et al.*,^[29] disagreed with findings of our study and reported that overall choroidal vascular flow and vascular flow in the CC layer are significantly higher in eyes with CSC than in control eyes.

The improvement is more associated with lower baseline VAD of SCP, DCP and CC.

The mean baseline FAZ area (in mm²) in SCP (FAZ-SCP) was measured in the **affected** eyes, **fellow** eyes and eyes of **control** group; with no statistically significant difference between the three groups (P-value 0.760).

Also, the mean baseline FAZ area (in mm²) in DCP (FAZ-DCP) was measured in the **affected** eyes, **fellow** eyes and eyes of **control** group; with no statistically significant difference between the three groups (P-value 0.679).

These findings agree with *Han et al.*,^[27] who reported no statistically significant difference in FAZ-SCP and FAZ-DCP between affected, fellow and control eyes.

Lower vessel density of SCP, DCP or CC decreases are associated with better vision, but this correlation lacks significance.

In other words, smaller FAZ-SCP and FAZ-DCP are associated with better vision, but this correlations lack significance.

Han et al.,^[27] agreed with these findings and concluded that FAZ areas and VADs of both the SCP and DCP had no correlation with BCVA in the eyes with CSC after complete SRF resolution.

Conclusions:

Proper assessment of systemic factors associated with CSC and ocular factors using multimodal ocular imaging help us in predicting the course and visual prognosis of CSC

cases. We depended on evaluating the difference of all variables between the "improvement group, n=22 cases" (decreased SRF height after 3 months) and "no improvement group, n=8 cases" (persistent/increased SRF height after 3 months).

References:

1. van Rijssen TJ, van Dijk EHC, Yzer S, Ohno-Matsui K, Keunen JEE, Schlingemann RO, et al. Central serous chorioretinopathy: Towards an evidence-based treatment guideline. *Prog Retin Eye Res.* 2019;73:100770.
2. Fine HF, Ober MD, Hariprasad SM. Current concepts in managing central serous chorioretinopathy. *Ophthalmic Surg Lasers Imaging Retina.* 2014;45:9-13.
3. Maranduca MA, Branisteanu D, Serban DN, Branisteanu DC, Stoleriu G, Manolache N, et al. Synthesis and physiological implications of melanic pigments. *Oncol Lett.* 2019;17:4183-7.
4. Lee WK, Baek J, Dansingani KK, Lee JH, Freund KB. Choroidal morphology in eyes with polypoidal choroidal vasculopathy and normal or subnormal subfoveal choroidal thickness. *Retina (Philadelphia, Pa).* 2016;36 Suppl 1:S73-S82.
5. Mrejen S, Spaide RF. Optical coherence tomography: imaging of the choroid and beyond. *Surv Ophthalmol.* 2013;58:387-429.
6. Rahbani-Nobar MB, Javadzadeh A, Ghojzadeh L, Rafeey M, Ghorbanihaghjo A. The effect of *Helicobacter pylori* treatment on remission of idiopathic central serous chorioretinopathy. *Mol Vis.* 2011;17:99-103.
7. Chalisgaonkar C, Chouhan S, Lakhtakia S, Choudhary P, Dwivedi PC, Rathore MK. Central serous chorioretinopathy and endogenous cortisol - is there an association? *Indian J Ophthalmol.* 2010;58:449-50; author reply 50.
8. Tufan HA, Gencer B, Comez AT. Serum cortisol and testosterone levels in chronic central serous chorioretinopathy. *Graefes Arch Clin Exp Ophthalmol.* 2013;251:677-80.

9. Natung T, Keditsu A. Comparison of Serum Cortisol and Testosterone Levels in Acute and Chronic Central Serous Chorioretinopathy. *Korean J Ophthalmol.* 2015;29:382-8.
10. Garg SP, Dada T, Talwar D, Biswas NR. Endogenous cortisol profile in patients with central serous chorioretinopathy. *Br J Ophthalmol.* 1997;81:962-4.
11. Kapetanios AD, Donati G, Bouzas E, Mastorakos G, Pournaras CJ. [Serous central chorioretinopathy and endogenous hypercortisolemia]. *Klin Monbl Augenheilkd.* 1998;212:343-4.
12. Zakir SM, Shukla M, Simi ZU, Ahmad J, Sajid M. Serum cortisol and testosterone levels in idiopathic central serous chorioretinopathy. *Indian J Ophthalmol.* 2009;57:419-22.
13. Mudvari SS, Goff MJ, Fu AD, McDonald HR, Johnson RN, Ai E, et al. The natural history of pigment epithelial detachment associated with central serous chorioretinopathy. *Retina.* 2007;27:1168-73.
14. Yannuzzi LA. Central serous chorioretinopathy: a personal perspective. *Am J Ophthalmol.* 2010;149:361-3.
15. Shahin MM. Angiographic characteristics of central serous chorioretinopathy in an Egyptian population. *Int J Ophthalmol.* 2013;6:342-5.
16. Spitznas M, Huke J. Number, shape, and topography of leakage points in acute type I central serous retinopathy. *Graefes Arch Clin Exp Ophthalmol.* 1987;225:437-40.
17. How AC, Koh AH. Angiographic characteristics of acute central serous chorioretinopathy in an Asian population. *Ann Acad Med Singap.* 2006;35:77-9.
18. Zhang P, Wang HY, Zhang ZF, Sun DJ, Zhu JT, Li J, et al. Fundus autofluorescence in central serous chorioretinopathy: association with spectral-domain optical coherence tomography and fluorescein angiography. *Int J Ophthalmol.* 2015;8:1003-7.
19. Missotten TO, Hoddenbach JG, Eenhorst CA, van den Born LI, Martinez Ciriano JP, Wubbels RJ. A randomized clinical trial comparing prompt photodynamic therapy with 3

- months observation in patients with acute central serous chorioretinopathy with central macular leakage. *Eur J Ophthalmol.* 2021;31:1248-53.
20. Imamura Y, Fujiwara T, Margolis R, Spaide RF. Enhanced depth imaging optical coherence tomography of the choroid in central serous chorioretinopathy. *Retina.* 2009;29:1469-73.
21. Yang L, Jonas JB, Wei W. Optical coherence tomography-assisted enhanced depth imaging of central serous chorioretinopathy. *Invest Ophthalmol Vis Sci.* 2013;54:4659-65.
22. Goktas A. Correlation of subretinal fluid volume with choroidal thickness and macular volume in acute central serous chorioretinopathy. *Eye (Lond).* 2014;28:1431-6.
23. Zhou H, Dai Y, Shi Y, Russell JF, Lyu C, Noorikolouri J, et al. Age-Related Changes in Choroidal Thickness and the Volume of Vessels and Stroma Using Swept-Source OCT and Fully Automated Algorithms. *Ophthalmol Retina.* 2020;4:204-15.
24. Karahan E, Zengin MO, Aydin R, Ozturk T, Kaya M, Kocak N, et al. Correlation of choroidal thickness with serum cortisol level. *Clin Exp Optom.* 2015;98:362-5.
25. Cakir B, Reich M, Lang S, Bühler A, Ehlken C, Grundel B, et al. OCT Angiography of the Choriocapillaris in Central Serous Chorioretinopathy: A Quantitative Subgroup Analysis. *Ophthalmol Ther.* 2019;8:75-86.
26. Wang Z, Xin Z, Yang J, Lu H, Wang H, Zhu L. Choriocapillaris Ischemia at the Leakage Point of Patients With Acute Central Serous Chorioretinopathy. *Frontiers in Medicine.* 2021;8.
27. Han KJ, Kim HJ, Woo JM, Min JK. Comparison of Retinal Layer Thickness and Capillary Vessel Density in the Patients with Spontaneously Resolved Acute Central Serous Chorioretinopathy. *J Clin Med.* 2020;10.

28. Lu H, Wang Z, Xin Z, Yang J. To evaluate the microcirculation of retinochoroid capillary between acute and chronic central serous chorioretinopathy with OCTA. *Medicine (Baltimore)*. 2021;100:e27069.

29. Nicolò M, Rosa R, Musetti D, Musolino M, Saccheggiani M, Traverso CE. Choroidal Vascular Flow Area in Central Serous Chorioretinopathy Using Swept-Source Optical Coherence Tomography Angiography. *Investigative Ophthalmology & Visual Science*. 2017;58:2002-10.

UNDER PEER REVIEW