

Short communication

Cryptococcus laurentii Fungaemia in a Neonate from Nigeria: A Case Report

Abstract

Aim: *Cryptococcus laurentii* is a non-neoformans *Cryptococcus* species previously considered to be non-pathogenic to humans. However, increasing cases of *Cryptococcus laurentii* infection are being reported globally possibly due to advances in medicine. **the use of immunosuppressants and invasive therapies such as endotracheal intubation,** parenteral nutrition, central vascular catheters and exposure to broad-spectrum antimicrobial agents. Four cases of *Cryptococcus laurentii* fungemia have been described in neonates, all were premature low/very low-birth-weight. Our case is likely the **5th** reported globally and the 1st from Nigeria and Africa across all age groups.

Comment [N1]: and in...

Case presentation: The patient presented at 34 hours of life with complaints of fever and multiple convulsions after delivery in a traditional birth attendant facility. Mother drained liquor for 5 days with poor cord care. A diagnosis of severe birth asphyxia with sepsis was made and baby received antibiotics (ceftriaxone and gentamicin) in addition to the management of severe birth asphyxia but showed no improvement. Blood culture yielded cream-colored smooth colonies, identified by Vitek 2 (bioMerieux, France) as *Cryptococcus laurentii*. **Baby was commenced on** fluconazole, had good recovery and was discharged home.

Comment [N2]: there are more than 15 cases reported in humans globally...read Ming-Fang Cheng et al., 2001

Conclusion: Our case report emphasizes the need for high index of suspicion for non bacterial organisms(fungi) as a possible cause of sepsis in newborns. Improved fungal diagnosis and timely commencement of antifungal drugs will improve clinical outcomes.

Comment [N3]: rephrase this

Keywords: *Cryptococcus laurentii*; Fungaemia; Neonates; Sepsis

Introduction

Cryptococcus (C.) laurentii is a rare non-neoformans *Cryptococcus* specie that cause human infections [1]. The clinical presentation of *C. laurentii* is similar to that of *C. neoformans*, but the cryptococcal antigen test is often negative [1]. *C. laurentii* infections have been reported in both the immunocompromised and the immunocompetent, though more common in the immunocompromised [2-6]. Although, previously considered saprophytic and nonpathogenic to humans, *C. laurentii* has been reported to cause central nervous system, bloodstream and pulmonary infections, and infections in other body sites [6]. Globally, few cases of *C. laurentii* fungaemia have been reported in neonates [2-5] but non from Nigeria. We report a case of *Cryptococcus laurentii* fungaemia in neonate at 34 hours of life.

Case Report

A neonate delivered at home with poor cry and presented at our facility, the University of Calabar Teaching Hospital (UCTH), Calabar, at age of 34 hours of life with complaints of fever and multiple convulsions. The baby had weak suck and the fever was high and continuous. Convulsions were tonic-clonic in nature lasting 2 to 3 minutes, and aborted spontaneously. Pregnancy was booked in a Primary Healthcare Centre (PHC) at gestational age (GA) of 20 weeks and was uneventful until GA of 32 weeks when mother had a febrile illness and was treated at the same PHC. Mother screened negative for hepatitis B surface antigen and human immunodeficiency virus. Syphilis test was not done. Her genotype and blood group are not known. She received two doses of tetanus toxoid and intermittent preventive treatment malaria prophylaxis twice. Baby was delivered in a Traditional Birth Attendant (TBA) facility, at 41 weeks. Apgar score was not recorded. Labour lasted for 5 days with multiple vaginal examinations. He had weak cry at birth but later cried well, drained liquor for 5 days and cord care was done with sand mixed with olive oil.

On examination, baby was acutely ill, febrile (39.5⁰C), tachypneic (respiratory rate of 74 cycles/min), dyspneic with intercostal and subcostal recessions, mildly icteric, not pale, no cyanosis, with tachycardia (heart rate of 170 beats/min), not dehydrated, SPO₂ 58% in room air, but 97% on O₂ flowing at 1-2L/min. His weight was 3.2kg, length 50.3cm and occipito-frontal circumference of 34.4cm. Abdominal examination showed dirty umbilical cord filled with sand, hyperaemic base with purulent discharge. Neurological examination showed depressed primitive reflexes. Urogenital examination showed external male genitalia and stretched penile length of 3.5cm. The

respiratory and cardiovascular system examinations were unremarkable. A diagnosis of Severe Birth Asphyxia with neonatal sepsis was made.

Baby was admitted into the newborn unit and managed accordingly with Oxygen via nasal prongs given at 1.5L/minute, intravenous fluid 8% dextrose in one-fifth saline maintenance, IM phenobarbitone, IM vitamin K 1mg stat and antibiotics (ceftriaxone and gentamicin). A seizure chart was kept to monitor seizure frequency and duration. Fluid intake and output was monitored as well as the vital signs.

Random blood glucose and E/U/Cr remained normal except metabolic acidosis, (bicarbonate 16mm/L (20-25), and hypocalcaemia (calcium levels was 2.0mm/L (2.2-2.6) which were corrected. Cerebrospinal fluid chemistry result was essentially normal and no pathogen was isolated on culture. Full blood count on 3rd day of life showed; packed cell volume 55%, white blood cell counts $6.3 \times 10^9/L$, haemoglobin 18.7g/dL, neutrophils 68%, lymphocytes 32%, eosinophils 0%, basophils 0%, monocytes 0% and platelets $43,000/\mu L$ (150,000-450,000). The reversal of neutrophils/lymphocyte percentages and presence of thrombocytopenia are in keeping with sepsis. Malaria parasites were seen in blood film and baby was treated with dihydroartemisinin piperaquine. Chest X-ray was not done due to family's financial constraints as a result of out-of-pocket health financing. Blood culture retrieved on day 9 yielded white-cream, smooth, discrete colonies, seen as large budding spherical / elongated yeast cells on microscopy and identified using Vitek 2 automated microbial identification system (bioMérieux, France) as *Cryptococcus laurentii*.

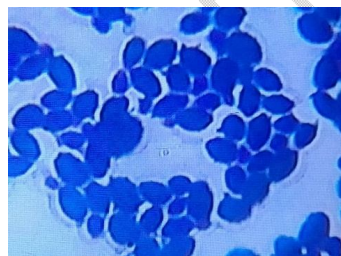


Figure 1. Budding encapsulated spherical and ellipsoidal yeast cells of *C. laurentii* from blood specimen on Gram stain

Diagnosis was changed to *Cryptococcal septicaemia*. Fluconazole suspension 6mg/kg stat, then 3mg/kg daily was commenced while antibiotics was stopped. Baby improved after two days of antifungals administration with reduction in temperature, improved activity and presence of sucking reflex. Baby was discharged home on the 11th

Comment [N4]: write the full meaning at first usage

day of admission to be followed up in the neonatal outpatient clinic. He made three visits to the outpatient newborn clinic and completed fluconazole suspension for seven weeks. She is fine and growing well as of last visit.

Discussion

C. laurentii is a non-neoformans *Cryptococcus* species previously considered to be non-pathogenic to humans [3]. However, increasing cases of *C. laurentii* infection are being reported globally possibly due to advances in medicine, the use of immunosuppressants and invasive therapies such as endotracheal intubation, parenteral nutrition, central vascular catheters and exposure to broad-spectrum antimicrobial agents. Literature review revealed four documented cases of *C. laurentii* fungemia in neonates, all were premature low/very low-birth-weight [2-6]. Our case is the 5th reported globally and first from Africa and Nigeria. The first case of *C. laurentii* fungaemia in a neonate was reported in 1997 in a 27-day old male premature with hypoplastic lungs and bilateral hydronephrosis secondary to posterior urethral valves. He was on mechanical ventilation and had central venous and urinary catheters in place as part of his management regimen. He improved with amphotericin B and flucytosine and was slowly weaned off ventilatory support and was discharged home [5]. The summary of *C. laurentii* fungaemia reported in neonates is as shown in table 1.

Comment [N5]: reflect on my earlier comment

Table 1. Clinical summary of *C. laurentii* fungaemia in neonates

Authors	Sex/Location	Underlying factors /Risk factors	Method of diagnosis	Treatment	Outcome
John LB et. al. 1998 [5]	M/USA	Hypoplastic lungs, bilateral hydronephrosis, posterior urethral valves, mechanical ventilation, central venous and urinary catheters	Blood culture, biochemical tests	AmB, Flucytosine	F
Cheng et. al. 2001 [3]	F/Taiwan	Extremely low birth weight, respiratory distress, antibiotic exposure, central venous line	Blood culture, ID 32C	AmB	F
Gupta et. al. 2018 [2]	M/India	Low birth weight, fetal distress, respiratory distress, intubation	Blood culture, Vitek 2, MALDI-TOF	Liposomal AmB	F
Al-Otaibi et. al. 2021 [4]	F/Kuwait	Very low birth weight, respiratory distress syndrome, antibiotic exposure, intubation	Blood culture, Vitek 2, PCR- sequencing	Liposomal AmB	F
This study	M/Nigeria	Contaminated umbilical cord	Blood culture, Vitek 2	Fluconazole	F

M: Male, F: Female, F: Favourable, AmB: Amphotericin B, MALDI-TOF: matrix-assisted laser desorption ionization time-of-flight mass spectrometry

Cryptococcus albidus and *C. laurentii* account for 80% of non-neoformans cryptococcal pathogenic infections [7]. *Cryptococcus* species are ubiquitously distributed in the environment, and most abundant in the droppings of pigeons and other birds. Infections primarily occurs by inhalation of infective particles due to close contact with pigeons or contaminated soil. Direct entry through the digestive tract or skin can also occur [3,8]. Our case must

have acquired *C. laurentii* due to cord care done with sand mixed with olive oil following delivery in a TBA facility as previously narrated. Activities leading to skin damage or bridge in mucosal surfaces including trauma, penetrating injuries, prior operative procedures and the use of invasive devices have been reported to predispose to *C. laurentii* infection [2-5,9]. In addition, extremes of age have also been attributed as a risk factor for fungal infections. Our index case was 34 hours old which is an immunocompromised state due to incompletely developed immune system [2-5]. Compared with previously reported cases of neonatal *C. laurentii* which were preterm low/very low birth weight preterm, our index case was a term baby. Two previously described cases of *C. laurentii* were treated with liposomal amphotericin B, one received amphotericin B, while the other received amphotericin B with flucytosine. All had favorable outcomes [2-5], table 1. The antifungal susceptibility profile of our index case was not done. However, patient improved remarkably with fluconazole therapy with favorable outcome. Although some case studies have reported *C. laurentii* to have decreased fluconazole susceptibility [1,2,5], some reports have also demonstrated the efficacy of fluconazole in the treatment of *C. laurentii* fungaemia with favorable clinical outcomes [6].

Conclusion

Fungal infections may not be as rare as it appears in our setting. Our case report emphasizes the need for high index of suspicion for non bacterial organisms (fungi) as a possible cause of sepsis in newborns. Improved fungal diagnosis and timely commencement of antifungal drugs will improve clinical outcomes.

Ethics approval: Not applicable

References

1. Xiao M, Fan X, Chen X-X, Wang H, Zhang L, Xu Z-P, et al. Misidentification of a rare species, *Cryptococcus laurentii*, by commonly used commercial biochemical methods and matrix-assisted laser desorption ionization–time of flight mass spectrometry systems: challenges for clinical mycology laboratories. 2016. J Clin Microbiol. 54:226–229.
2. Gupta M, Mishra AK, Singh SK. *Cryptococcus laurentii* fungemia in a low birth weight preterm neonate: India. J Infect Public Health. 2018;11(6):896-897.

Comment [N6]: complete the reference

3. Cheng MF, Chiou CC, Liu YC, Wang HZ, Hsieh KS. *Cryptococcus laurentii* fungemia in a premature neonate. J Clin Microbiol. 2001;39(4):1608-11
4. Al-Otaibi H, Asadzadeh M, Ahmad S, Al-Sweih N, Joseph L. *Papiliotrema laurentii* fungemia in a premature, very low-birth-weight neonate in Kuwait successfully treated with liposomal amphotericin B. J Mycol Med. 2021;31(2):101123.
5. Johnson LB, Bradley SF, Kauffman CA. Fungaemia due to *Cryptococcus laurentii* and a review of non-neoformans cryptococcaemia. Mycoses. 1998;41(7-8):277-80.
6. Molina-Leyva A, Ruiz-Carrascosa JC, Leyva-Garcia A, Husein-Elahmed H. Cutaneous *Cryptococcus laurentii* infection in an immunocompetent child. Int J Infect Dis. 2013;17(12): e1232-3.
7. Khawcharoenporn T, Apisarnthanrak A, Mundy LM. Non-neoformans cryptococcal infections: a systematic review. Infection. 2007; 35:51–8.
8. Ekeng BE, Davies AA, Osaigbovo II, Warris A, Oladele RO, Denning DW. Pulmonary and Extrapulmonary Manifestations of Fungal Infections Misdiagnosed as Tuberculosis: The Need for Prompt Diagnosis and Management. J. Fungi 2022, 8, 460.
9. Banerjee P, Haider M, Trehan V, Mishra B, Thakur A, Dogra V, et. al. *Cryptococcus laurentii* fungemia. Indian J Med Microbiol. 2013;31(1):75-7