

Case study

Mature cystic teratoma of adrenal gland masquerading as myelolipoma

ABSTRACT

Introduction Extragonadal teratomas are uncommon tumors and are less common in adults than children . They are mostly retroperitoneal. Primary adrenal teratomas are even rarer.

Objective We report an unusual case of primary adrenal teratoma in a young adult.

Case Summary A 29 year old male presented with complains of intermittent right sided flank pain for 6 months , dull aching , radiating to groin. On CT Abdomen a large heterogenous mass was seen having predominantly fat component and punctate calcification in right suprarenal region. Histopathology confirmed a diagnosis of adrenal teratoma.

Conclusions Adrenal teratomas are difficult to diagnose clinically or on imaging as these mimic other lipomatous lesions. Although rare this should be considered as a differential diagnosis for adrenal tumors.

Key words: Adrenal, teratoma, lipomatous

Introduction : Teratomas are totipotent germ cell tumors which usually arise from one or all three germ cell layers i.e., ectoderm, mesoderm, and endoderm. Teratoma is a rare neoplasm with an incidence of 0.9/100,000 population.¹ Most common sites are gonads, sacrococcygeal, mediastinal, and pineal region.² Retroperitoneal teratomas account for 4% of all primary teratomas whereas adrenal teratomas are even rarer.³ Adrenal teratomas can pose a diagnostic challenge because radiologically they mimic myelolipoma, angiomyolipoma, liposarcoma and pheochromocytoma. We report an unusual case of mature teratoma in right adrenal gland in a young adult male.

Case Summary: A 29 year old male presented with complains of intermittent right sided flank pain since 6 months , dull aching , radiating to groin . There was no associated vomiting, hematuria, dysuria or no lower urinary tract symptoms. Physical examination and complete blood count were within normal limits. Serum **cortisol**, plasma **metanephrine** and urinary **VMA** level were also within normal limits. On **Ultrasonography** a well defined, heterogenous mass of size (10 x 8)cm, oval shaped was seen between right lobe of liver and right kidney having hyperechoic central component with posterior acoustic shadow was seen. On **CT Abdomen** a large heterogenous mass, measuring about (7x 8) cm was seen having predominantly fat component, soft tissue density lesion and punctate calcification in right suprarenal region suggestive of Adrenal Myelolipoma . (Fig. 1) Right sided laparoscopic adrenalectomy was done without any complications. The specimen was sent to histopathologic laboratory. On gross examination, a cystic mass measuring (10x10x5)cm with a wall thickness of 1cm was seen. External surface was congested, cut section showed thick cheesy material with hairtuft. (Fig. 2) On microscopic examination, derivatives of all three germ layers were seen. Compressed adrenal cortical tissue was seen in the cyst wall (Fig. 3) Thus a confirmatory diagnosis of mature teratoma of Adrenal gland was established.

Discussion : Gonadal teratomas are known to occur however extra gonadal teratomas are uncommon neoplasms . Adrenal teratomas form about 0.13% of all adrenal tumours.⁴ Clinically, adrenal teratomas usually occur in young women, in the right adrenal gland, and 90% are benign.⁵ Patients are mostly asymptomatic, however in our case the patient presented with right sided flank pain. Abdominal CT is the choice of imaging which usually shows well-circumscribed heterogenous masses mainly comprising of fatty component with multiple tissue types such as bone, teeth, soft tissue and fluid component. In a study by Davidson et al.⁶ comprising 21 cases, it was suggested that the presence of a heterogeneous mass containing a well-circumscribed fluid volume, fat-fluid and calcifications were the most characteristic radiologic findings on CT. These findings were consistent with our case report. Indicators for malignant transformation include significant enhancement of the cyst wall, septations as well as mural nodules and abnormal levels of hormones including cortisol, ACTH, aldosterone, and VMA.⁷ No such findings were evident in our case. Histopathology is essential for a confirmatory diagnosis of mature teratoma. Surgery is the method of choice for treatment of mature teratoma. Laparoscopic surgery is the gold standard for adrenal tumors⁸ with excellent prognosis and 5 year survival rate of 100%.

Conclusion : This case report emphasizes that adrenal teratoma should be considered as an important differential diagnosis for lipomatous lesions involving the Adrenal gland

References :

1. Taori K, Rathod J, Deshmukh A, Sheorain VS, Jawale R, Sanyal R, et al. Primary extragonadal retroperitoneal teratoma in an adult. *Br J Radiol.* 2006;79:e120–2.
2. Bedri S, Erfanian K, Schwaitzberg S, Tischler AS. Mature cystic teratoma involving adrenal gland. *EndocrPathol.* 2002;13:59–64.

3. Grosfeld J.L., Billmire D.F. Teratomas in infancy and childhood. *Curr. Probl. Cancer.* 1985;9:1–53. doi: 10.1016/S0147-0272(85)80031-3.
4. Narla SL, Jacob S, Kurian A, Parameswaran A. Primary mature cystic teratoma with carcinoid mimicking an adrenal tumor: Report of a rare association and review of literature. *Indian J PatholMicrobiol.* 2016;59:200–2.
5. Lane RH, Stephens DH, Reiman HM. Primary retroperitoneal neoplasms: CT findings in 90 cases with clinical and pathologic correlation. *AJR Am J Roentgenol* 1989;152:83–9.
6. Davidson A.J., Hartman D.S., Goldman S.M. 1989. Mature Teratoma of the Retroperitoneum: Radiologic, Pathologic, and Clinical Correlation; pp. 421–425. <https://doi.org/10.1148/Radiology.172.2.2664866>. 172.
7. Niu M, Liu A, Zhao Y, Feng L. Malignant transformation of a mature teratoma of the adrenal gland: A rare case report and literature review. *Medicine (Baltimore)* 2017;96:e8333.
8. Chuan-Yu S, Yat-Faat H, Wei-Hong D, Yuan-Cheng G, Qing-Feng H, Ke X, et al. Laparoscopic adrenalectomy for adrenal tumors? *Int J Endocrinol.* 2014:241854. doi: 10.1155/2014/241854.

LEGENDS

Fig1 : CT image of upper abdomen: A spherical mass in right adrenal region with predominantly fat and punctate calcification

Fig 2: Gross findings: Cut specimen show cyst with tufts of hair and cheesy material.

Fig 3: Microscopy: H&E stain (200x) Components of cyst – Skin with hair shaft, mature adipose tissue and lymphoid aggregates.

Fig4 Microscopy: H&E stain (200x) Shows adrenal gland tissue (Arrow) compressed at periphery and mature adipose tissue.

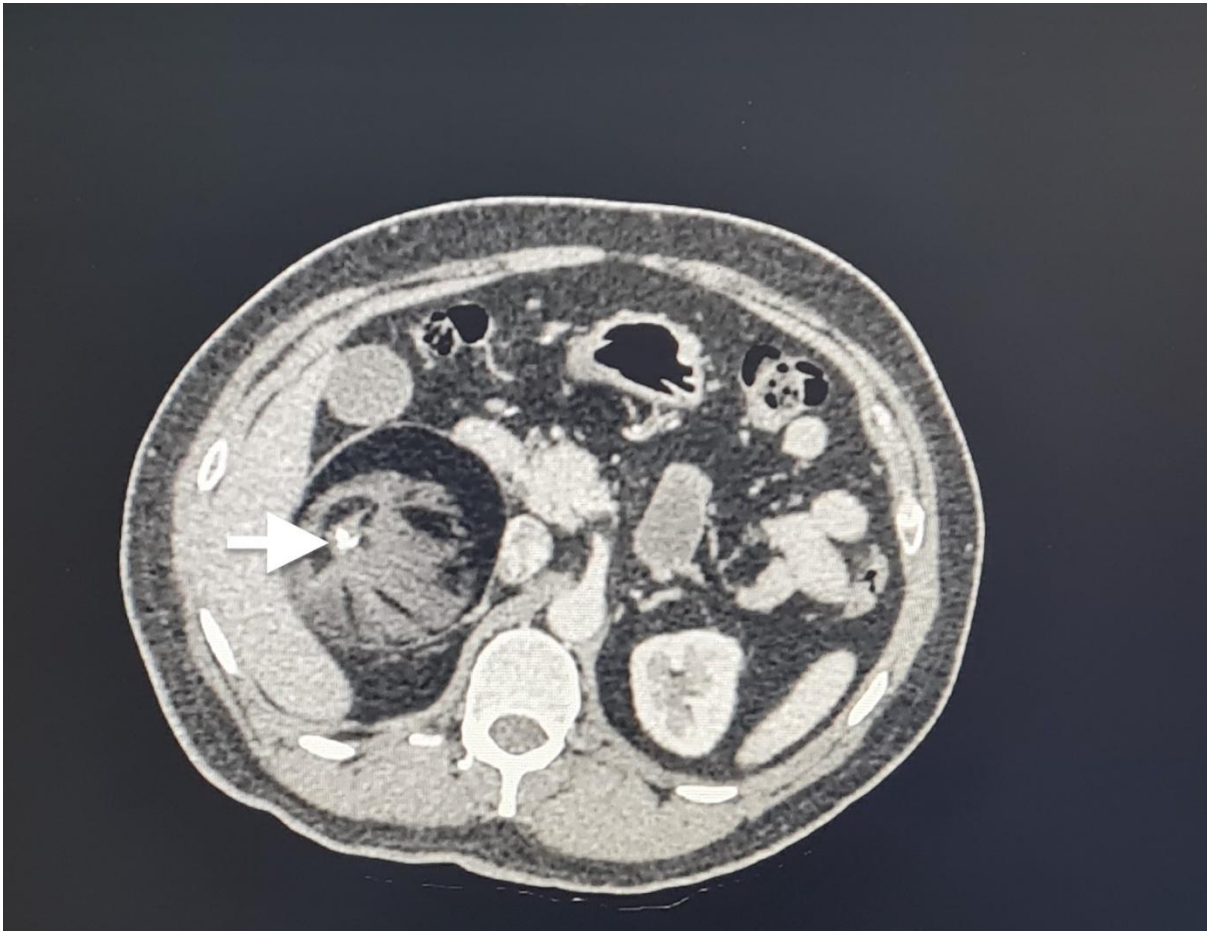


Fig 1:

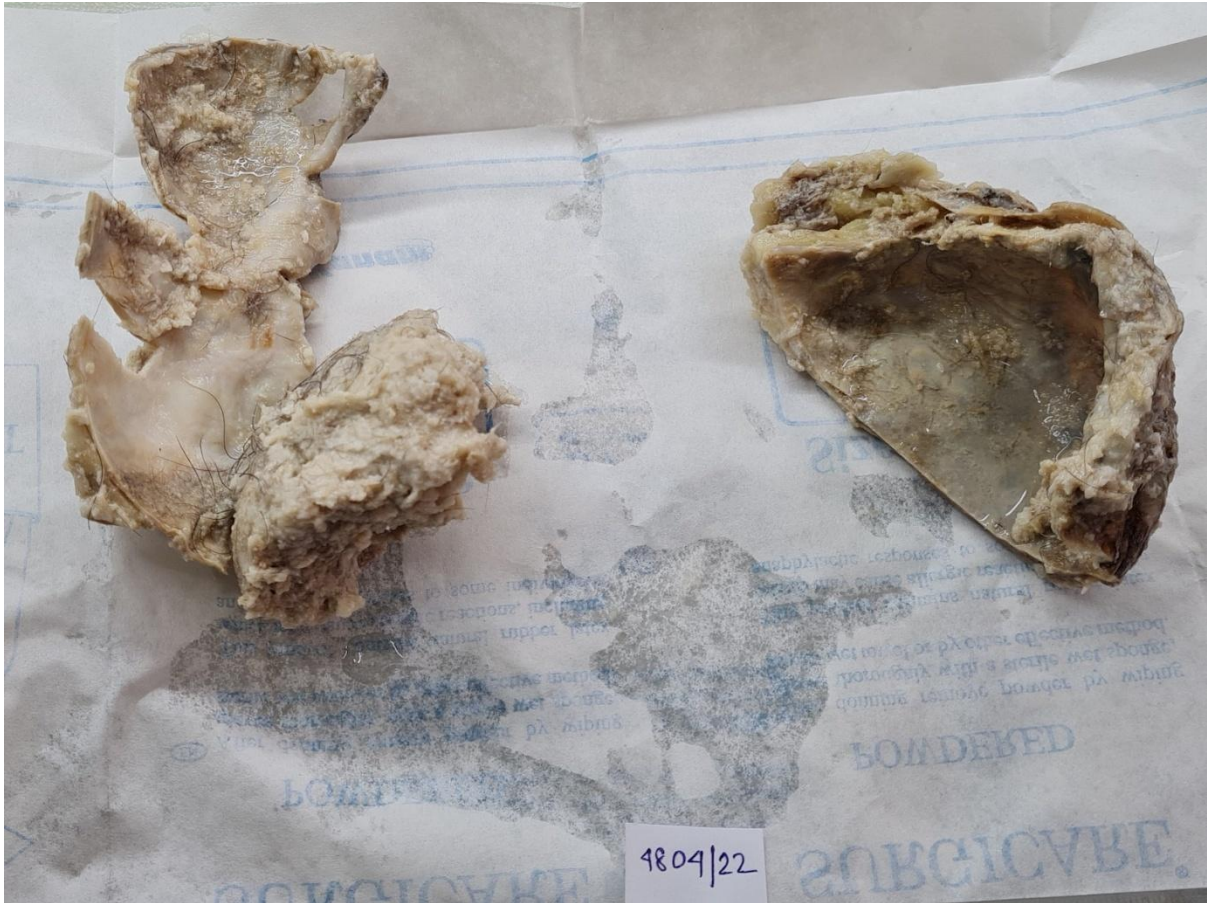


Fig 2:

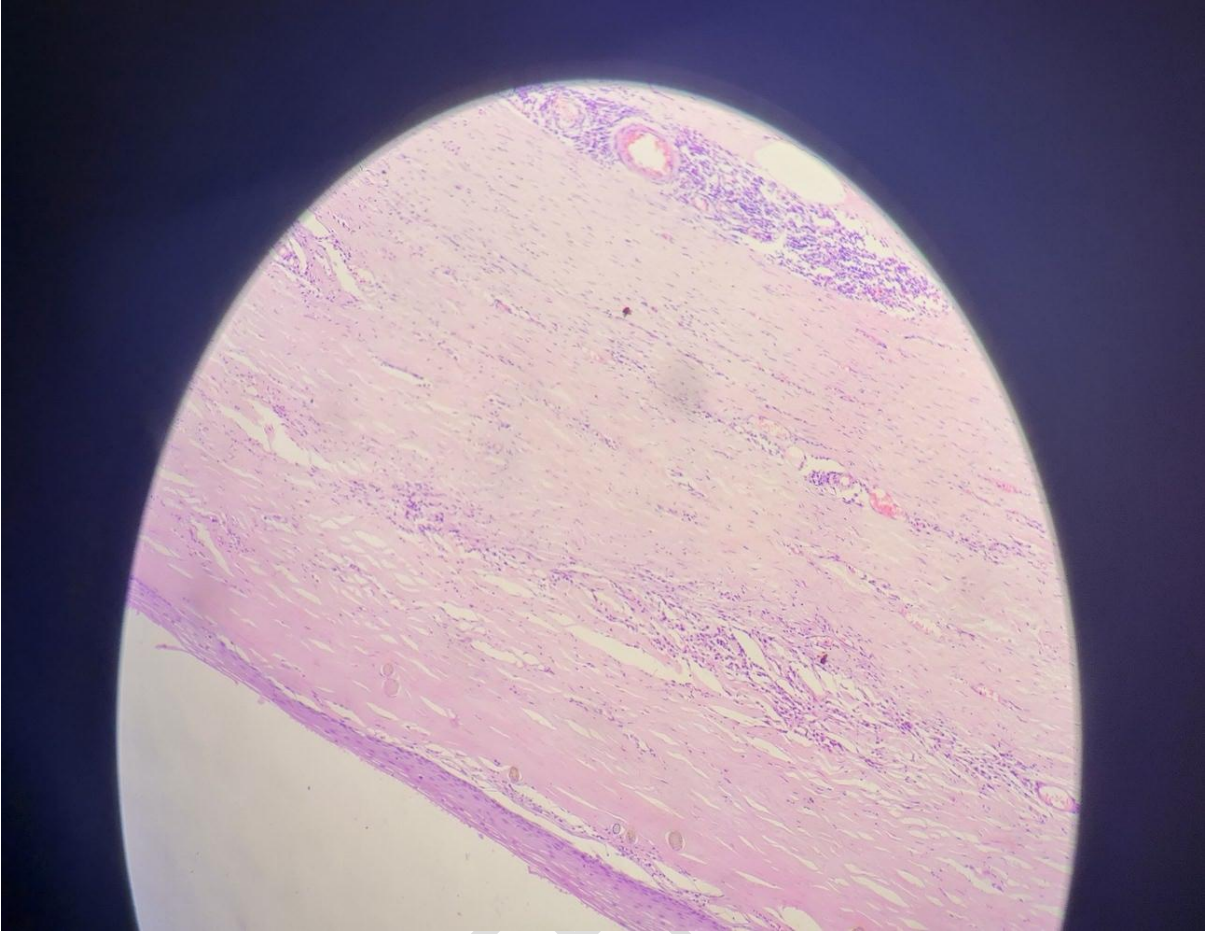


Fig 3

UNDER PEEL

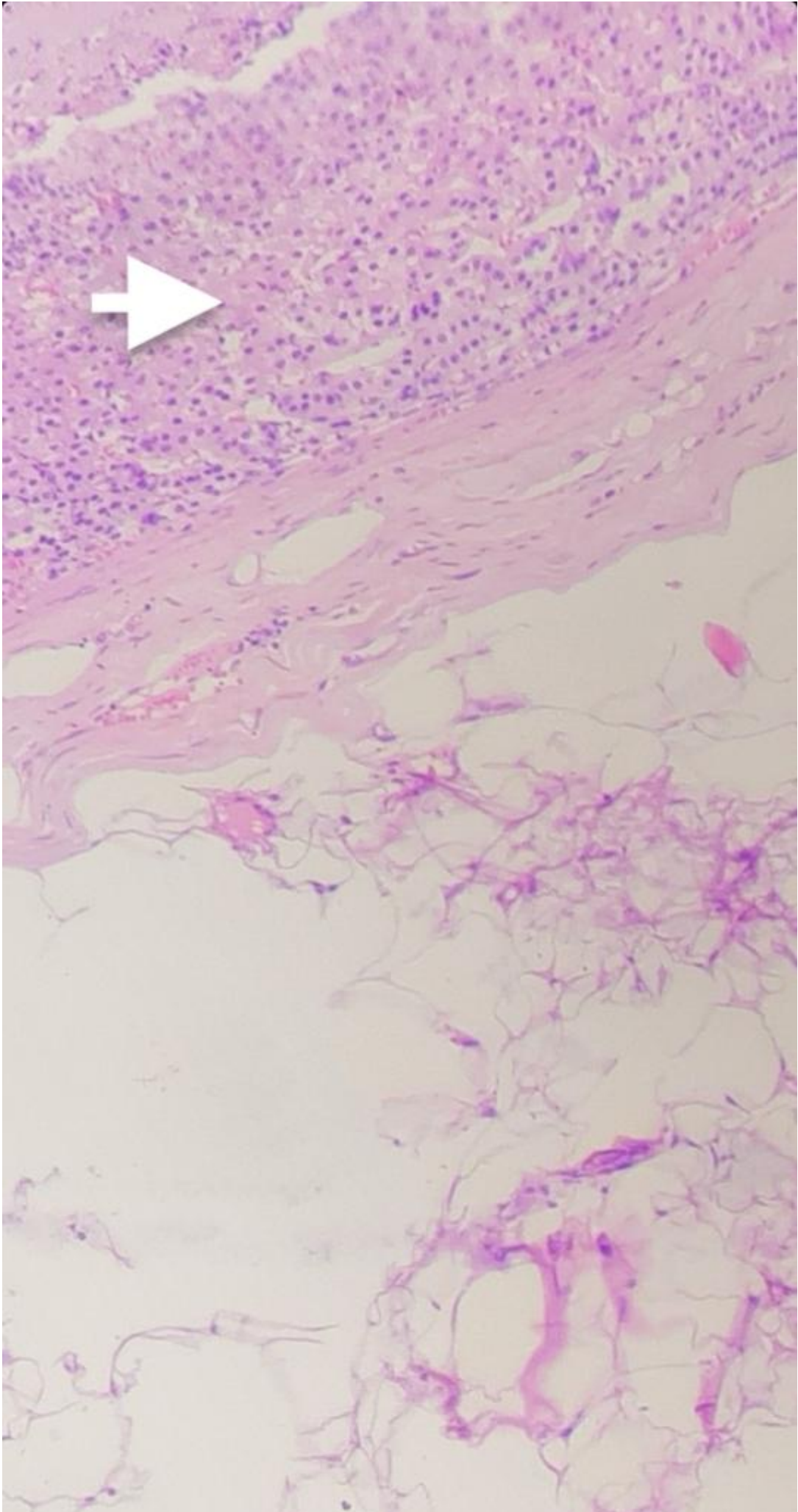


Fig 4:

UNDER PEER REVIEW