

ASSESSMENT OF *URTICA AESTUANS* EXTRACT ON ULCER INDICES AND HISTOLOGY OF INDOMETHACIN INDUCED GASTRIC TOXICITY

ABSTRACT

The effectiveness of *Urtica aestuans* leaf extract on ulcer indices and histopathology in Wistar rats was investigated in the current study. For this investigation, 30 rats were employed, divided into 5 groups of 6 rats each. These are the rat groupings: Groups 1 and 2 functioned as the control group (CG) and Indomethacin only group (INDOG), Group 3 as the standard drug group (SDG), Group 4 as the low dosage extract group (LDEG), Group 5 as the medium dose extract group (MDEG), and Group 6 as the high dose extract group (HDEG). All the rats received treatment for 14 days before being fasted for 24 hours with unlimited access to water. After a 24-hour fast, 40mg/kg of indomethacin was administered orally to induce gastric ulcers. The leaves of *Urtica aestuans* significantly ($P < 0.05$) decreased ulcer indicators. The acquired data suggests that the antioxidant properties of the plant extract and its active ingredients are responsible for the anti-ulcer actions of *Urtica aestuans* leaves extract.

Key words: *Urtica aestuans*, Indomethacin, Ulcer indices, Gastric toxicity.

Introduction

The most prevalent gastrointestinal and international disorder is stomach ulcers. It happens mostly as a result of an imbalance between the mucosal barrier's offensive and destructive elements (1). Stomach hydrochloric acid (HCl), mucosal hypoperfusion, free radicals, liquor, *Helicobacter pylori*, and excessive use of non-steroidal anti-inflammatory medicines (NSAIDs), which encourage gastric mucosal damage and gastric ulcers, are among the damaging causes (2). A medical problem is preventing or treating stomach ulcers. Major drawbacks of gastric ulcer therapy include the ineffectiveness of medications to treat the condition and severe side effects (3,4).

A potential alternative medicine that has fewer adverse effects and contains a variety of antioxidants may therefore be found in medicinal plants. According to a thorough literature analysis, medicinal plants are also promising complementary treatments for the creation of novel pharmaceuticals to control gastrointestinal illnesses (5).

Laportae aestuans is another name for the tropical and subtropical plant known as *Urtica aestuans* (family Urticaceae). This medicinal plant is used to treat hernias, fevers, and oedema in addition to preventing amenorrhea. Previous research has demonstrated that this plant has antibacterial, antifungal, and antioxidative properties. Additionally, *U. aestuans* extract may promote fertility and aphrodisiac activities (6). However, we still need to conduct suitable trial studies to fully understand the positive effects of *U. aestuans* leaf extract on stomach cytoprotective characteristics. In order to evaluate the gastroprotective effect of *U. aestuans* hydroethanolic extract against indomethacin-induced stomach ulcers in rodents, the current study was conducted.

Methodology

Preparation of extract

The Department of Plant Sciences, Faculty of Sciences, University of Port-Harcourt, Choba, Nigeria's botanic homestead, provided fresh leaves of *Urtica aestuans*, which were then collected and identified scientifically by the herbarium. The leaves were properly cleaned before being allowed to air dry. Until they were used for extract processes, the excellent quality of dried leaves was maintained in a dry plastic container.

Experimental Design

For this investigation, 30 rats were employed, divided into 5 groups of 6 rats each. All the rats received therapy for 14 days before being fasted for 24 hours with unlimited access to water. After a 24-hour fast, 40mg/kg of indomethacin was administered orally to cause gastric ulcers.

Group 1: Control group (CG), received feed and water ad libitum only

Group 2: Indomethacin only group (INDOG), received 40mg/kg of Indomethacin

Group 3: Standard Drug Group (SDG), received 400mg/kg of cimetidine

Group 4: Low dose extract group (LDEG), received 50mg/kg of the extract

Group 5: Medium dose extract dose group (MDEG), received 75mg/kg of the extract

Group 6: High dose extract dose group (HDEG), received 200mg/kg of the extract

The extract and cimetidine were administered orally for a period of 14 days.

DETERMINATION OF ULCER INDICES

Determination of gastric juice volume

Four hours after the gastric ulcer was induced, the rats were put to death, and the stomach was removed from the abdomen. To calculate the volume of gastric juice, stomach contents were collected into measuring cylinders.

Determination of gastric acid secretion

The gastric juice content was mixed with 5ml of distilled water, and the resulting solution was centrifuged at 3,000 rpm for 10 minutes. By titrating the supernatant to pH 7 with 0.0025N sodium hydroxide, the stomach acidity in mEq/L was calculated from the supernatant.

Determination of gastric mean ulcer index

Following the removal of the stomach's gastric contents, the stomach was pinned to a board, and the ulcer was then scored as follows:

1 denotes erosions that are less than 1 mm in diameter, 2 denotes erosions that are between 1 and 2 mm in diameter, and 3 denotes erosions that are larger than 2 mm in diameter. The ulcer index was calculated by multiplying the sum of the scores by a factor of 10.

Determination of percentage ulcer inhibition

The percentage of ulcer inhibition was also calculated as follows:

Percent ulcer inhibition = $\frac{\text{mean ulcer index of control} - \text{mean ulcer index of test}}{\text{mean ulcer index of control}} \times 100$

Mean ulcer index of control

Measurement of pH

Using a pre-calibrated Beckman pH metre, samples of gastric contents (1ml) were examined for hydrogen ion concentration. The electrodes were repeatedly washed with distilled water before being calibrated with pH 4 and pH 7 standard buffer solutions.

Statistical Analysis

The mean and standard error of the mean were used to express the results. With the use of Students Package for Social Science, version 23.0, data were analysed using a one-way analysis of variance, followed by the LSD post-hoc test to identify significant differences in all the parameters (SPSS). Differences were deemed statistically significant when their p-values were 0.05 or higher.

Results

Figure1: Values of ulcer parameters of extract in study animals.

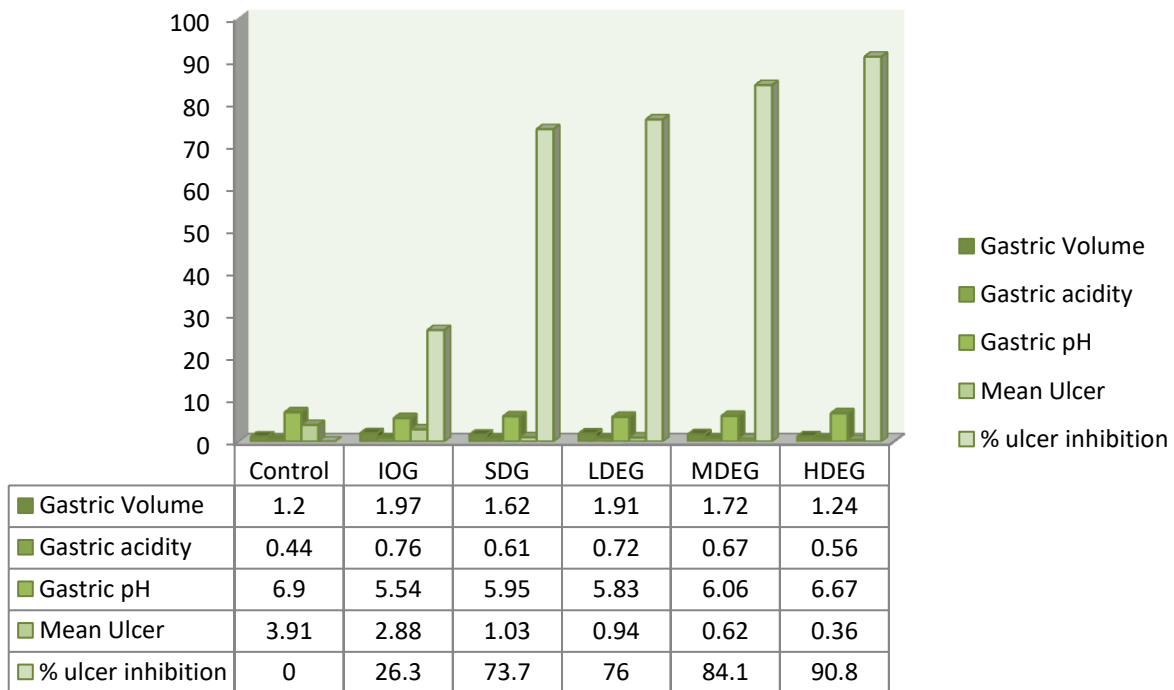
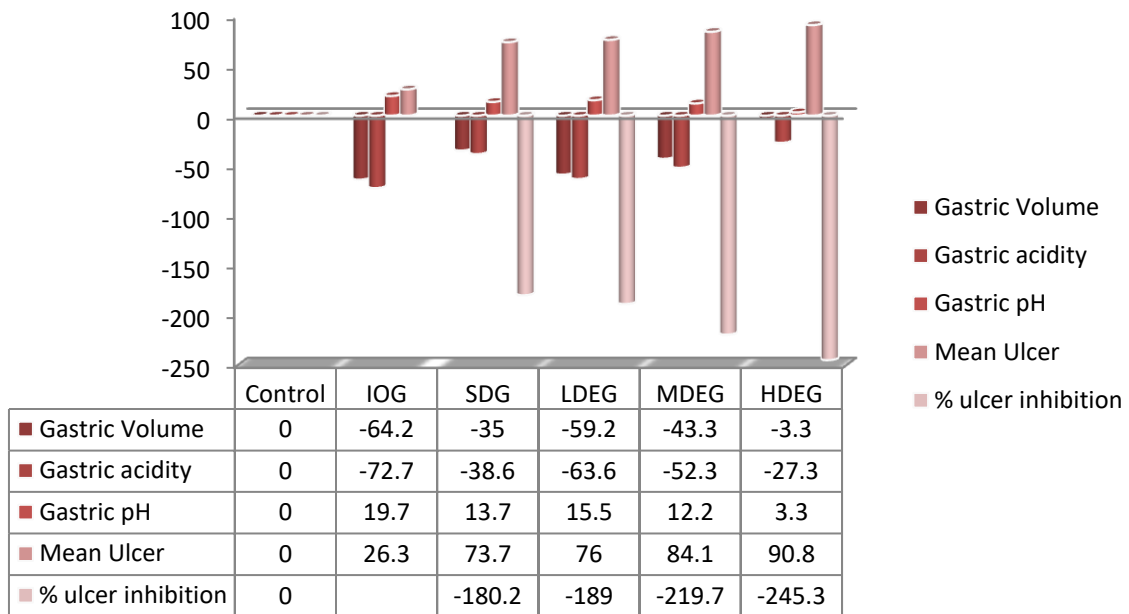


Figure 2: % diff of ulcer parameters of extract in study animals.



Plates : Histological Examination

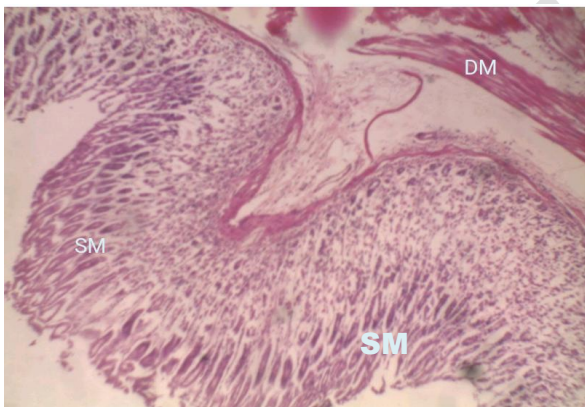


Plate 1

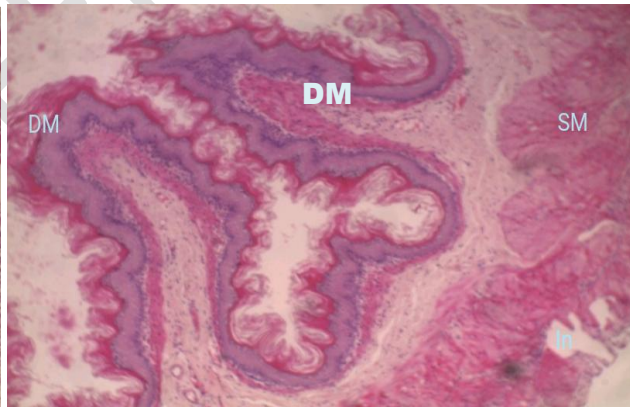


Plate 2

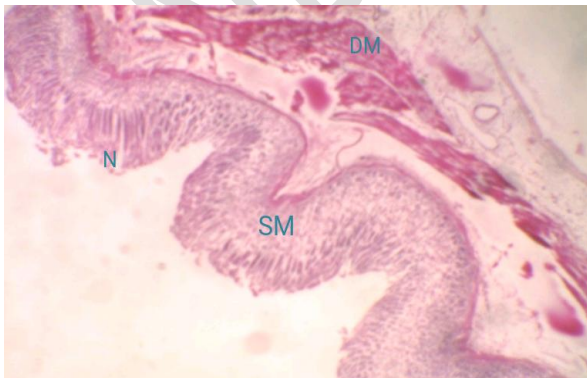


Plate 3

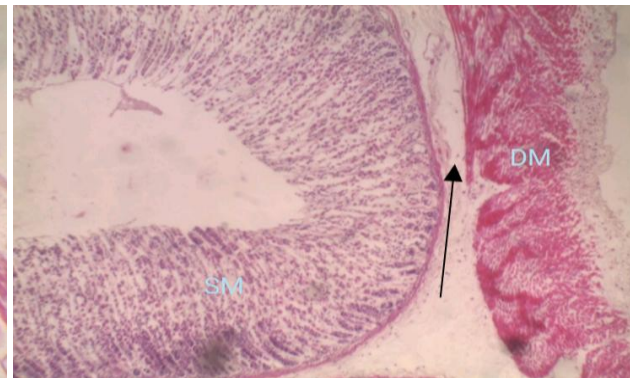


Plate 4

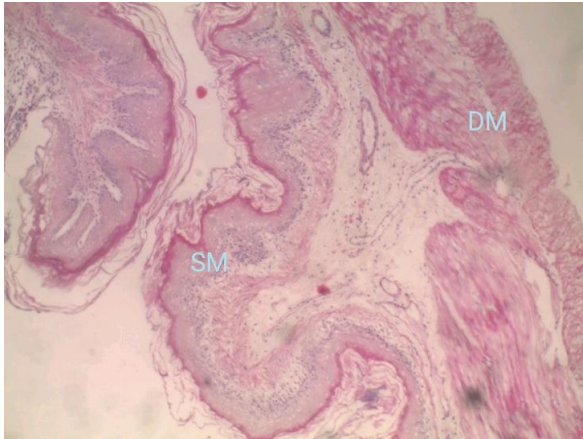


Plate 5

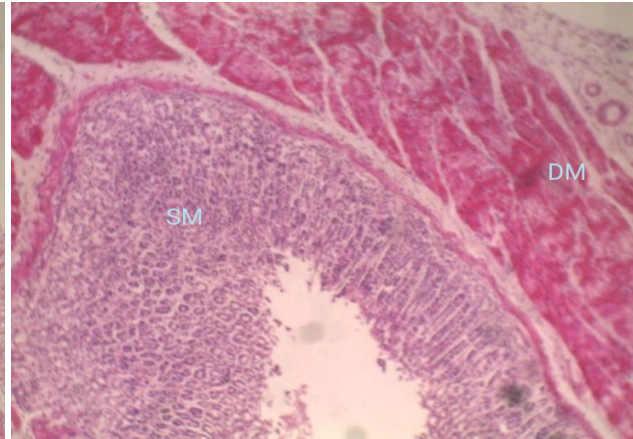


Plate 6

The INDOG's stomach mucosa had extensive damage, according to histology (Plate 2). Gastric mucosal necrosis was present in the ulcerated rat group. In contrast, animals fed with *U. aestuans* extract in the Plate 3–6 groups displayed improved protection of the stomach mucosa with a depressed level of or absence of leucocyte infiltration and edoema. Extracts of *U. aestuans* demonstrated defense actions that were dose-dependent and significantly improved stomach epithelial protection.

Discussion

In this study, it was found that treatment with *U. aestuans* leaf extract hastened the healing of chronic ulcers caused by indomethacin in the stomach tissue of rats. Indomethacin-induced chronic stomach ulcers are comparable to human ulcers in that they manifest in the same region, are as severe and persistent, and progress through a similar healing process (7). Changes in a variety of variables, including PG production, growth factor, NO, cytokine levels, and mucus formation, lead to the development of ulcers when indomethacin is used to induce them. Oral administration of indomethacin in this study also resulted in significant mucosal disruption, loss of normal colour, haemorrhage, edoema, and other macroscopic damage to the stomach mucosa layer. By blocking the production of PGs by cyclooxygenase-1 (COX-1) and causing oxidative stress in the gastric tissue, indomethacin weakens the gastric mucosa and causes a chronic gastric ulcer (7).

The main factors causing ulcer development and aggravation are ROS generation and oxidative stress. Additionally, indomethacin-induced chronic ulceration results in chronic oxidative stress with decreased SOD activity and GSH levels and elevated levels of lipid peroxidation (MDA). The protective effects of SOD, GSH, and MDA on the gastric mucosa against oxidative gastric mucosal injury are well recognized (8).

Endogenous sulfhydryl (SH) has implications for gastroprotection since it is critical for preserving the health of the gastric mucosa and increasing the basal concentration of nonprotein sulfhydryl, which is primarily reduced GSH (-glutamyl-cysteinyl-glycine). MDA is a reliable indicator of mucosal damage brought on by ROS. A collection of metalloenzymes known as SOD catalyze the conversion of oxygen and hydrogen peroxide from superoxide radicals. The initial line of defense against ROS inside cells is SOD. Therefore, oxidative stress in the tissue can be reflected and shown by expression analyses using SOD immunohistochemistry and measuring GSH and MDA levels (9, 10).

Furthermore, NSAIDs start the lipoperoxidation-producing ROS and operate as a prooxidant catalyst, which interferes with the antioxidant system of the mucosa's endogenous cells, causes leukocyte recruitment, and intensifies the inflammatory response.

Chronic ulcer healing is a complicated process that includes anti-oxidant activation, cell migration, proliferation, and replication of epithelial cells close to the edges to restore the glandular architecture, and granulation tissue angiogenesis at the ulcer's base (11, 12).

In addition to lowering MDA levels, treatment with *U. aestuans* extract may have activated SOD expression and increased GSH levels in the gastric tissue.

The ulcerated area brought on by indomethacin was greatly reduced by the treatment with this plant in a dose-dependent manner, supporting the theory that the *U. aestuans* leaf extract could stimulate gastrointestinal healing.

Histological examination of the lesion in the *U. aestuans* extract-treated groups' lesions (Plates D–F) reveals a reduction in the ulcerated region. On Plate B, the stomach wall of the ulcerated control group can be seen to have significant erosive lesions. Additionally, in the group receiving standard medication treatment, restructuring of the epithelium together with healing of the ulcerated area may be seen both microscopic and histologically (Plate C).

The main phyto-constituents and the identification mark for *U. aestuans* are thought to be phenolic compounds, tannins, and flavonones. Flavonoids and non-flavonoids are two different subclasses of phenolic compounds based on their chemical makeup. Anthocyanins, catechins, flavanones, flavones, flavonols, and isoflavones are among the polyphenols of the flavonoid type. Acids like hydroxycinnamic acid and phenolic acids are non-flavonoid types of polyphenols. The hydro-ethanolic leaf extract of *Urtica astuans* was found to contain several phenolic compounds of pharmaceutical interest, including catechols like vanillin, ferulic acid, and salicin, flavonols like

quercetin, gingerol, kaempferol, myricetin, and rutin, flavanones like naringenin, anthocyanidins like cyanidin, delphinidin, malvidin

Reports on the potential health advantages of phenols have greatly grown in recent years. (13).

According to reports, phenolic substances help treat stomach ulcers by promoting the production of PGE₂, mucus, and bicarbonate ions.

According to reports, flavonoids work on the digestive system and possess antispasmodic, anti-secretory, anti-diarrheal, anti-ulcer, and antioxidant activities (14). Among the cytoprotective substances for which anti-ulcerogenic activity has been thoroughly established are flavonoids. (15)

Through a number of modes of action, including enhanced mucus production, antisecretory activity, free radical scavenging and antioxidant capabilities, and prevention of *Helicobacter pylori* growth, they defend the gastric mucosa against a variety of ulcerogenic substances. (16,17)

Tannins prevent the onset of ulcers by precipitating proteins and restricting blood vessels. As shown by the gut secretions, their astringent activity can aid to precipitate microproteins on the ulcer site, generating an impenetrable coating over the lining, which prevents the development of an induced gastric ulcer in rats and shields the underlying mucosa from a decline in the ulcer scores (18).

These academic studies support the findings of the current study by showing that the phenolic compounds, flavonoids, and tannins found in *Urtica aestuans* leaves have a boosting influence on the defensive gastric factors and a debilitating effect on the offensive gastric factors.

Pharmacological research have documented and supported similar literature on plants having polyphenolic chemicals with substantial anti-ulcerogenic effect (19, 20).

Conclusion

Preclinical tests using *U. aestuans* extract showed strong gastroprotective and anti-ulcer properties, respectively, which were meaningful pharmacological effects. The potential of the extract's phytochemicals to boost the antioxidant defense system and modulate inflammatory indicators may be the cause of these benefits. Overall, this research can help create a new phytotherapeutic therapy for peptic ulcer illness or serve as a new raw material for a functional food ingredient that can be added to food matrices.

References

1. Czekaj, R., Majka, J., Magierowska, K., Sliwowski, Z., Magierowski, M., Pajdo, R. (2018). Mechanisms of Curcumin-Induced Gastroprotection against Ethanol-Induced Gastric Mucosal Lesions. *J. Gastroenterol.* 53, 618–630

2. M. Asali, A., Alghamdi, M. A., Fallatah, S. A., Alholaily, W. A., Aldandan, R. G., Alnosair, A. H. (2018). Risk Factors Leading to Peptic Ulcer Disease: Systematic Review in Literature. *Int. J. Community Med. Public Health* 5, 4617–4624.
3. Weltermann, T., Schulz, C., and Macke, L. (2021). Effect of Frequently Prescribed Drugs on Gastric Cancer Risk. *Best Pract. Res. Clin. Gastroenterol.* 50-51,
4. Scally, B., Emberson, J. R., Spata, E., Reith, C., Davies, K., Halls, H. (2018). Effects of Gastroprotectant Drugs for the Prevention and Treatment of Peptic Ulcer Disease and its Complications: a Meta-Analysis of Randomised Trials. *Lancet Gastroenterol. Hepatol.* 3 (4), 231–241
5. Edilane Rodrigues Dantas De Araújo, Gerlane Coelho Bernardo Guerra, Anderson Wilbur Lopes Andrade, Júlia Morais Fernandes, Valéria Costa Da Silva, Emanuella De Aragão Tavares, Aurigena Antunes De Araújo, Raimundo Fernandes de Araújo Júnior and Silvana Maria Zucolotto (2021): Gastric Ulcer Healing Property of *Bryophyllum pinnatum* Leaf Extract in Chronic Model *In Vivo* and Gastroprotective Activity of Its Major Flavonoid. *Front. Pharmacol* | <https://doi.org/10.3389/fphar.2021.744192>
6. Green I. Kinikanwo1, Charles C. Nwafor and Weleh I. Iyke (2021): Attenuation of Reproductive Dysfunctions by Hydroethanolic Leaf Extract of *Fleurya aestuans* in Diabetic Rats. *Asian Research Journal of Gynaecology and Obstetrics* 6(2): 24-31
7. Lim, J. M., Song, C. H., Park, S. J., Park, D. C., Jung, G. W., Cho, H. R. (2019). Protective Effects of Triple Fermented Barley Extract (FBe) on Indomethacin-Induced Gastric Mucosal Damage in Rats. *BMC Complement. Altern. Med.* 19, 149.
8. Tu, P. S., Tung, Y. T., Lee, W. T., and Yen, G. C. (2017). Protective Effect of Camellia Oil (*Camellia Oleifera* Abel.) against Ethanol-Induced Acute Oxidative Injury of the Gastric Mucosa in Mice. *J. Agric. Food Chem.* 65, 4932–4941.
9. Wang, X. Y., Yin, J. Y., Zhao, M. M., Liu, S. Y., Nie, S. P., and Xie, M. Y. (2018). Gastroprotective Activity of Polysaccharide from *Hericium erinaceus* against Ethanol-Induced Gastric Mucosal Lesion and Pylorus Ligation-Induced Gastric Ulcer, and its Antioxidant Activities. *Carbohydr. Polym.* 186 (1), 100–109.
10. Tu, P. S., Tung, Y. T., Lee, W. T., and Yen, G. C. (2017). Protective Effect of Camellia Oil (*Camellia Oleifera* Abel.) against Ethanol-Induced Acute Oxidative Injury of the Gastric Mucosa in Mice. *J. Agric. Food Chem.* 65, 4932–4941.
11. Amang, A. P., Mezui, C., Siwe, G. T., Emakoua, J., Mbah, G., Nkwengoua, E. Z. (2017). Healing and Antisecretory Effects of Aqueous Extract of *Eremomastax Speciosa* (Acanthaceae) on Unhealed Gastric Ulcers. *Biomed. Res. Int.* 2017, 1924320.
12. Kuna, L., Jakab, J., Smolic, R., Raguz-Lucic, N., Vcev, A., and Smolic, M. (2019). Peptic Ulcer Disease: a Brief Review of Conventional Therapy and Herbal Treatment Options. *J. Clin. Med.* 8 (2), 179.
13. Shahidi, F., and Yeo, J. (2018). Bioactivities of Phenolics by Focusing on Suppression of Chronic Diseases: A Review. *Int. J. Mol. Sci.* 19, 1573.

14. De Moraes, F. P., Xiong, J., Borges, K. C., Hoskin, R. T., and Esposito, D. (2020). Phytochemical Content, Antioxidant, Anti-inflammatory Activities and Wound Healing Properties of Freeze-Dried Fruits. *Act. Sci. Nutr. Health* 4 (1), 63–71.
15. Glevitzky, I., Dumitrel, G. A., Glevitzky, M., Pasca, B., Otrisal, P., BungauCioca, S. (2019). Statistical Analysis of the Relationship between Antioxidant Activity and the Structure of Flavonoid Compounds. *Rev. Chim.* 70 (9), 3103–3107.
16. Justino, J. (2021). Flavonoids - from Biosynthesis to Human Health. *Intech Open* 4. doi:10.5772/67810
17. Wang, X. X., Liu, G. Y., Yang, Y. F., Wu, X. W., Xu, W., and Yang, X. W. (2017). Intestinal Absorption of Triterpenoids and Flavonoids from *Glycyrrhizae radix* et rhizoma in the Human Caco-2 Monolayer Cell Model. *Molecules* 22 (10), 1627.
18. De Moraes, F. P., Xiong, J., Borges, K. C., Hoskin, R. T., and Esposito, D. (2020). Phytochemical Content, Antioxidant, Anti-inflammatory Activities and Wound Healing Properties of Freeze-Dried Fruits. *Act. Sci. Nutr. Health* 4 (1), 63–71.
19. Raeesi, M., Eskandari-Roozbahani, N., and Shomali, T. (2019). Gastro-protective Effect of Biebersteinia Multifida Root Hydro-Methanolic Extract in Rats with Ethanol-Induced Peptic Ulcer. *Avicenna J. Phytomed* 9 (5), 410–418.
20. Youn, S. H., Lim, H., Ju, Y., Soh, J. S., Park, J. W., Kang, H. S. (2018). Effect of Gastroprotective Agents on Upper Gastrointestinal Bleeding in Patients Receiving Direct Oral Anticoagulants. *Scand. J. Gastroenterol.* 53 (12), 1490–1495.