
Case study

Voriconazole associated hypertension: A Case report

Abstract

Objective: The study report a case of a young female with candida tropicalis and candida krusei infection who developed severe hypertension after she had repeated received voriconazole for few days.

Case presentation: A 23-year-old female was admitted to hospital because of recurrent urinary tract infection. She underwent horseshoe nephrectomy, extracorporeal lithotripsy treatment and double J-tube placement in the past 5 years. After multiple surgeries, she developed recurring fungal urinary tract infections and underwent anti-infective treatment. Twenty days ago, the patient developed chills, fever, dizziness, fatigue, urinary tract irritation signs and bilateral low back pain. Urine culture suggests Candida croco (resistant to fluconazole). After taking antifungal therapy with voriconazole 300 mg q12h, the patient experienced an unexplained increased blood pressure and transient loss of consciousness.

The patient began to experience an increase in blood pressure (140-160/90-100 mmHg) on the second day of voriconazole treatment.

After 5 days of taking voriconazole, the patient developed fatigue,

dizziness and blurred vision with persistent hypertension (150/100 mmHg), and temporary loss of consciousness and syncope on day 8, when blood pressure was measured at 175/95 mmHg.

Conclusion: This case illustrates that acute blood pressure elevation may manifest in patients taking normal doses of voriconazole, which deserves the attention of clinicians.

Key Words

Triazole antifungal agent; Hypertension; Voriconazole

Introduction

Voriconazole is a triazole antifungal agent with a broad spectrum of antifungal activity. The most common side effects of voriconazole include dizziness, headache, diarrhea, and fatigue. (Hedrick and Droz 2019; Levine and Chandrasekar 2016) Patients very rarely can develop thrombocytopenia and hepatic damage. Although other anti-infective drugs with activity against bacteria such as levofloxacin and piperacillin tazobactam have been associated with drug induced hypertension (Kaye et al. 2018), the incidence rate of azole is very low. Here, we report a case of a young female with candida tropicalis and candida krusei infection who developed severe hypertension after she had repeated received voriconazole for few days, and valsartan orally 80mg qd lowers blood pressure temporary. This is case report of voriconazole-induced hypertension, which should be paid attention to by clinicians.

In previous research, another antifungal drug, posaconazole, has been reported to increase the level of aldosterone in the blood by activating renin-angiotensin-aldosterone-system (RAAS) pathway (Beck, Thompson, and Odermatt 2020; Inderbinen et al. 2021; Nguyen et al. 2020), so that it save the sodium and excrete potassium, resulting in typical hypertension and hypokalemia. However, in this case report, we monitored serum Renin-Aldosterone-Angiotensin II and serum potassium, which showed that there was no obvious abnormality. It may suggest that the mechanism of voriconazole causing the hypertension is still unknown.

Case presentation

A 23-year-old female underwent horseshoe nephrectomy, extracorporeal lithotripsy treatment and double J-tube placement in the past 5 years. After multiple surgeries, she developed recurring fungal urinary tract infections and underwent anti-infective treatment. Twenty days ago, she presented with a 20-days history of left flank pain, vomiting, malaise, dysuria, urinary frequency, urgency, cloudy urine and malodorous urine. She denied fever, chills, rigor, or abdominal pain. At the time of admission, the physical examination revealed anemic appearance without costovertebral angle tenderness and lower extremity edema. Urine analysis showed 109 WBCs and 227 RBCs per high power field / micro liter. The urine culture indicated 10^5 colony-forming units (cfu)/ml bacterial concentrations in

specimen. Furthermore, candida krusei was detected in different urine specimens (at least 3 times), which was resistant to fluconazole (MIC=64ug/ml), sensitive to voriconazole (MIC≤0.25ug/ml), amphotericin B (MIC≤0.25ug/ml). Abdominal KUB and ultrasonography showed left urinary system double-J tube and left kidney stones. A chest computed tomography (CT) scan and other routine laboratory test were unremarkable. The first clinical diagnosis indicated recurrent complex urinary tract infections and hydronephrosis, and we chooses voriconazole 300mg q12h for antifungal treatment. (Benitez and Carver 2019)

Despite without history of hypertension, the patient occurred increased blood pressure (140-160/90-100mmHg) on the second day of taking voriconazole. These may be related to primary disease or drugs. In this regard, we closely monitored the changes of blood pressure instead of antihypertensive drugs. (Fig.1) Five days after taking voriconazole, the patient developed fatigue, anorexia, dizziness and blurred vision, accompanied by persistent hypertension (165/100mmHg). Transient loss of consciousness and syncope occurred on day 8, when blood pressure was markedly elevated at 175/95 mmHg. Further, 24h dynamic electrocardiogram results showed that blood pressure was significantly higher than before (average blood pressure was 140/89mmHg and the highest blood pressure was 165/105mmHg).

Considering the variety causes of syncope, including cerebral events,

metabolic disturbances, psychogenic patterns and intoxication, cranial computer tomography, serum hormone index and other form of laboratory examination were completed. (Choe et al. 2018) Nevertheless, the results of ACTH, cortisol, catecholamine and cranial CT were within the normal range. <Tab.1> Consider that CYP2C19 is the major drug metabolizing enzyme of voriconazole, we also detected that the metabolic pattern of CYP2C19 (Moriyama et al. 2017) of the patient was moderate. Voriconazole was discontinued at day 15 considering of the sufficiency treatment and the improved urinary irritation symptoms. Ten days following cessation of voriconazole therapy her blood pressure returned to normal, and the patient was discharged from the hospital with an improved general condition.

Four months later, the patient was subsequently admitted to our department again for the recurrent UTIs, for which presented urinary tract irritation, fever, chill, and flank pain. Urine analysis showed 3159 WBCs per micro liter. The urine culture indicated 10^5 colony-forming units (cfu)/ml *Candida tropicalis* concentrations in specimen. She was restarted on voriconazole tablets (300mg q12h) in an attempt to treat recurrent UTIs. A markedly elevated blood pressure and dizziness were also observed on the second day after medication. (Fig.2) The valsartan was temporarily used to control the hypertension when the blood pressure above 150/90 mmHg. However, the blood pressure was still poorly controlled. Fifteen days later,

on discussion with the patient it was decided to withhold antifungal therapy and repeat laboratory testing. Then three days following cessation of voriconazole therapy her blood pressure returned to normal. Furthermore, head CT, electrocardiogram, blood routine, liver function, and hormones (ACTH, cortisol, catecholamines) was normalized.

Discussion

Relevance evaluation of voriconazole induced hypertension.

In this case, the patient was admitted to the hospital due to complicated urinary tract fungal infection, and was received voriconazole 300mg q12h. However, although without history of hypertension, a significant increase in blood pressure (141/85 mmHg) was observed in the next day. The patient then had blurred vision and further increased blood pressure (165 / 95 mmHg). Furthermore, on the 8th day after voriconazole infusion, transient unconsciousness were found with blood pressure of 175 / 95 mmHg. The unconsciousness of the patient is regarded to be caused by neurovascular response to the sudden increase in blood pressure, after excluding craniocerebral, cardiogenic and hypovolemic. Then the patient's blood pressure returned to normal after stop taking the drug. 4 months later, the patient still had unexplained blood pressure rise after using voriconazole for the UTIs. Furthermore, the blood pressure accordingly decreased to normal after stop taking the drug.

Although the relevant symptoms such as hypertension and neurovascular syncope were not founded in the instructions of voriconazole, repeated increase in blood pressure was related to the time of administration of voriconazole, and the patients' performances such as hypertension and blurred vision improved after stopping the drug. Above all, according to the analysis of the judgment principle specified by the adverse drug reaction monitoring center of the ministry of health (Benitez and Carver 2019; McConachie et al. 2020), the newly appearing blurred vision, hypertension and neurovascular syncope were related to the using of voriconazole.

Dosage of voriconazole and related problems.

For complicated urinary tract infections, the voriconazole therapy (300mg q12h) is recommended according to The UAA-AAUS Guidelines for Urinary Tract Infections. (Choe et al. 2018) Voriconazole is a kind of triazole antifungal agent, which can selectively inhibits demethylation of 14 α -wool sterol mediated by fungal cytochrome P450 enzyme, delays biosynthesis of ergosterol, and against *Candida albicans*, *Candida paraplantatus*, *Candida tropicalis*. (Govindarajan et al. 2021) The patient was hospitalized due to the complicated urinary tract infection. What's more, the voriconazole was used for the treatment of *enterococcus faecium* and *Candida tropicalis* which were cultured in clean midstream urine. The dosage and frequency of voriconazole were reasonable. Due to the genetic

polymorphism of CYP2C19, Weiss J et al. (Mikus, Scholz, and Weiss 2011) found that 15% - 20% of the Asian population belongs to the slow metabolism type, which can lead to the abnormal increase of plasma concentration of triazole antifungal drugs and the aggravation of its hepatotoxicity. However, we also detected that the metabolic pattern of CYP2C19 of the patient was moderate. Therefore, it is unlikely that excessive intake or slow metabolism of voriconazole leads the increased blood concentration and hypertension.

Analysis of the mechanism of hypertension induced by voriconazole.

Cardiac output and peripheral vascular resistance were crucial for the formation of blood pressure. (McConachie et al. 2020) When cardiac output is increased, blood pressure increases accordingly. Furthermore, cardiac output is also affected by cardiac systolic and diastolic function, heart rate and blood volume. In the routine examination, the patient's cardiac function examination including blood routine, myocardial enzyme spectrum, liver and kidney function, cardiac ultrasound, chest CT were generally normal. What is the mechanism of azole antifungal drugs leading to elevated blood pressure?

For example, another antifungal drug, posaconazole, has been reported to increase the level of aldosterone in the blood by activating renin-angiotensin-aldosterone-system (RAAS) pathway (Beck, Thompson, and Odermatt 2020; Inderbinen et al. 2021; Nguyen et al. 2020), so that it

save the sodium and excrete potassium, resulting in typical hypertension and hypokalemia. Stopping posaconazole for 2 weeks, the patient's blood pressure returned to normal. We doubt that whether voriconazole has the same mechanism as posaconazole in causing blood pressure to rise. However, in this case report, we monitored serum Renin-Aldosterone-Angiotensin II and serum potassium in the early stage of the hypertension period (1 week after the acute risen of blood pressure), which showed that there was no obvious abnormality. It may suggest that the hypertension in this case may not be caused by the activation of RAAS pathway. <Tab.1>

Nevertheless, on the one hand, aldosterone elevation is a chronic procedure. According to the literature reports (Sanchez-Niño and Ortiz 2018), the elevation of aldosterone in the patient with hypertension induced by posaconazole was detected at 4 days after the increase in blood pressure.

(In Vivo 11β -Hydroxysteroid Dehydrogenase Inhibition in Posaconazole-Induced Hypertension and Hypokalemia - PubMed n.d.)

However, the serum 11-deoxycortisol level in this case only to be detected at the first week after admitted to the hospital, which is controversial for the real mechanism. Therefore, it cannot be ruled out whether the increase of blood pressure is caused by the activation of RAAS pathway. On the other hand, the blood concentration of voriconazole in this case was not detected. Above all, the mechanism of voriconazole causing the

hypertension is still unknown.

Conclusion

Above all, it is the first time that the acute increased hypertension has been detected in a patient with the normal dosage of voriconazole. In this paper, the symptoms such as hypertension and blurred vision were observed during the three hospitalizations, but the mechanism of the medicine still need to be verified by further examination such as hormone detection, blood mass spectrometry and so on. The relevant cases should be collected in the follow-up clinical work for statistical analysis and mechanism investigation, in that to expanding the indications and adverse effects of antifungal drugs.

Ethical Approval:

As per international standard or university standard written ethical approval has been collected and preserved by the author(s).

Consent

As per international standard or university standard, patient(s) written consent has been collected and preserved by the author(s).

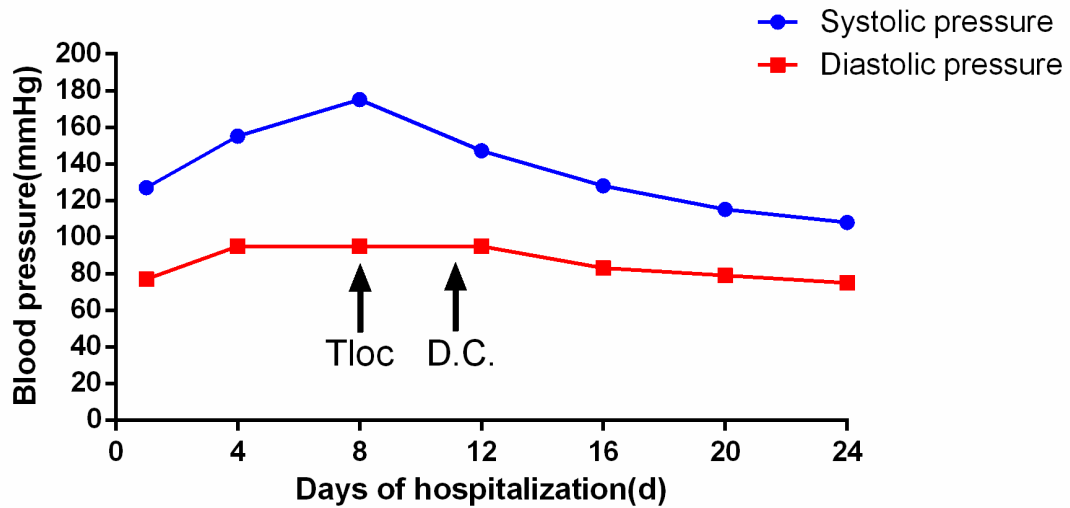


Figure 1. Fluctuation of blood pressure after voriconazole administration.

(Tloc, Transient loss of consciousness; D.C.: Discontinue)

The day after admitted (days)	Potassium (mmol/L)	Renin (pg/ml)	Aldosterone (pg/ml)	Angiotensin II (pg/ml)
0	3.7	4.44	101.44	121.75
3	4.0	9.04	120.33.	135.65
6	3.9	10.84	89.35	101.15

Table 1. Serum potassium and Renin-Aldosterone-Angiotensin II level association with the voriconazole administration.

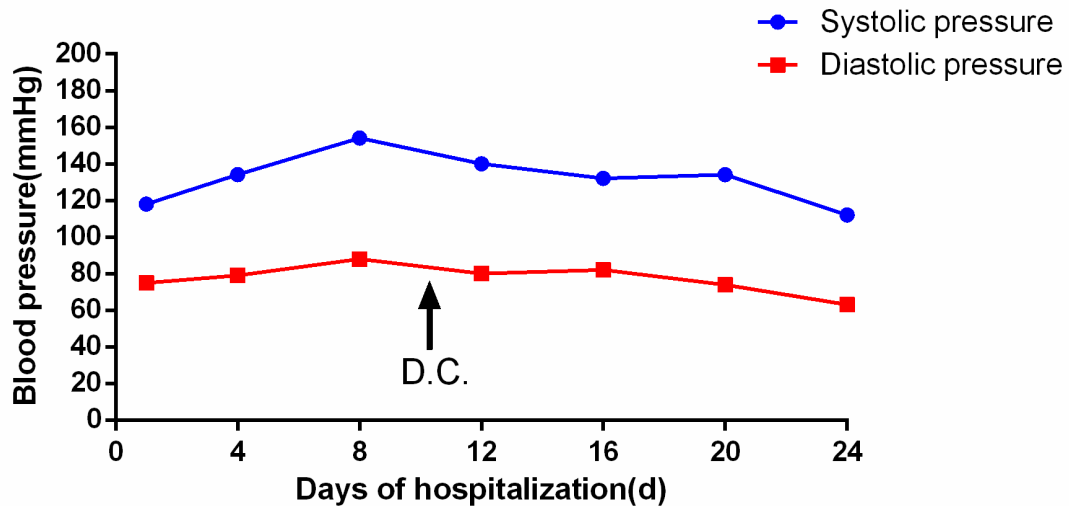


Figure 2. Fluctuation of blood pressure after voriconazole administration.

(D.C.: Discontinue)

References:

Beck, K. R., Thompson, G. R. & Odermatt, A. Drug-induced endocrine blood pressure elevation. *Pharmacol Res* **154**, 104311 (2020).

Benitez, L. L. & Carver, P. L. Adverse Effects Associated with Long-Term Administration of Azole Antifungal Agents. *Drugs* **79**, 833–853 (2019).

Choe, H.-S. *et al.* Summary of the UAA-AAUS guidelines for urinary tract infections. *Int J Urol* **25**, 175–185 (2018).

Govindarajan, A., Bistas, K. G., Ingold, C. J. & Aboeed, A. Fluconazole. in *StatPearls* (StatPearls Publishing, 2021).

Hedrick, J. & Droz, N. Voriconazole-Induced Periostitis. *N Engl J Med* **381**, e30 (2019).

In Vivo 11 β -Hydroxysteroid Dehydrogenase Inhibition in Posaconazole-Induced Hypertension and Hypokalemia - PubMed.

<https://pubmed.ncbi.nlm.nih.gov/28533238/>.

Inderbinen, S. G., Zogg, M., Kley, M., Smieško, M. & Odermatt, A. Species-specific differences in the inhibition of 11 β -hydroxysteroid dehydrogenase 2 by itraconazole and posaconazole. *Toxicol Appl Pharmacol* **412**, 115387 (2021).

Kaye, K. S. *et al.* Effect of Meropenem-Vaborbactam vs Piperacillin-Tazobactam on Clinical Cure or Improvement and Microbial Eradication in Complicated Urinary Tract Infection: The TANGO I Randomized Clinical Trial. *JAMA* **319**, 788–799 (2018).

Levine, M. T. & Chandrasekar, P. H. Adverse effects of voriconazole: Over a decade of use. *Clin Transplant* **30**, 1377–1386 (2016).

McConachie, S. M., Volgyi, D., Moore, H. & Giuliano, C. A. Evaluation of adverse drug reaction formatting in drug information databases. *J Med Libr Assoc* **108**, 598–604 (2020).

Mikus, G., Scholz, I. M. & Weiss, J. Pharmacogenomics of the triazole antifungal agent voriconazole. *Pharmacogenomics* **12**, 861–872 (2011).

Moriyama, B. *et al.* Clinical Pharmacogenetics Implementation Consortium (CPIC) Guidelines for CYP2C19 and Voriconazole Therapy. *Clin Pharmacol Ther* **102**, 45–51 (2017).

Nguyen, M.-V. H. *et al.* Posaconazole Serum Drug Levels Associated With

Pseudohyperaldosteronism. *Clin Infect Dis* **70**, 2593–2598 (2020).

Sanchez-Niño, M. D. & Ortiz, A. Unravelling drug-induced hypertension: molecular mechanisms of aldosterone-independent mineralocorticoid receptor activation by posaconazole. *Clin Kidney J* **11**, 688–690 (2018).

World Health Organization (WHO). WHO draft guidelines for adverse event reporting and learning systems Geneva, Switzerland: The Organization; 2005.

UNDER PEER REVIEW