

please double check :
 a) dosage or dose?
 b) mice or rats

Original Research Article

Alterations in Hepatocellular, Reproductive, and Oxidative Stress Parameters in Female Albino Rats Exposed to Crude Oil

If ? impossible to get 50 female albino rats. or shall be mice ?

ABSTRACT

Aim: To study the effect of exposure of crude oil on the liver, ovary and some-oxidative stress parameters in albino rats.

Study Design: A total of 50 female albino rats were used in the experiment. The rats were grouped into three: control group which consisted of 10 rats, low dose group which consisted of 20 rats and high dose group also consisted of 20 rats. The low dose group was orally administered 1.5mL crude oil mixed with 300grams of rat feeds (0.005mL/g) and the high dose group was orally administered 3.0mL crude oil mixed with 300 grams of rat feeds (0.01mL/g), while the control group was fed with normal rat feeds. The treated feeds were given once a day for a period of 35 days.

Place of Study: The study was carried out in the Department of Medical Laboratory Science, Rivers State University, Port Harcourt, Nigeria.

Methodology: On the 36th day, the rats were sacrificed and then 5mL of blood from each rat was collected by cardiac puncture into labeled lithium heparin bottles for liver enzymes assay, hormonal assay, and oxidative stress parameters assay, while the livers and ovaries were harvested and fixed in 10% formal saline prior to tissue processing and histological examinations using H&E staining technique. The collected blood specimens were spun; the plasma was extracted and analyzed in the laboratory for AST, ALT, ALP, FSH, LH, Prolactin, MDA and SOD. Statistical analysis was performed using Graphpad prism version 8.02.

Results: Significantly higher plasma levels of AST, ALT, and MDA in the treated groups, except for ALP which was only significantly higher in the high dose group. FSH, LH, Prolactin and SOD indicated significantly lower levels in the crude oil treated rats. The histological examinations showed marked distortion in the architecture of the livers and ovaries of the treated groups, also, there was reduction in ovarian cellularity and massive degenerated tissues.

Conclusion: It is shown in this research that exposure to crude oil contaminants orally could have significant effect in plasma level of hepatocellular enzymes, reproductive hormones, and oxidative stress parameters which in turn could lead to hepatocellular dysfunction, infertility or impaired reproduction in mammals and cellular injuries caused by excess free radicals as signaled by plasma level of oxidative stress parameters.

Keywords: Crude Oil, Hepatocellular Enzymes, Reproductive Hormones, Oxidative Stress markers, Niger Delta

1. INTRODUCTION

Crude oil exploration is the mainstay of the Nigeria economy and constitutes about 90% percent of the foreign exchange earnings of the nation [1]. The southern part of the country especially the Niger Delta area provides most of the space for exploration and exploitation of crude oil in Nigeria. It has been reported that an average of 240,000 barrels of crude oil are spilled in the Niger delta every year, mainly due to unknown causes (31.85%), third party

activity (20.74%), and mechanical failure (17.04%). This region harbours numerous rivers and streams through which freshwater empties into the Atlantic Ocean. ^{most of the time} Most times, these rivers provide the only sources of drinking water and marine food for the local communities within the area. The economic benefits of crude oil exploration and exploitation is accompanied with the discharge of harmful substances into the environment [2]. Crude oil is found to contain a number of poisonous compounds [3]. Over the years, there have been concerns about the effects of acute and chronic exposure to crude oil from direct contact with petroleum products, oil spills, pipeline vandalism, tanker accidents, as well as indirect ingestion of contaminated water and foods [4].

Crude oil composition is very ambiguous, consisting of complex combination of hydrocarbons, oxygen, sulfur, and nitrogen and trace metals. The hydrocarbons of crude oil consist of paraffin, cycloparaffins and aromatic substances containing at least ^{one} benzene ring. Bonny light crude oil (BLCO) also contains polycyclic aromatic hydrocarbons (PAHs). Majority of these elements (vanadium, nickel, asphaltenes, and poly^{polyaromatic} aromatic hydrocarbons) are considered to be toxic [5].

PAHs have been linked to liver damage in humans and cancers, especially lung cancers [6]. PAHs in agricultural crop add to organisms' exposure to these compounds via the dietary route [7]. Exposure to crude oil may occur directly or indirectly through inhalation, skin contact and ingestion [8]. Consumption of crude oil by humans may affect state of wellbeing however; the actual evidence of pathological and psychological effects on the health of local communities is poorly understood [9].

Symptoms such as anxiety, throat and eyes irritation, headache, depression, and sore throat may occur. It may also cause several problems to heart, lungs, kidney liver, endocrine, DNA and brain etc. [8]. ^{reverse!} Children, given crude oil to treat febrile convulsion, show symptoms of acute renal failure, sequel of shock, intestinal obstruction, extensive epidermolysis, mucositis, conjunctivitis, pneumonitis and oesophagitis. The symptoms of exposure may appear spontaneously (acute) or emerge after some time passes (chronic) [8].

This research is centered on the effects of acute exposure of crude oil on the liver, ovary and some oxidative stress markers. Globally, liver disease is a leading cause of illness and mortality [10]. Defect or injury to the ovary may lead to female infertility. Infertility is the inability of a couple to achieve pregnancy after one year of unprotected sexual intercourse. The prevalence of infertility varies, in Nigeria; its prevalence is up to 25% [11]. Malondialdehyde (MDA), a lipid peroxidation product, while Superoxide dismutase (SOD) act as catalyst for mopping excess free radicals (reactive oxygen species). These oxidative markers are vital in determining the extent of cellular damage. The disturbance of the integrity of the liver, ovaries and oxidative stress markers may be influenced by hereditary, lifestyle, and environmental variables [10]. Therefore, there is need to attempt to investigate the toxicological influence of crude oil on the different organ systems.

2. MATERIAL AND METHODS

2.1 Materials

The materials used in this study include Ohaus Scout-Pro electronic weighing balance (Ohaus Corporation, New Jersey, USA), Polypropylene gavage tubes (Intect Laboratory Incorporated, Plymouth Meeting, USA), Bonny light crude oil (BLCO), albino rats, Aspartate aminotransferase (AST), Alanine amino transferase (ALT), Alkaline Phosphatase (ALP), rat-specific ELISA kits for Follicle Stimulating Hormone (FSH), Luteinizing Hormone (LH), Prolactin, Malondialdehyde (MDA) and Superoxide Dismutase (SOD). H&E stains, Memmert Incubator, STAT-FAX 4200 Microplate Reader, Automatic Tissue Processor (MTPN-Series),

Is there necessary to use capital letter?

Rotary Microtome, and light Microscope. Others materials used include; automatic pipette dissecting board, pins, measuring cylinder, beakers, cotton wool staining trough, slides, cover slips, syringes and needles.

2.2 Experimental Animals

Fifty (50) female albino rats (*Rattus norvegicus*) of eight weeks old weighing 132.1 ± 2.233 g were used. The rats were purchase from Olive Green Laboratory Animals Company in Obieche, Aba, Abia State, Nigeria. The housing of the rats was made of conventional wire mesh metal cage of dimension (36 inch × 71 inch). The cage was separated into three compartments of equal size. The compartments were properly aerated; the bedding of the cage was made of pine shavings. Each group of rat was placed in separate compartments of the cage and kept under standard rat laboratory conditions (room temperature, 40-50% humidity and proper ventilation). The rats were avoided form exposure to rainfall and high sunlight with clean tap water for drinking and fed with rat pre-mix pellet feeds given *ad libitum* for the entire period of the experiment. The body weights of the rats were assessed daily prior to treatment. This experiment was carried out with regards to the Helsinki [12] declaration on the guiding principles of care and use of experimental animals.

2.3 Preparation of Treated Feeds

Control feed: 300g of rat pellets only (that is, dose of 0.00mL/g of rats feed). **Low Dose Feed:** 300g of rat pellets was mixed thoroughly with 1.5mL of bonny light crude oil making it a dose of 0.005mL/g of rats feeds. **High Dose Feed:** 300g of rat pellets was mixed thoroughly with 3.0mL of bonny light crude oil making it a dose of 0.001mL/g of rat's feeds. The method of treatment adopted the technique as described by Ogara et al. [13].

2.4 Administration of Crude Oil Contaminated Feeds

The crude oil used in this experiment was the Bonny Light Crude Oil (BLCO) and was gotten from the Department of Petrochemical Engineering, Rivers State, Port Harcourt Nigeria. The rats were allowed to feed on the feds contaminated with the crude oil for 35 days. Feds given were measured before and after on a daily basis. Before the crude oil contaminated feeds were administered, the rats were first made to acclimatize with the environment for two weeks in their cages.

2.4.2 Acute Toxicity Study

A total of 50 female albino rats were randomly divided into three (3) groups; Control group, low dose group and high dose group. Control group consisted of 10 albino rats with average weight of 134.1 ± 5.877 . The low dose consisted of 20 albino rats with average weight of 128.8 ± 7.587 and the high dose group consisted of 20 albino rats, and weight 133.8 ± 5.646 on the average. **Dose and Duration:** Control Group was fed with normal (uncontaminated) feeds and water only (that is, dose of 0.00mL/g of rats feed), the low dose (0.005mL/g) group was fed with 300g of rat feeds mixed with 1.5mL of BLCO while high dose (0.01mL/g) group was fed with 300g of feeds mixed with 3.0mL of BLCO. The treated feeds were administered ones every day for thirty five (35) days.

2.5 Study Area

capital letter?

→ shall be brown colour. or grey colour.

→ different country
different n.t. Also
specify TR.

The study was carried out and samples analyzed in the Department of Medical Laboratory Science, Port Harcourt, Nigeria. While the histological examination of the selected organs was carried out in the Anatomical Laboratory, College of Medical Science, University of Port Harcourt, Rivers State, Nigeria.

2.6 Specimen Collection, Preparation and Analysis

On the 36th day, the experimental rats were anesthetized with chloroform (CHCl₃) then the rats were placed on the dissecting board, lying supine with the four limbs pinned to the board and 5mL of blood was collected by cardiac puncture using syringe and then transferred into anticoagulant labeled bottle (lithium heparin bottle) for laboratory investigation. Organs were harvested using surgical blade to make a longitudinal incision and another incision on the upper left part of the thorax. The livers and ovaries of the experimental rats were harvested and preserved in 10% formalin in different labeled plastic containers prior to tissue processing and histological examinations. The collected blood specimens were spun at 4,500 rpm for 10 minutes to obtain plasma. The plasma was extracted into clean labeled plain bottles and stored in the refrigerator at 4 °C prior to the laboratory analysis. During the laboratory analysis, Plasma levels of ALT and AST were determined as described by Reitman-Frankel [14], ALP was determined as described by King-Angstrom [15], while FSH, LH, Prolactin, MDA and SOD were determined by Enzyme linked immunosorbent assay (ELISA).

capital letter?

2.7 Statistical Analysis

The data were statistically analyzed using Graphpad prism version 8.02 (San Diego, California, USA). Results were presented as Mean \pm Standard Deviation (SD), comparison of the values of exposed groups and control group was done using One-way ANOVA, at a significant p value of <0.05.

←
←

3. RESULTS

3.1 Results of ALT, ALP and AST in Rats Treated with Crude oil Contaminated Feds

The comparison of ALT, AST and ALP values between the control and the treated groups over a period of 35 days of treatment showed significantly higher values of ALT, ALP and AST in the low and high dose treated groups at $p < 0.05$. However, in ALP there were no significant difference between the control and the low dose treated rats. In addition, significantly higher values were observed in rats treated with high doses of crude oil compared against those treated with low doses (Table 1).

←

3.2 Results of FSH, LH and Prolactin in Rats Treated with Crude Oil Contaminated Feds

The control and the treated groups on comparison of their FSH, LH and prolactin levels showed significantly higher values of FSH, LH and prolactin in the low and high dose treated rats, there was also significant difference in FSH, LH and prolactin values when compared between the low and high dose treated rats, at $p < 0.05$ (Table 2).

3.3 Results of SOD and MDA in Rats Treated with Crude Oil Contaminated Feds

The plasma value of SOD was significantly reduced in the low and high dose treated groups when compared against the control rats. Also, there was significant difference of SOD value between the low and high dose treated groups when compared at $p < 0.05$ (Table 3).

3.4 Results of Body Weights in Rats Treated with Crude oil Contaminated Feeds

The body weights of the control and crude oil treated groups, after the experiment, were compared, the low and high treated groups showed significant decrease in body weight at $p < 0.05$ (Table 4).

Table 1: Results (Mean \pm SD) of Liver Enzymes in Serum of Rats Exposed to Feeds Contaminated with Bonny Light Crude Oil

Parameters	Control	Low dose	High dose	Pvalue	Fvalue	Remark
ALT(U/L)	27.25 \pm 11.05 ^a	35.76 \pm 12.17 ^b	49.11 \pm 19.97 ^c	0.0043	5.962	S
ALP(U/L)	26.83 \pm 15.09 ^a	31.25 \pm 7.95 ^a	42.75 \pm 17.88 ^b	0.0012	7.558	S
AST(U/L)	36.17 \pm 13.13 ^a	44.88 \pm 21.47 ^b	64.88 \pm 21.47 ^c	0.0001	4.840	S

Key: ALT= Alanine aminotransferase, ALP= Alkaline Phosphatase, AST= Aspartate aminotransferase. Tukey's post-Hoc: Within same row, values with different superscripts differ significantly at $p < 0.05$

Table 2: Results (Mean \pm SD) of Follicle Stimulating Hormone (FSH) and Luteinizing Hormone (LH) and Prolactin in Plasma of Rats Exposed to Feeds Contaminated with Bonny Light Crude Oil

Parameters	Control	Low dose	High dose	Pvalue	Fvalue	Remark
FSH (ng/ml)	4.07 \pm 1.20 ^a	2.03 \pm 0.81 ^b	1.63 \pm 0.62 ^b	<0.0001	31.63	S
LH (ng/ml)	2.10 \pm 0.1 ^a	1.20 \pm 0.1 ^b	0.98 \pm 0.1 ^b	<0.0001	31.45	S
Prolactin (ng/ml)	1.09 \pm 26 ^a	0.85 \pm 0.19 ^b	0.78 \pm 0.13 ^b	0.0002	10.25	S

Key: FSH= Rat-specific Follicle Stimulating Hormone, LH= Luteinizing Hormone. Tukey's Post-Hoc: Within same row, values with different superscripts differ significantly at $p < 0.05$

Table 3: Results (Mean \pm SD) of Superoxide Dismutase (SOD) and Malondialdehyde (MDA) in Plasma of Rats Exposed to Feeds Contaminated with Bonny Light Crude Oil

Parameters	Control	Low dose	High dose	Pvalue	Fvalue	Remark
SOD (ng/mL)	6.90 \pm 0.94 ^c	4.18 \pm 1.24 ^b	2.72 \pm 0.82 ^a	<0.0001	54.76	S
MDA(ng/mL)	148.3 \pm 34.64 ^b	161.6 \pm 21.24 ^b	178.1 \pm 11.27 ^a	0.0022	6.968	S

Key: SOD= Superoxide Dismutase, MDA= Malondialdehyde. Tukey's Post-Hoc: Within same row, values with different superscripts differ significantly at $p < 0.05$

Table 4: Results (Mean \pm SD) of Weight of Rats Exposed to Bonny Light Crude Oil Contaminated Feeds

Group	Weight Before (g)	Weight After (g)	Tvalue	Pvalue	Remark
Control	134.1 \pm 5.877	148.7 \pm 9.262	4.209	0.0005	S
Low dose	128.8 \pm 7.587	110.0 \pm 7.255	7.988	<0.0001	S
High Dose	133.8 \pm 6.463	113.5 \pm 6.509	9.872	<0.0001	S

S=Significant at $p < 0.05$

Table 5: Mean Average of Feed Contaminated with Crude Oil Consumed Over a Period of 35 Days

Dosage	Weight of feed given (g)	Weight of feed remaining (g)	Weight of feed consumed	pvalue	Fvalue	Remark
Low dose	300.0±0.00 ^a	51.23±43.11 ^b	248.8±43.11 ^c	<0.0001	487.6	S
High dose	300.0±0.00 ^a	74.03±52.73 ^b	226.5±53.35 ^c	<0.0001	247.9	S

Post-Hoc: Values in the same row with different superscript (a, b, c) differ significantly when compared to one another at p<0.05. S=Significant.

3.5 Histological Examinations

3.5.1 Histology of the Liver

The photomicrograph of the control rat liver tissue showed normal central vein as well as distinct hepatocytes that are deeply stained with the primary dye (haematoxylin). The hepatocytes are well arranged within the hepatic plate separated from one another by well-defined sinusoid radiating from the central vein (Fig 1A). The photomicrograph of the low dose rat showed the filtration of the central vein by parenchymal materials of the hepatocytes. The hepatocytes showed aggregation of nuclear material, these hepatocytes are hyperplexed with nuclear aggregation. The hepatic plate and sinusoids are completely distorted (Fig 1B). The photomicrograph of high dose rat indicates distorted central vein as well as vacuolation at the periphery of the central vein. The hepatocytes appeared to be hyperchromatic within and slightly distorted hepatic plate. The sinusoids also appeared distorted (Fig C).

3.5.2 Histology of the Ovaries

The photomicrograph of the control rat showed normal ovarian cortex with primordial follicles, growing follicles and mature ovum, while the photomicrograph of the low dose rat indicated mildly distorted growing follicle. The high dose rat showed degenerated follicles as well as absence of primordial follicles.

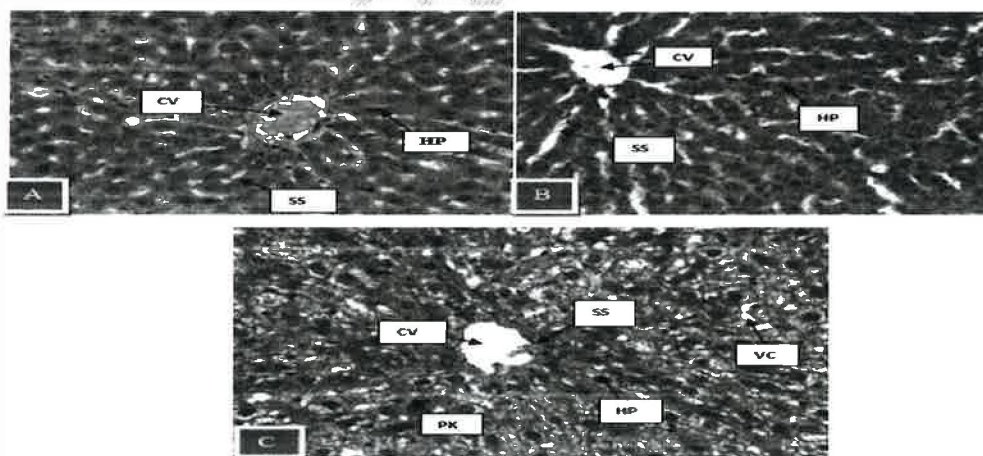


Fig 1: Histological images of Liver sections of female albino rats. Magnification X400 Stain: H&E. Image A: a photomicrograph liver section of a control rat showing Central Vein (CV), Hepatocytes (HP), and Sinusoids (SS). Image B: a photomicrograph liver section of low dose treated rat showing Distorted Central Vein (CV), and Hypercellularization of Hepatocytes (HP), as well as Dilated Sinusoids (SS). Image C: a photomicrograph liver section of high dose treated rat showing Hepatic Tissue Vacuolation (VC), Hypertrophied Hepatic Cells, Nuclear Pyknosis (PK) and Liver Tissue Fibrosis (LTF), as well as CV Infiltration

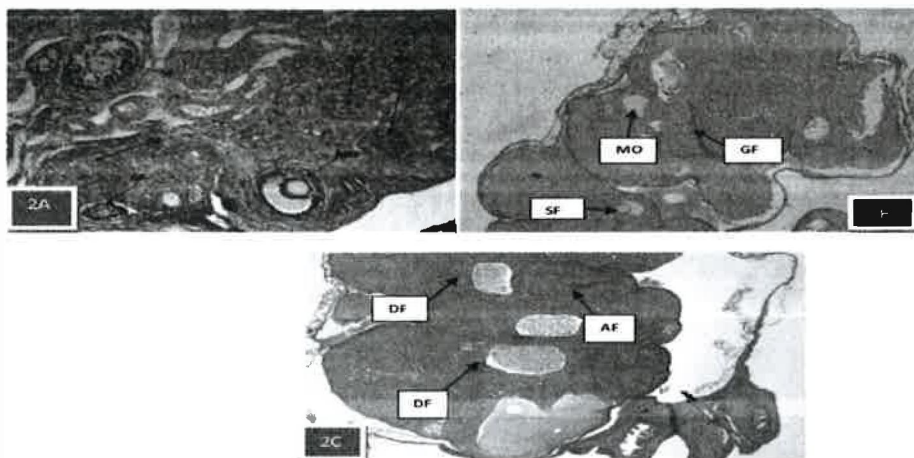


Fig 2: Histological images of ovaries sections of female albino rats. Magnification X400 Stain: H&E. Image 2A: a photomicrograph liver section. Image 2A: photomicrograph section of normal control tissue showing ovarian cortex with primordial follicles, growing follicles (GF) and mature ovum (MO), atretic follicles (AF), secondary follicles (SF) at different stages of developments. Image 2B: Photomicrograph section of ovarian tissues from rats treated with low dose, showing recovered secondary follicles (SF), mature ovum (MO), germinal and growing follicles, (GF). Image 2C: Photomicrograph section of an ovarian tissue from rats treated with high dose of extract showing atretic (AF) and degenerative follicles (DF).

4. DISCUSSION

The study of the rats' plasma level of MDA, SOD, ALT, AST, ALP, FSH, LH, Prolactin, and the histology of the livers and ovaries provided insight into the potential impacts of crude oil using the albino rat model. The liver is a multifunctional organ that is vulnerable to xenobiotic damage due to its major involvement in xenobiotic metabolism [16]. Hepatic toxicity and potential liver damage are indicated by ALT, AST, and ALP [17]. The increased levels of these plasma enzymes seen in the groups exposed to contaminated feeds with crude oil are indicative of cellular leakage and loss of cell membrane integrity as agreed with the works of Ubani and Joshua [18] and Ubani et al [19] who determined the kerosene has similar effect in albino rats. Photomicrographs of liver tissue from rats in control group revealed substantially normal histoarchitecture. The liver tissue of rats in group low dose group had a skewed arrangement of laminae plate and a dilated hepatic triad (SS) with a spindle-shaped slightly larger central vein (CV). The majority of hepatocytes have hyperchromatic nuclei, with others having hollow nuclei (HP). The liver necrosis within the dilated hepatic triad was seen in histological sections of rats in low dose group. In high dose group, the stroma appears heavily fibrous, with hypochromatic nuclei in some hepatocytes (HP). The central vein (CV) is enlarged and lined by single layer epithelial cells with multicystic spaces within which are seen as pyknotic hepatocytes (PK). The hepatic triad is slightly dilated (SS). Also seen are numerous ghost cells within the stroma. In a study done by Obidike [20] on the effect of crude on the stomach, his work also revealed degeneration of mucosal villi of the stomach. This study also recorded significant decrease in body weight of the exposed groups when compared against the control rats, this is in line with the findings of Obidike [20].

FSH, LH and prolactin are one of the most important endocrine parameters to evaluate on ovarian function [21]. Measurement of these hormones can establish the point of defect along the female reproductive system. The FSH, LH, and prolactin were significantly reduced in the treated groups when compared against the control group at ($p < 0.05$). The photomicrograph of the control rats, showed normal primordial follicles, and secondary follicles at the stage of developments while the photomicrograph of the low dose rats

indicated mildly distorted growing follicles. The high dose rat showed degenerating follicles as well as absence of primordial follicle. In the study done by Orisakwe et al. [22], they reported mild to complete degeneration and necrosis of the seminiferous tubules and reduction in the epididymal sperm count following administration of BLCO dissolved in drinking water to rats.

Malondialdehyde (MDA) is a useful biomarker for lipid peroxidation and oxidative stress. Different researchers have used MDA assay as a parameter for different sample types. Increased levels of oxidative stress have been associated with various disease patterns. MDA and MDA-DNA adduct determination has been found to be a valuable tool in finding out the associations of oxidative stress levels and occurrence of various pathologies. Conclusively, MDA estimations can be used as a reliable tool to assess oxidative stress levels and finding its relationships with different disease patterns [23]. SOD has a crucial antioxidant role in defending the cell from superoxide damage [24]. Numerous diseases, such as hepatocellular cancer [25], an accelerated loss of muscle mass with aging, and a shorter life span [26] are all present in mice lacking SOD1, in the midst of extreme oxidative stress. In the midst of extreme oxidative stress, SOD2 knockout mice pass away a few days after birth [27]. This study is in concordance with Chibuike et al. [28], as they recorded significant increase in plasma levels of MDA in the treated rats. In a study done on the exposure crude oil on plants, Skrypnik et al. reported significant increase in MDA and SOD activities in the shoots of plants [29]. Plants showed a similar increase in MDA level in line to this study but showed increase in SOD level contrary to this study.

4. CONCLUSION

The oral administration and ingestion of two different doses of crude oil mixed with rat feeds; for 35 days, revealed mild derangement of the liver and ovary in the low dose rats, and the derangement was more pronounced in the high dose treated rats. This study further reveals that irrespective of how little the quantity of crude oil contamination, it will induce toxicological and detrimental effect as seen in this study.

5. RECOMMENDATION

Due to the mild derangements observed in the treated groups, it is important to enlighten the local dwellers, the dangers of directly or indirectly ingestion crude oil.

CONSENT

Not applicable.

ETHICAL APPROVAL

We hereby declare that principles of laboratory animal care (NIH publication No. 85-23, revised 1985) were followed, as specific national laws where applicable. All experiments have been examined and approved by the Rivers State University research/ethics committee with file No: RSU/CV/APU/74/VOL.VIII/104.

please check all. TO.

REFERENCES

1. Bruederle A & Hodler R. Effect of oil spills on infant mortality in Nigeria. Proceedings of the National Academic of Science, 2019; 116(12): 5467-5471.
2. Micheal OE, Lasbrey A, Abanike TF, Tobchi A, Uwazie IU, Kalu EO, et al. Oil Exploration and Exploitation in Nigeria and the Challenges of Sustainable Development : An Assessment of the Niger Delta. International Journal of Energy Economics and Policy, 2019; 9(4):1-5.
3. Ogara A, Joshua P, Omeje K, & Onwurah I. Journal of Applied Science and Environmental Management, 2016;20(4):927-932.
4. Azeez M, Akhigbe RE, Anigbogu CN, Ige SF, & Saka WA. Variability in cardiovascular functions and baroflex sensitivity following inhalation of petroleum hydrocarbons. Journal of Cardiovascular Disease Research, 2012;3(2):99-103.
5. Wegwu M & Omeodu S. Evaluation of Selected Biochemical Indices in Clariasgariepinus Exposed to Aqueous Extract of Nigerian Crude Oil (Bonny Light)". Journal of Applied Sciences and Environmental Management. 2010; 14(1): 77-81.
6. Manoli E, Kouras A, Karagkiozidou O, Argyropoulos G, Voutsas D & Samara C. Polycyclic aromatic hydrocarbons (PAHs) at traffic and urban background sites of northern Greece: source apportionment of ambient PAH levels and PAH-induced lung cancer risk. Environmental Science and Pollution Research, 2016; 23:3556-3568. ←
7. Sun C, Zhang J, Ma Q, Chen Y & Ju H. Polycyclic aromatic hydrocarbons (PAHs) in water and sediment from a river basin: sediment-water partitioning, source identification and environmental health risk assessment. Environmental Geochemistry and Health, 2016; 39:1-12.
8. Azubike P, Isaac A, Owoeye O & Ebenezer O. Neurotoxicity of Nigerian bonny light crude oil in rats. Drug and Chemical Toxicology, 2013; 36(2):187-95.
9. Nriagu J, Udofia EA, Ekong I. & Ebuk G. Health risk associated with oil pollution in the Niger Delta, Nigeria. International Journal of Environmental research and Public Health, 2016; 13(3):346.
10. Adekanle O, Ijarotimi O, Obasi E, Anthony-Nwojo N. & Ndububa D. A Southwest Nigerian tertiary hospital 5-year study of the pattern of liver disease admission. Nigerian Journal of Gastroenterology and Hepatology, 2020; 12(1): 18-23.
11. Sule JO, Engbali P, Eruom L. Prevalence of infertility in Women in a Southern Nigerian Community. African Journal of Biomedical Research, 2008;11(2008): 225-227
12. World Medical Association. Declaration of Helsinki. Ethical Principles for Medical Research Involving Human Subjects. Journal of American Association of Medicine. 2013; 310(20), 2191-2194.
13. Ogara AL, Joshua PE, Omeje KO, Onwurah IN. Effects of Ingested Crude Oil Contaminated Diets on Antioxidant Enzyme and Lipid Profile in Wistar Albino Rat. Journal of Applied Science and Environmental Management. 2016; 20(4): 927-932
14. Reitman S, Frankel S, Colorimetric estimation of serum transaminases. American Journal of Clinical Pathology. 1957; 28(10):56-6. ← ??
15. King EJ, Armstrong AR. A convenient method for determining serum and bile phosphatase activity. Canadian Medical Association Journal, 1934;3(4):376-381.
16. Gu X, Manautu J. Molecular mechanisms underlying chemical liver injury. Expert reviews in of Molecular Medicine, 2012; 3(14):4.
17. Giannini EG, Testa R, Savarino V. Liver enzymes alterations: a guide for clinicians. Canadian Medical Association Journal, 2005; 172(3):367-379.

check the format. TO.

18. Ubani CS, Josua PE. Biochemical assessment of kerosene contaminated diet on the liver enzyme markers of albino rats. *Asian Journal Research Chem.* 2010;3(3), 795-800.
19. Ubani, CS, Oje, OA, Ogechukwu 1. Effects of Excravos light crude oil on liver enzyme markers activity and malondialdehyde levels of rat. *Journal of environmental and Occupational Studies*, 1 (3), 1.
20. Obidike NA. Effect of crude oil on intestinal motility and histology of ileum of Wista rats. *Biomedical and Pharmacology journal*, 2012;5(1):2012.
21. Raju GA, Chavan R, Deennadayal M, Gunasheela D, Gutgutia R, Haripiriya G, Govindarajan M, Patel HN, Pakti S. Luteinizing hormone and follicle stimulating hormone synergy: A review of role in controlled ovarian hyper-stimulation. *Journal of Human Reproductive Science* 2013;6(4):227-234.
22. Orisakwe OF, Afonne OJ, Nwobode E, Asonugha L, Dioka CE. Testicular toxicity of Nigeria's bonny light crude oil in male albino rats. *Reproductive Toxicity* 2004;18:43-42.
23. Signh Z, Karthigesu, I, Singh P, KAUR R. Use of malondialdehyde as a biomarker for assessing oxidative stress in different disease pathologies: a Review. *Iranian Journal of Public Health*, (2014); 43(3):7-16. } ←
24. Alscher RG, Erturk N, Heath LS. Role of superoxide dismutases (SODs) in controlling oxidative stress in plants. *Journal of Experimental Botany*, 2002;53(372):1331–1341.
25. Elchuri S, Oberley TD, Qi W, Eisenstein RS, Jackson Roberts L, Van Remmen H, et al. CuZnSOD deficiency leads to persistent and widespread oxidative damage and hepatocarcinogenesis later in life. *Oncogene*, 2005; 24 (3): 367–380.
26. Muller FL, Song W, Liu Y, Chaudhuri A, Pieke-Dahl S, Strong R, et al. "Absence of CuZn superoxide dismutase leads to elevated oxidative stress and acceleration of age-dependent skeletal muscle atrophy". *Free Radical Biology & Medicine*, 2006;40(11):1993–2004.
27. Li Y, Huang TT, Carlson EJ, Melov S, Ursell PC, Olson JL, et al. "Dilated cardiomyopathy and neonatal lethality in mutant mice lacking manganese superoxide dismutase". *Nature Genetics*, 1995;11 (4): 376–381.
28. Chibuike SU, Obinna AO, Isaac O. Effects of excravos light crude oil on liver enzyme markers activity and malondialdehyde levels of rats. *Journal of Environmental and Occupational Science*, 2012; 1(3), 161-166.
29. Skrypnik L, Maslennikov P, Novikova A, Kozhikin M. Effect of Crude Oil on Growth, Oxidative Stress and Response of Antioxidative System of Two Rye (*Secale cereale* L.) Varieties. *Plants Basel*, 2021;10(1):157. ←

check the format!