
Second Trimester Uterine Rupture of an Unscarred Uterus in a Primigravida: A Case Report

ABSTRACT

Antepartum uterine rupture in an unscarred uterus is extremely rare. Early-pregnancy uterine rupture in nulliparous women is an uncommon, unpredictably occurring event with substantial maternal morbidity and catastrophic fetal outcomes. Undiagnosed uterine perforation could be the cause of this dangerous condition underestimated in the literature. We report a rare case where undiagnosed uterine perforation during curettage could be the cause of uterine rupture.

Keywords: Rupture uterus; spontaneous; unscarred uterus.

1. INTRODUCTION

“Spontaneous uterine rupture in the second trimester of an unscarred uterus is rare and carries severe risk to both mother and fetus compared to scarred uterus” [1]. “The causes of rupture of unscarred uterus include grandmultipara, injudicious use of oxytocics, uterine anomalies, internal podalic version with breech extraction, external cephalic version, instrumentation like forceps application or vacuum extraction” [2]. A few cases of primary antepartum uterine rupture have been reported where no direct etiology is found. Pre-labour rupture of uterus is a rare identity. We present a rare case of spontaneous rupture at 18 weeks of gestation in a primigravida where no direct etiology was found.

2. CASE REPORT

A 32 year old primigravida at 18 weeks of gestation with a dichorionic- diamniotic twin pregnancy reported to the emergency department with history of pain in the epigastric region. Eight months back she underwent a diagnostic hysteroscopy and laparoscopy as a part of infertility work-up. No electrosurgical procedures were performed. On examination, her blood pressure was 116/60 mm Hg and her pulse rate was 138 beats per minute. On abdominal examination uterine fundus was tender. Sonography showed twin pregnancy with absent cardiac activity of both fetuses with free fluid in the abdomen. Ultrasonographic findings were suspicious of uterine rupture but there was no correlation with her history given her parity status and gestational age. Hence emergency CT

abdomen(Fig. a) was done and it showed loss of myometrial architecture with fluid in the abdomen suggestive of uterine rupture. She was stabilized and taken up for an emergency laparotomy which revealed massive hemoperitoneum with both the fetuses and placenta in the abdominal cavity. A uterine rupture of 6 cm length was noted in the fundal region. (Fig. b) The uterine defect was repaired with a continuous double layer closure with 1-0 synthetic monofilament absorbable suture. There was no features suggestive of adherent placenta. Patient was transfused with 2 units of packed red cells. Post operative period was uneventful. There was no history suggestive of collagen disease in the patient. Patient was subjected for genetic workup for Ehler-Danlos syndrome and was tested negative. She was further counselled about the risk of recurrent uterine rupture(22-100%).

3. DISCUSSION

“Spontaneous rupture of uterus in a nulliparous woman before onset of labour in an unscarred uterus is very rare. Overall rupture uterus is estimated to occur 1 in 5700 to 1 in 20000 pregnancies. The most common site of rupture in an unscarred uterus is the fundus”[3].

Rare causes of uterine rupture in literature are adenomyosis, pelvic radiation, connective tissue disease and chronic steroid use. Eleven cases of uterine rupture in the second trimester of unscarred uterus were reported in which 5 cases had placenta percreta, 2 had myomectomy, 2 had uterine anomalies and 2 had no risk factor[4,5,6].

Uterine perforation during operative hysteroscopy or even by uterine sounding has been associated with the possibility of uterine rupture[7]. In the current case, the patient had diagnostic hysteroscopy where no electrosurgical procedures were performed and there was no history of perforation. Hysteroscopy findings

revealed normal endometrial cavity and endometrial biopsy was taken and sent for histopathology examination and TBPCR. The results were negative. The possibility of undiagnosed uterine perforation could be the cause for uterine rupture.

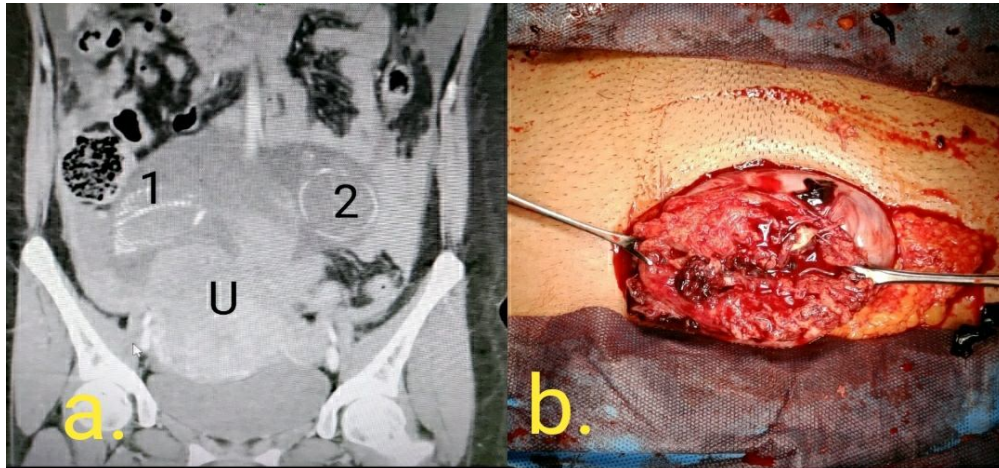


Fig. (a). CT abdomen and pelvis showing Fetus 1 and fetus 2 in the abdominal cavity with loss of myometrial architecture; Fig. (b) Uterine fundal rupture of about 6 cm length

The complications of a primary uterine rupture includes severe post-hemorrhagic anemia, puerperal infection, broad ligament hematoma, chance or an irreparable rupture requiring hysterectomy, damage to the bladder or bowel, perinatal mortality. Etc [8]. The cause of rupture in our case is not defined. One possibility could be inherited collagen disease Ehler- Danlos syndrome [9]. Our patient underwent genetic testing for the same and was negative.

Fang-Peng et al, 2007 reported a successful term delivery following spontaneous 2nd trimester uterine rupture and surgical repair. She had no apparent risk factors. The rent at the fundus was repaired without damaging the amniotic membrane at 26 weeks. Patient was put on tocolysis and delivered at 37 weeks by C-section, hence suggesting a conservative management as an alternative to hysterectomy [10].

A case series by Aggarwal et al, 2021 reported “3 different presentations of uterine rupture. One among them was a 21-year-old primigravida with breech presentation at a gestation of 34 weeks 6 days with preterm labour was taken up for LSCS and on entering the abdomen rupture uterus with an inverted T-shaped rent in the upper segment extending up to the fundus was seen. A stillborn male fetus was delivered through the rent,

followed by successful uterine repair. Early diagnosis and timely intervention by the obstetrician, can help us to improve the fetal and maternal outcome drastically”[11].

“Second trimester uterine rupture in unscarred uterus is very rare, but life threatening obstetrical emergency that should be considered as part of differential diagnosis for severe abdominal pain in early pregnancy. Rupture of scarred uterus have greater maternal morbidity, greater mean blood loss and higher rate of blood transfusion than rupture of a scarred uterus, renal failure, need for dialysis, life support. Etc. A risk of recurrent rupture is described upto 22-100% of cases mainly when it occurs at the fundus” [12]. It is important to counsel patients who have not completed family.

Child birth after uterine rupture require great deal of attention. They carry a high risk of recurrent uterine rupture. Successful near-term deliveries have been reported with meticulous tertiary level antenatal care and planned operative delivery [13].

4. CONCLUSION

In conclusion, uterine rupture is a rare complication especially in nulliparous women before labour. However clinical suspicion, early

diagnosis may represent the only possibilities to preserve maternal and fetal outcomes. The overall risk of uterine rupture associated with prior curettage is low but warrants consideration by obstetrician when clinical events raise concern for uterine rupture. We recommend clinicians to be aware of uterine rupture in pregnant women with pain abdomen with a history of uterine manipulation [14,15]. Because of the rarity of its occurrence, more evidence should be collected to increase understanding of this potentially lethal complication.

CONSENT

As per international standard or university standard, patient(s) written consent has been collected and preserved by the author(s).

ETHICAL APPROVAL

As per international standard or university standard written ethical approval has been collected and preserved by the author(s).

COMPETING INTERESTS

Authors have declared that no competing interests exist.

REFERENCES

1. Gibbins KJ, Weber T, Holmgren CM, Porter TF, Varner MW, Manuck TA. Maternal and fetal morbidity associated with uterine rupture of the unscarred uterus. *American Journal of Obstetrics and Gynecology*. 2015;213(3):382-e1.
2. You SH, Chang YL, Yen CF. Rupture of the scarred and unscarred gravid uterus: Outcomes and risk factors analysis. *Taiwanese Journal of Obstetrics and Gynecology*. 2018;57(2):248-54.
3. Available: www.uptodate.com/contents/uterine-rupture-unscarred-uterus
4. Boujida S, M'Hamdi O, Flissate F, Baidada A, Kharbach A. Placenta percreta as a cause of uterine rupture in the second trimester: Case report. *International Journal of Surgery Case Reports*. 2022;94:107069.
5. Damiani GR, Gaetani M, Landi S, Lacerenza L, Barnaba M, Spellecchia D, Pellegrino A. Uterine rupture in a nulliparous woman with septate uterus of the second trimester pregnancy and review in literature. *International Journal of Surgery Case Reports*. 2013;4(3):259-61.
6. Li X, Li C, Sun M, Li H, Cao Y, Wei Z. Spontaneous unscarred uterine rupture in a twin pregnancy complicated by adenomyosis: A Case report. *Medicine*. 2021;100(3).
7. Heemskerk SG, Ten Eikelder ML, Janssen CA. Uterine rupture in pregnancy after an intervention complicated by uterine perforation: Case report and systematic review of literature. *Sexual & Reproductive Healthcare*. 2019;19:9-14.
8. Cunningham F, Leveno K, Bloom S, Spong CY, Dashe J. *Williams obstetrics*, 25e, New York, NY, USA: Mcgraw-Hill. 2018;765-767.
9. Pepin M, Schwarze U, Superti-Furga A, Byers PH. Clinical and genetic features of Ehlers–Danlos syndrome type IV, the vascular type. *New England Journal of Medicine*. 2000;342(10):673-80.
10. Chen FP. Term delivery after repair of a uterine rupture during the second trimester in a previously unscarred uterus: A case report. *The Journal of Reproductive Medicine*. 2007;52(10):981-3.
11. Aggarwal S, Jindal M, Minhas S. Case series on uterine rupture depicting the atypical presentations in the labour room. *International Journal of Reproduction, Contraception, Obstetrics and Gynecology*. 2021;10(12):4549-53.
12. Abdalla N, Reinholz-Jaskolska M, Bachanek M, Cendrowski K, Stanczak R, Sawicki W. Hemoperitoneum in a patient with spontaneous rupture of the posterior wall of an unscarred uterus in the second trimester of pregnancy. *BMC Research Notes*. 2015;8(1):1-3.
13. Chibber R, El-Saleh E, Fadhli RA, Jassar WA, Harmi JA. Uterine rupture and subsequent pregnancy outcome—how safe is it? A 25-year study. *The Journal of Maternal-Fetal & Neonatal Medicine*. 2010;23(5):421-4.
14. Abdulwahab DF, Ismail H, Nusee Z. Second-trimester uterine rupture: Lessons learnt. *The Malaysian Journal Of Medical Sciences*. MJMS. 2014;21(4):61.
15. Heemskerk SG, Ten Eikelder ML, Janssen CA. Uterine rupture in pregnancy after an intervention complicated by uterine perforation: Case report and systematic review of literature. *Sexual & Reproductive Healthcare*. 2019;19:9-14.

© 2022 Sreedhar and Antony ; This is an Open Access article distributed under the terms of the Creative Commons Attribution License (<http://creativecommons.org/licenses/by/4.0>), which permits unrestricted use, distribution, and reproduction in any medium, provided the original work is properly cited.