Case study

Second trimester Uterine Rupture of an Unscarred uterus in a Primigravida: A Case Report

Abstract

Spontaneous uterine rupture in the second trimester of an unscarred uterus is rare and carries severe risk to both mother and fetus compared to scarred uterus. A 32 years old primigravida at 18 weeks of gestation with a dichorionic- diamniotic twin pregnancy reported to the emergency department with pain in the epigastric region. Eight months back she underwent a diagnostic hysteroscopy and laparoscopy as a part of infertility work-up. She was diagnosed with rupture uterus by CT scan and emergency laparotomy was done with rupture repair. Second trimester uterine rupture in unscarred uterus is very rare, but life-threatening obstetrical emergency that should be considered as part of differential diagnosis for severe abdominal pain in early pregnancy.

Keywords : rupture uterus, spontaneous, unscarred uterus

Introduction

Spontaneous uterine rupture in the second trimester of an unscarred uterus is rare and carries severe risk to both mother and fetus compared to scarred uterus. The causes of rupture of unscarred uterus include grandmultipara, injudicious use of oxytocics, uterine anomalies, internal podalic version with breech extraction, external cephalic version, instrumentation like forceps application or vaccum extraction. A few cases of primary antepartum uterine rupture have been reported where no direct etiology is found. Pre-labour rupture of uterus is a rare identity. We present a rare case of spontaneous rupture at 18 weeks of gestation in a primigravida where no etiology was found.

Case report

A 32 years old primigravida at 18 weeks of gestation with a dichorionic- diamniotic twin pregnancy reported to the emergency department with pain in the epigastric region. Eight months back she underwent a diagnostic hysteroscopy and laparoscopy as a part of infertility work-up. No electrosurgical procedures were performed. On examination, her blood pressure was 116/60 mm Hg and her pulse rate was 138 beats per minute. On abdominal examination uterine fundus was tender. Sonography showed twin pregnancy with absent cardiac activity of both fetuses with free fluid in the abdomen. Ultrasonographic findings were suspicious of uterine rupture but there was no correlation with her history given her parity status and gestational age. Hence CT abdomen(Fig a) was done and it showed loss of myometrial architecture with fluid in the abdomen suggestive of uterine rupture. She was stabilized and taken up for an emergency laparotomy which revealed massive hemoperitoneum with both the fetuses in the abdominal cavity. A uterine rupture of 6 cm length was noted in the fundal region (Fig b) and was reapaired. Patient was transfused with 2 units of packed red cells. Post operative period was uneventful. She was subjected for genetic workup. There

UNDER PEER REVIEW

was no history suggestive of collagen disease in the patient and also she was tested negative for Ehler-Danlos syndrome.

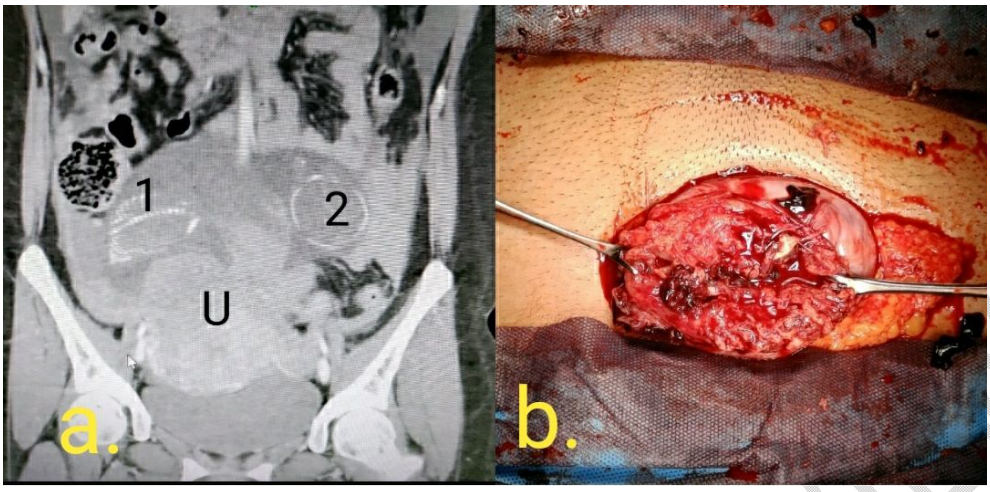

Figure(a): CT abdomen and pelvis showing Fetus 1 and fetus 2 in the abdominal cavity and the ruptured uterine myometrium retracting towards the pelvic cavity.

Figure (b): Uterine fundal rupture of about 6 cm length.

Discussion

Overall rupture uterus is estimated to occur 1 in 5700 to 1 in 20000 pregnancies. The most common site of rupture in an unscarred uterus is the fundus.[1]

Rare causes of uterine rupture in an unscarred uterus reported in literature are adenomyosis, pelvic radiation, connective tissue disease and chronic steroid use. Eleven cases of uterine rupture in the second trimester of unscarred uterus were reported in which 5 cases had placenta percreta, 2 had myomectomy, 2 had uterine anomalies and 2 had no risk factor.[2]

Uterine perforation during operative hysteroscopy or even by uterine sounding has been associated with the possibility of uterine rupture.[3]

In the current case, the patient had diagnostic hysteroscopy where no electrosurgical procedures were performed and there was no history of perforation. The cause of rupture in our case is not define. One possibility could be inherited collagen disease. Our patient underwent genetic testing for the same and was negative.

Fang-Peng et al, 2007 reported a successful term delivery following spontaneous 2nd trimester uterine rupture and surgical repair. Child-birth after uterine rupture require great deal of attention. They carry a high risk of recurrent uterine rupture. Successful near-term deliveries have been reported with meticulous tertiary level antenatal care and planned operative delivery. [4]

Conclusion

UNDER PEER REVIEW

Second trimester uterine rupture in unscarred uterus is very rare, but life-threatening obstetrical emergency that should be considered as part of differential diagnosis for severe abdominal pain in early pregnancy. Pre-labour rupture of uterus in a primigravida is a rare identity. A risk of recurrent rupture is described up to 22-100% of cases mainly when it occurs at the fundus.[5] It is important to counsel patients who have not completed family. Although uterine rupture occurs more commonly in multiparous women, it cannot be assured that the nulliparous women are immune to rupture in the second trimester of pregnancy.

References

1. Zwart JJ, Richters JM, Öry F, De Vries JI, Bloemenkamp KW, Van Roosmalen J. Uterine rupture in the Netherlands: a nationwide population-based cohort study. BJOG: An International Journal of Obstetrics & Gynaecology. 2009 Jul;116(8):1069-80.

2. Damiani GR, Gaetani M, Landi S, Lacerenza L, Barnaba M, Spellecchia D, Pellegrino A. Uterine rupture in a nulliparous woman with septate uterus of the second trimester pregnancy and review in literature. International Journal of Surgery Case Reports. 2013 Jan 1;4(3):259-61.

3. Heemskerk SG, Ten Eikelder ML, Janssen CA. Uterine rupture in pregnancy after an intervention complicated by uterine perforation: case report and systematic review of literature. Sexual & Reproductive Healthcare. 2019 Mar 1;19:9-14.

4. Chen FP. Term delivery after repair of a uterine rupture during the second trimester in a previously unscarred uterus: a case report. The Journal of Reproductive Medicine. 2007 Oct 1;52(10):981-3.

5.Chibber R, El-Saleh E, Fadhli RA, Jassar WA, Harmi JA. Uterine rupture and subsequent pregnancy outcome–how safe is it? A 25-year study. The Journal of Maternal-Fetal & Neonatal Medicine. 2010 May 1;23(5):421-4.

UNDER PEER REVIEW