

Brain Metastasis in a Case of Osteosarcoma

ABSTRACT

INTRODUCTION: Sarcomas are responsible for about 3% of brain metastases, and brain metastases are found in 1–8% of patients of sarcoma patients. One of the most prevalent malignant bone tumors in adolescents and children is osteosarcoma, which only rarely spreads to the central nervous system. We report here a rare case of an 8-year-old boy with brain metastasis from osteosarcoma of the foot.

CASE REPORT: An 8-year-old male presented with osteosarcoma of the foot and brain because of metastasis from the primary tumor. After diagnosis by CT scan and PET scan, the patient underwent occipital- parietal craniotomy with gross total excision of the skull along with pirogoff's amputation for the foot. On histopathological examination, the diagnosis of osteosarcoma was confirmed, and patient was started on chemotherapy.

CONCLUSION: Brain metastasis with osteosarcoma is a rare condition. However, aggressive craniotomy and excision of the primary tumor with timely chemotherapy can result in long term survival of patient. However, a proper protocol must be followed to achieve this.

KEY WORDS

Osteosarcoma, Brain Metastasis, Craniotomy, Amputation

INTRODUCTION

Sarcomas are responsible for about 3% of brain metastases, and brain metastases are found in 1–8% of patients of sarcoma patients [1,2]. It is very uncommon in children to find the involvement of the central nervous system (CNS) in soft tissue and bone sarcomas. For example, Wiens and Hattab conducted a study in a large cohort of children with CNS tumors in which there were only twenty-six patients with solid nonhematopoietic CNS metastases, accounting for 2.3 percent of the total, and bone and soft tissue tumors were the second most common cause of CNS metastases after kidney and adrenal gland tumors [3]. These figures give an estimation of how rare the occurrence of brain metastases is from soft tissue and bone neoplasms are in the pediatric population.

One of the most prevalent malignant bone tumors in adolescents and children is osteosarcoma, which only rarely spreads to the central nervous system. This neoplasm spreads through a hematogenous route, with the lungs and bones being the primary targets [4]. In a large series of osteosarcoma patients, 90 percent of those who relapsed had lung metastases, and around half of those who relapsed had bone lesions [5]. Brain metastases were found in these patients only through autopsy or as a late, pre-terminal event. This pattern may be changing as patients live longer in the current chemotherapeutic age [7]. Brain metastases have been detected in a few of people with osteosarcoma. The onset of brain metastases is rare and frequently is the last stage of the clinical history because long-term survival in these patients is very less [8]. We report here a rare case of an 8-year-old boy with brain metastasis from osteosarcoma of the foot.

CASE REPORT

An 8-year-old male child presented to the outpatient department with Swelling over the dorsum of right foot since April 2019 and Swelling over the occipital-parietal region since August 2019. The child was diagnosed with osteosarcoma on a true cut biopsy elsewhere, for which he received 4 cycles of chemotherapy with the last cycle being given in December 2019. Both the swellings were gradually progressive and increased in size over the last few months, and the child presented with diplopia and squint in the left eye since December 2019. CT Brain was done to see for bony extension of the occipital-parietal swelling which confirmed the diagnosis of osteosarcoma of the brain [Figure 1].

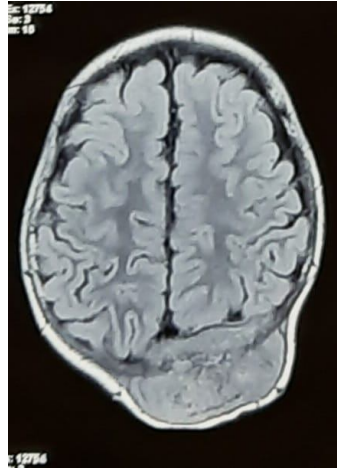


Figure 1: CT scan of the brain showing a occipital-parietal tumor.

PET scan was done which was suggestive of metastatic parieto-occipital swelling of the brain from primary right foot osteosarcoma with no extension of the metastasis elsewhere in the body. Patient was symptomatic for metastasis from the primary osteosarcoma of the foot. He was posted for occipital-parietal craniotomy with gross total excision of skull osteosarcoma along with right foot amputation. A circular incision was taken, tumor was separated from overlying skin, and 2cm margin dissection was done from all around the tumor [Figure 2], and underlying bone which was found to be involved, was excised along with the tumor [Figure 3]. One satellite nodule was present about 3cm from left margin of the tumor, which was removed, hemostasis was achieved, and the bone defect was covered with a titanium mesh of size of 10 x 10 cm [Figure 4], a 10 number drain was placed, and closure was done in layers.

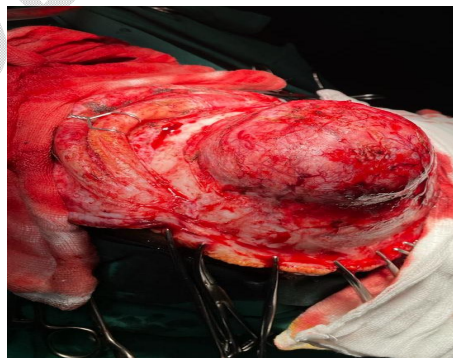


Figure 2: Exposure of the tumor after incision and soft tissue dissection.

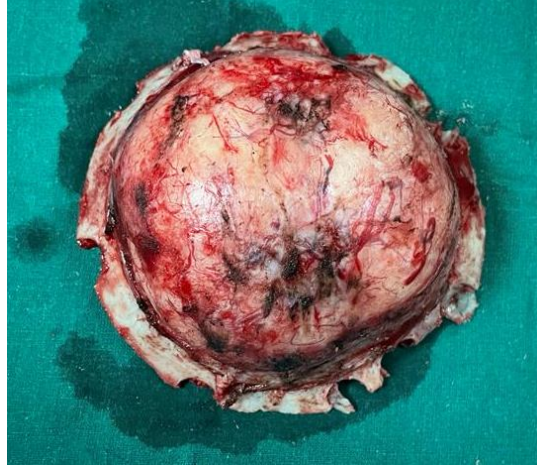


Figure 3: Intra-operative specimen of the excised tumor.

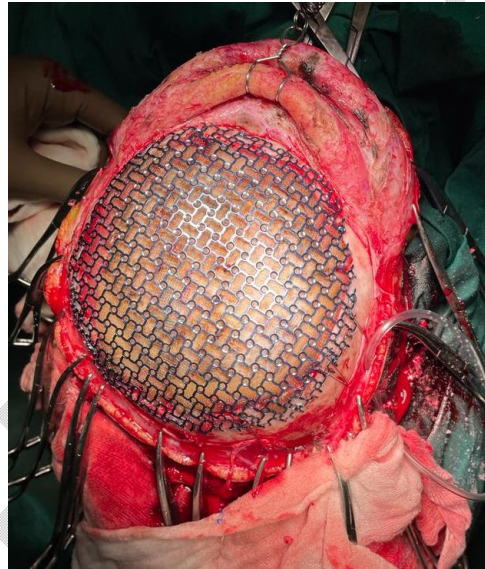


Figure 4: Titanium mesh used to cover the bony defect after tumor excision.

The tumor of the foot was addressed by a Pirogoff's hindfoot amputation where the talus and tarsal bones were removed followed by calcaneal osteotomy of around 70 degrees with rotation of the calcaneum with the posterior part facing downwards [Figure 5]. The gross specimen of the brain and of the foot was sent for histopathological analysis where a diagnosis of osteosarcoma of foot and metastatic deposit of osteosarcoma in occipital-parietal region was confirmed. Post-operatively patient was started on chemotherapy regime of iphosphamide, cisplatin and Adriamycin and had been advised for regular follow-ups on which no other secondary metastasis was found on diagnostic investigations.

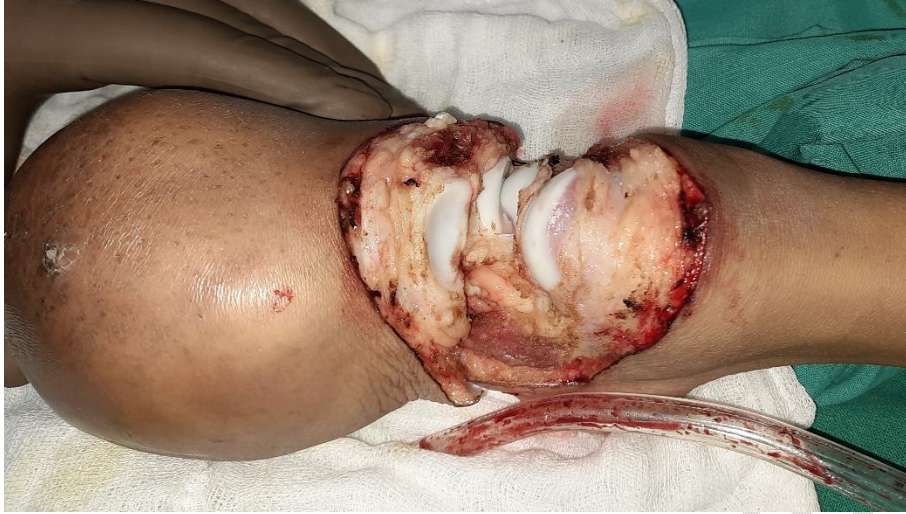

Figure 5: Pirogoff's amputation of the hind foot was preformed for foot osteosarcoma.

DISCUSSION

Brain metastasis is uncommon in osteosarcoma, with rates ranging from 2 percent to 6.5 percent [7, 9, 10]. After lung metastasis, brain metastasis is almost always discovered. Brain metastasis is most likely the result of lung metastasis. In individuals who have developed lung metastasis, the likelihood of brain metastasis should always be addressed. Systemic chemotherapy has been found to alter the pattern of metastasis, resulting in an increase in the incidence of extrapulmonary metastasis. In 12.5 percent of patients with lung metastasis, brain metastasis was discovered [10]. In patients with pulmonary metastases, a brain CT or MRI should be performed on a regular basis.

The prognosis of patients with brain metastasis of osteosarcoma is very poor. As for long term survivors of brain metastasis, only several such patients have been reported [3,7,9]. The absence of active pulmonary metastasis at the onset of brain metastasis and the complete removal of all brain metastases by craniotomy are common to the long-term survivors. In the present patient as well, no active pulmonary metastasis was found when the brain metastasis was detected. **Those patients without active pulmonary metastasis at the onset of brain metastasis have the possibility of long-term survival. In such patients, therefore, it would be worthwhile to perform craniotomy aggressively along with excision of the primary tumor [11].**

Long-term survival was obtained in our patient after his craniotomy and excision of primary tumor due to timely intervention. Hence, a protocol for aggressive craniotomy with excision of primary tumor along with chemotherapy regime can be proposed for long term survival of patients.

CONCLUSION

Brain metastasis with osteosarcoma is a rare condition. However, aggressive craniotomy and excision of the primary tumor with timely chemotherapy can result in long term survival of patient. However, a proper protocol must be followed to achieve this.

Ethical Approval:

As per international standard or university standard written ethical approval has been collected and preserved by the author(s).

CONSENT

An informed patient consent was taken from the patient for the procedure and publication of the case report.

REFERENCES

1. Fox B. D., Patel A., Suki D., Rao G. Surgical management of metastatic sarcoma to the brain: clinical article. *Journal of Neurosurgery*. 2009;110(1):181–186.
2. Salvati M., D'Elia A., Frati A., Santoro A. Sarcoma metastatic to the brain: a series of 35 cases and considerations from 27 years of experience. *Journal of Neuro-Oncology*. 2010;98(3):373–377.
3. Wiens A. L., Hattab E. M. The pathological spectrum of solid CNS metastases in the pediatric population: clinical article. *Journal of Neurosurgery: Pediatrics*. 2014;14(2):129–135.

4. Rosen G: Spindle cell sarcoma-osteogenic sarcoma. In: Sutow WW, Fernbach DJ, Vietti TJ (eds) *Clinical Pediatric Oncology*. St. Louis, C. V. Mosby, 1984.
5. Jaffe N: Advances in the management of malignant bone tumors in children and adolescents. In: *Pediatric Clinics of North America*. Philadelphia, W. D. Sanders, 1985.
6. Sawaya R, Bindal RK Metastatic brain tumors. In: Kaya AH, Laws ER Jr (eds) *Brain tumors. An encyclopedic approach*. Churchill Livingstone, Edinburgh, pp 923–946
7. Baram TZ, van Tassel P, Jaffe NA Brain metastases in osteosarcoma: incidence, clinical and neuroradiological findings and management options. *J Neurooncol* 6:47–52.
8. Doval DC, Chacko M, Sinha R, Choudhury KD, Sharma A, Rao A, Jaggi RS, Mehta A. A rare case of brain metastasis in a patient with osteosarcoma. *South Asian J Cancer*. 2017 Jan-Mar;6(1):36-37.
9. Marina NM, Pratt CB, Shema SJ, et al. (1993) Brain metastases in osteosarcoma: report of a long-term survivors and review of the St. Jude Children's Research Hospital experience. *Cancer* 71:3656– 3660.
10. Curless RG, Toledano SR, Ragheb J, et al. (2002) Hematogenous brain metastasis in children. *Pediatr Neurol* 26:219–221.
11. Shweikeh F, Bukavina L, Saeed K, Sarkis R, Suneja A, Sweiss F, Drazin D. Brain metastasis in bone and soft tissue cancers: a review of incidence, interventions, and outcomes. *Sarcoma*. 2014;2014:475175.