

Case Report

A Case Report of a Muroid Cyst of the Penis

Abstract:

Penile cysts are benign tumors that are incredibly rare. It can be difficult to make a clinical or pathological diagnosis of them. There have only been around 200 cases of this reported in the literature. Even though the most of them are present from birth and asymptomatic, they usually don't become apparent until adolescence or maturity. These disorders seldom impair sexual function. This case involves a 57-year-old man with a 2.5 cm nodule on the prepuce (ventral surface) that developed two years ago and affected his ability to perform sexual acts. After cutting out the lesion, a penile muroid cyst was discovered by histological investigation. The patient's sexual function had returned to normal at the six-month checkup, and there had been no recurrence.

Key words: Muroid Cyst, Penis, General Surgery

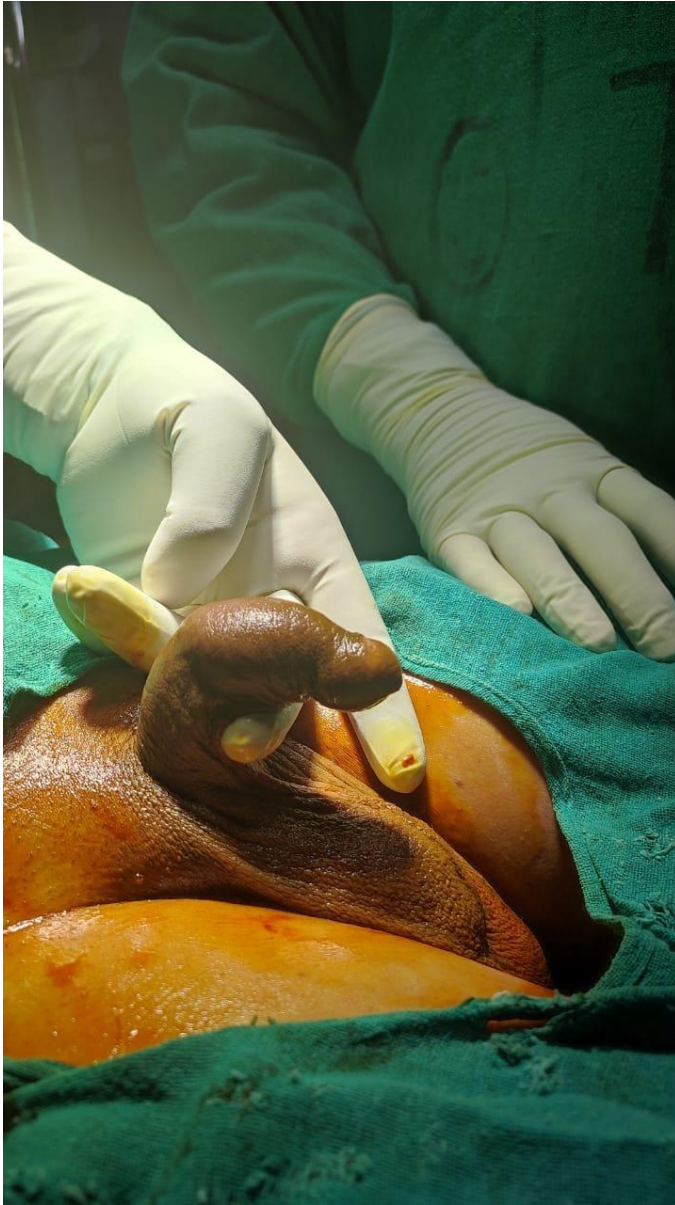
Introduction

The genital tubercle, which has two urethral folds and the scrotal swellings that converge in the middle to create the scrotum, is the developmental origin of the male external genitalia. Penile, scrotal, and perineal raphe are used to identify the center of fusion. Cysts in the midline may arise as a result of an embryological abnormality or the median raphe closing prematurely, giving rise to the term "median raphe cyst" (MRC). But other explanations for the pathogenesis exist as well.¹ The condition was initially described by Mermet in 1895². The cyst can be observed anywhere along the midline, from the glans to the anus³⁻⁵. Surgery, urology, pediatrics, and infrequently dermatology sees cases of MRC, an uncommon benign lesion⁵⁻⁷. Penile muroid cysts are an uncommon benign condition. The ectopic urethral mucosa that was sequestered throughout embryologic development is where cysts most frequently occur. It is connected with mucous cells or glands, stratified columnar epithelium is usually found during a cyst's

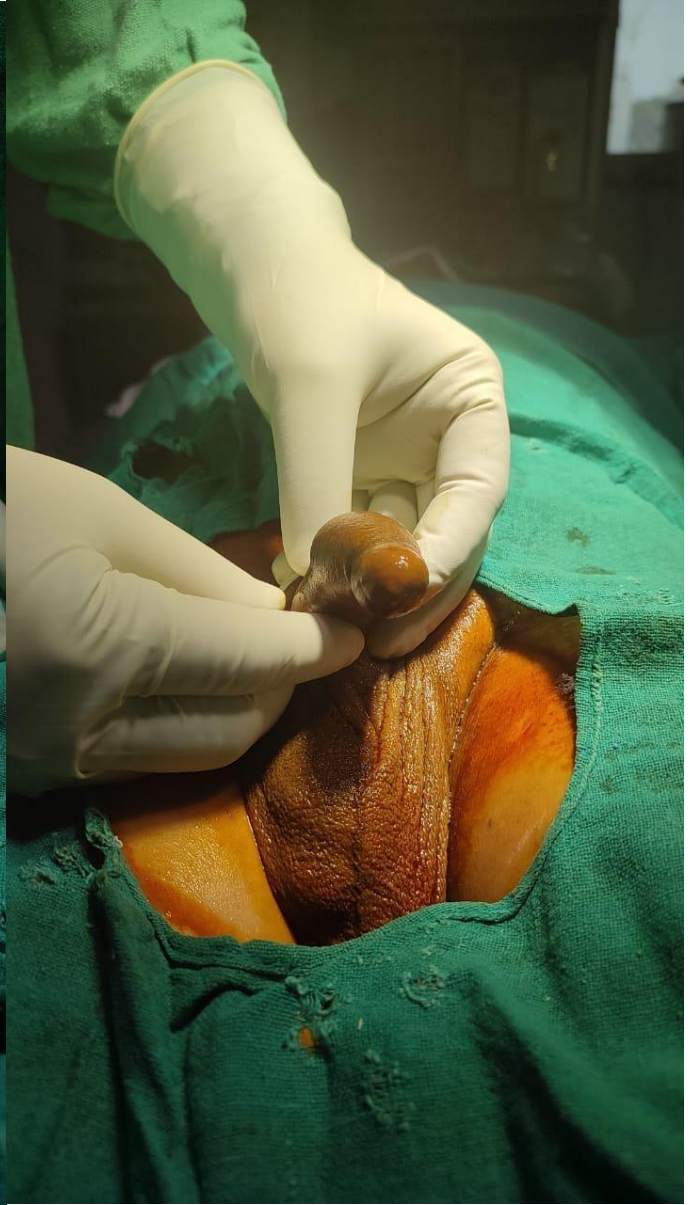histopathologic investigation.⁸The cysts are often tiny, floppy lumps that may move freely. They are often asymptomatic until an illness or a challenging coitus complicates things.⁹

Case Presentation

After taken written informed consent from patients for Research and publication purpose as well as ethical clearance taken from institute. In the last two years, a 57-year-old man has had a gradually growing nodule on the foreskin of his penis, which has been interfering with his sexual function for the last three months [Fig-1a and 1b]. There had been no previous surgery, illness, or trauma. We discovered a 2.5 × 2.5 cm soft, sensitive, and cystic nodule on the prepuce (ventral surface) during physical examination [Fig-1a and 1b]. USG bilateral inguinal and penis collection reveals a hypoechoic lesion of approximately (21x10) mm with interior bright echoes. All standard investigations came back normal. Under spinal anesthesia, **Surgical excision of lesion is the treatment** of choice and submitted for histopathologic examination (Fig-2a , 2b, and 3a). Histopathologic investigation revealed a cyst wall with a thin layer of squamous epithelium (Fig-3b) There weren't any surgical problems, and the patient was discharged on postoperative day 3. Client was seen by the surgical outpatient department every 15 days and there was no reappearance (Fig 4a, and Fig 4b) or pain during sex.

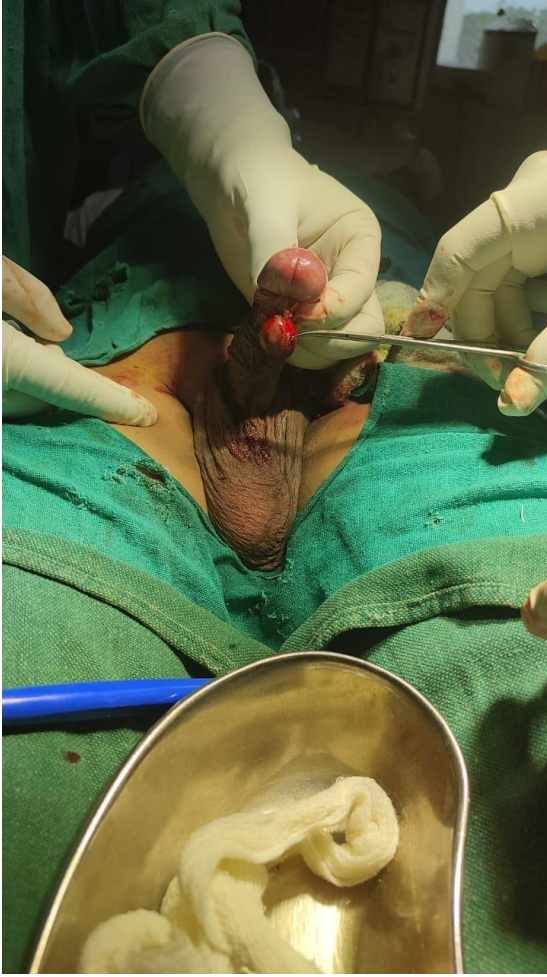

(1a)

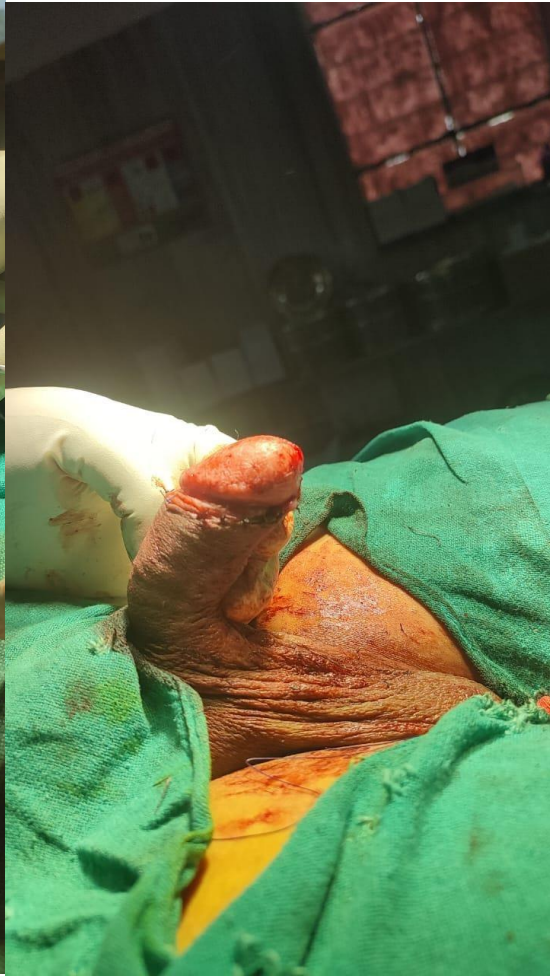

(1b)

Fig 1(a-b): Morphology of Mucoïd Cyst of the Penis

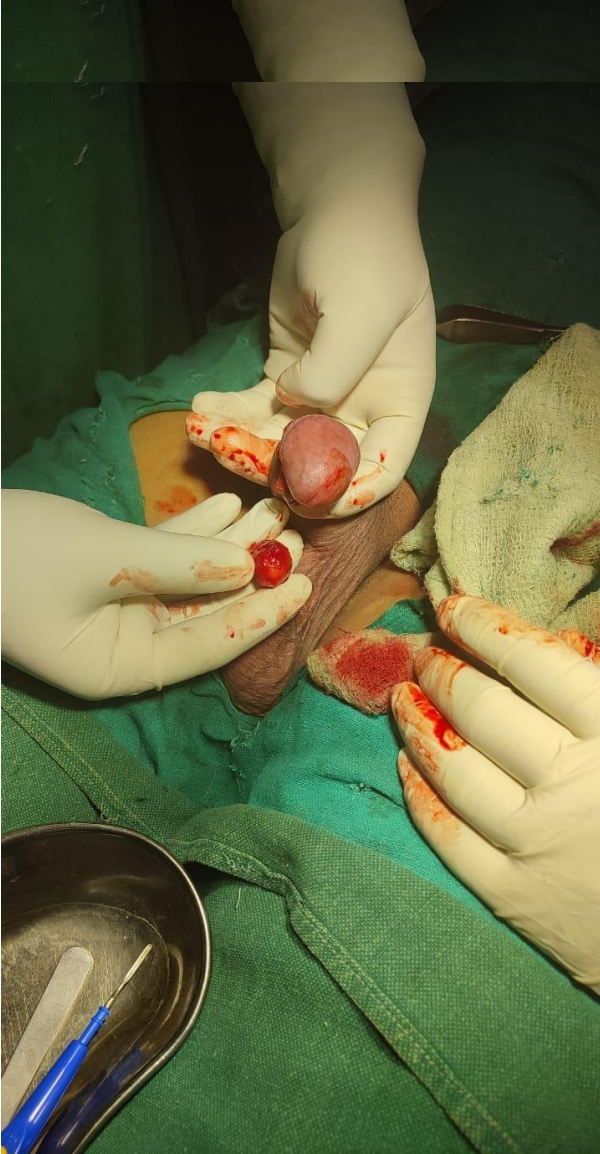

(2a)

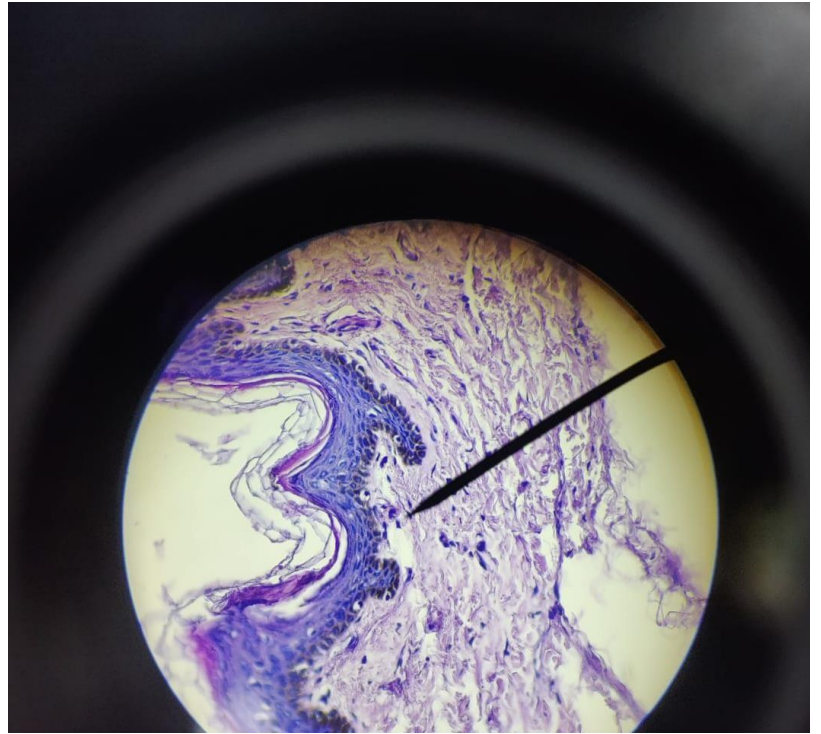


(2b)

Fig -2 (a-b): Operative phase



(3a)



(3b)

Fig -3(a-b)

Histopathology Section shows evidence of cyst lined by squamous epithelium with on fragment of fibrocollagenous stroma also seen covered by squamous epithelium.

□

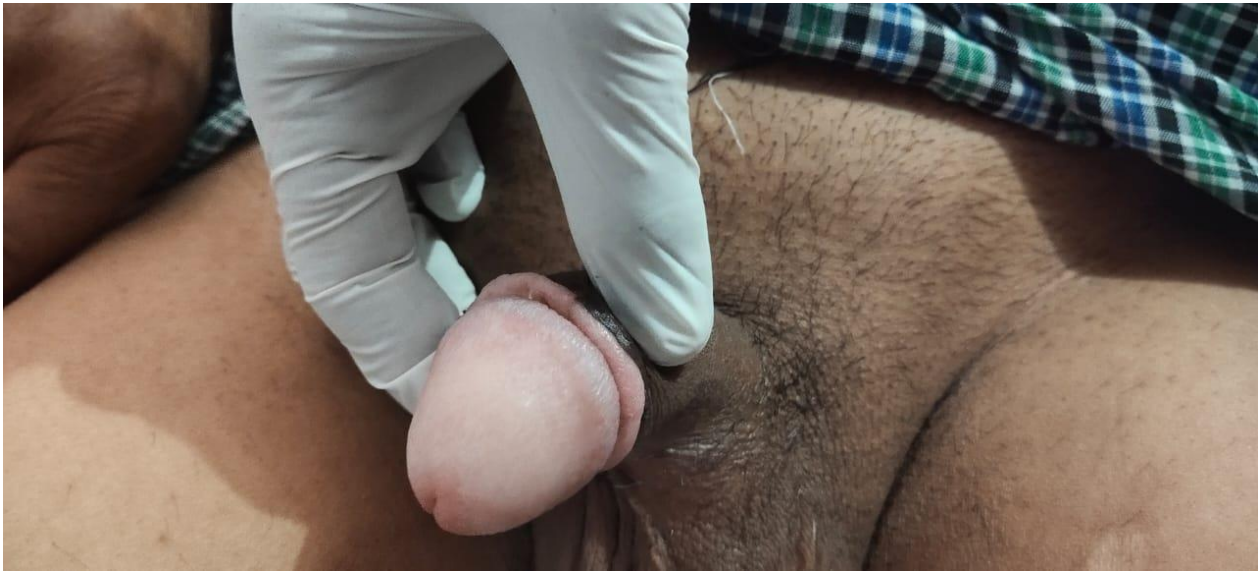
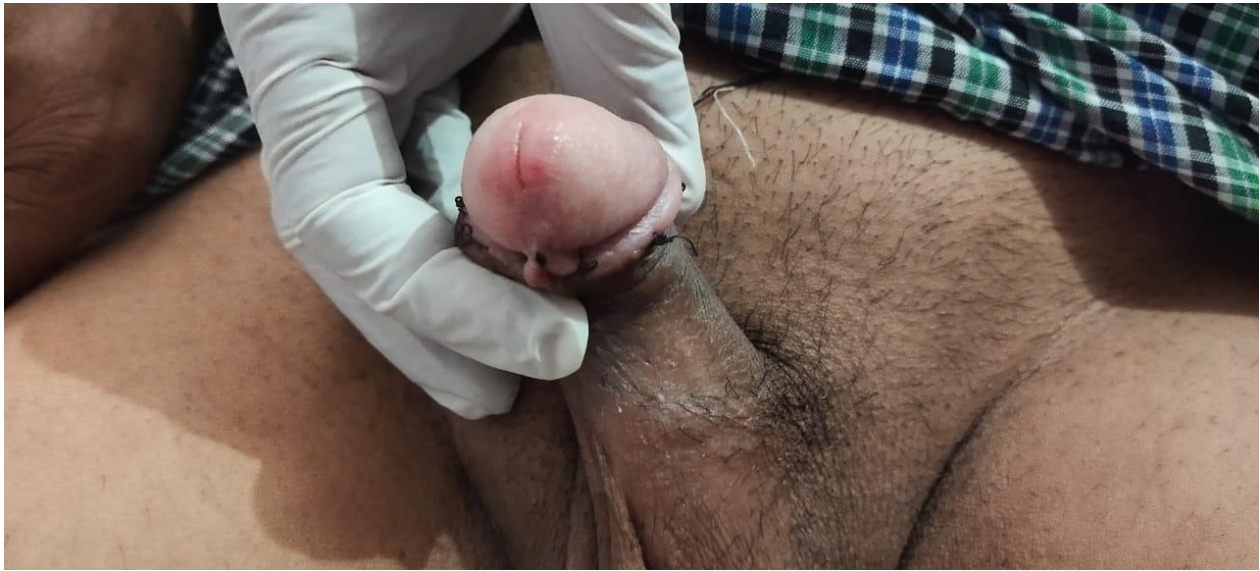
Fig-4(a)



4(b)

Fig -4 (a-b) : Post operative phase

Discussion:

Mucus penile cyst is a rare benign disease that mostly affects young men on the ventral aspect of the glans penis. Epidermal cysts, lipomas, steatocystomas, dermoid cysts, pilonidal cysts, Tyson gland cysts, and urethral diverticula are all differential diagnoses.² Various terminology, including mucus cyst of the penis, genitoperineal cyst of the median raphe, parameatal cyst, hydrocystoma, and apocrine cystadenoma of the penile shaft, should be considered synonymous.^{1,15,16} They are midline cysts that can be found anywhere from the anus to the urinary meatus. The majority of them are present from birth, however they are generally not identifiable until adolescence or manhood. The cysts form mostly on the penile ventral side, near the glans. They are usually asymptomatic, but might be worsened by infection, trauma, or making coitus difficult, as in the case of the patient in this report. Excision surgery is necessary.¹⁰ Excision of lesion results in positive outcomes with no signs of recurrence at follow-up intervals of six months¹¹, one year^{12, 13} and four years¹⁴. In a case series by Asarch et al., they noted recurrence in one of six patients after five years, and the cyst was re-excised with no subsequent recurrence⁷. One of the patients treated by Shao et al. after excision developed a fistula⁵. In a 14-year retrospective investigation, Matsuyama et al. found no instances of recurrence following treatment³.

Conclusion:

Penile cysts are an uncommon condition that are present from birth but only become apparent in adolescence. The cyst can appear anywhere from the glans to the anus along the midline. The histological confirmation of the clinical diagnosis. Excision is the treatment of choice with the lowest probability of recurrence.

Ethical Approval:

As per international standard or university standard written ethical approval has been collected and preserved by the author(s).

Consent

As per international standard or university standard, patient (s) written consent has been collected and preserved by the author(s).

Notes:

Financial or Other Competing Interests

None.

Reference:

1. Otsuka T, Ueda Y, Terauchi M, Kinoshita Y. Median raphe (parameatal) cysts of the penis. *J Urol*. 1998;159(6):1918–20.
2. Mermet P. Congenital cysts of the genitoperineal raphe. *Rev Chir*. 1895;15: 382–435.
3. Matsuyama S, Matsui F, Yazawa K, Matsumoto F, Shimada K, Matsuoka K. Long-term follow-up of median raphe cysts and parameatal urethral cysts in male children. *Urology*. 2017; 101:99–103.
4. Navalon-Monllor V, Ordone-Saiz MV, Ordone-Dominguez F, Sabater-Marco V, Pallas-Costa Y, Navalon-Verdejo P. Median raphe cysts in men: presentation of our experience and literature review. *Actas Urol Esp*. 2017;41(3):205–9.
5. Shao IH, Chen TD, Shao HT, Chen HW. Male median raphe cysts: serial retrospective analysis and histopathological classification. *Diagn Pathol*. 2012; 7:121.
6. Nagore E, Sanchez-Motilla JM, Febrer MI, Aliaga A. Median raphe cysts of the penis: a report of five cases. *Pediatr Dermatol*. 1998;15(3):191–3.
7. Asarch RG, Golitz LE, Sausker WF, Kreye GM. Median raphe cysts of the penis. *Arch Dermatol*. 1979;115(9):1084–6.
8. Cole LA, Helwig EB. Muroid cysts of the penile skin. *J Urol*. 1976; 115:397– 400.
9. Velasco E. Muroid cyst of penis skin [in Spanish] *Urol Colomb*. 1993; 3:99– 104.
- 10 Cardoso R, Freitas JD, Reis JP, et al. Median raphe cyst of the penis. *Dermatol Online J*. 2005; 11:37.
- 11 Arrabal-Martin M, Jimenez-Pacheco A, Arrabal-Polo M, Arias-Santiago S. Median raphe cyst of the penis: diagnosis and therapeutic approach [abstract]. *J Am Acad Dermatol*. 2012;66(4): AB38.
- 12 Deliktas H, Sahin H, Celik OI, Erdogan O. Median raphe cyst of the penis. *Urol J*. 2015;12(4):2287–8
- 13 Parnham AS, Freeman A, Kirkham A, Muneer A. An unusual swelling in the male

perineum. BMJ Case Rep. 2015;2015: bcr2014206199

14 Unal B, Bassorgun C, Karanis M, Elpek G. Perianal median raphe cyst: a rare lesion with unusual histology and localization. Case Rep Dermatol Med. 2015; 2015:3

15. De Mendonça RR, Silva II JL, Wroclawski ML, Sakuramoto PK, Pompeo AC. Muroid cyst of the penis: case report and literature review. Canadian Urological Association Journal. 2010;4(6):E155-7.

16. Malhotra MK, Singh KB, Garg P, Sharma P, Singh K. Muroid cyst of the penis: a case report. Journal of Clinical & Diagnostic Research. 2015 Feb 1;9(2).