

A Case Report of a Mucoïd Cyst of the Penis

Abstract:

Penile cysts are benign tumors that are incredibly rare. A clinical or pathological diagnosis of them is fairly challenging. Less than 200 cases of this have been documented in the literature. Even though the most of them are asymptomatic and present from birth, they are typically only noticeable in adolescence or adulthood. These disorders seldom impair sexual function. This case involves a 57-year-old man with a 2.5 cm nodule on the prepuce (ventral surface) that developed two years ago and affected his ability to perform sexual acts. After cutting out the lesion, a penile mucoïd cyst was discovered by histological investigation. The patient's sexual function had returned to normal at the six-month checkup, and there had been no recurrence.

Introduction

Penile mucoïd cysts are an uncommon benign condition. The ectopic urethral mucosa that was sequestered throughout embryologic development is where cysts most frequently occur. Whether or whether it is connected with mucous cells or glands, stratified columnar epithelium is usually found during a cyst's histopathologic investigation.¹The cysts are often tiny, floppy lumps that may move freely. They are often asymptomatic until an illness or a challenging coitus complicates things.²

Case Report **you should have permission from the hospital and patient consent ethically?**

In the last two years, a 57-year-old man has had a gradually growing nodule on the foreskin of his penis, which has been interfering with his sexual function for the last three months [Fig-1, Fig-2]. There had been no previous surgery, illness, or trauma. We discovered a 2.5 × 2.5 cm soft, sensitive, and cystic nodule on the prepuce (ventral surface) during physical examination [Fig-1, Fig-2]. USG bilateral inguinal and penis collection reveals a hypoechoic lesion of approximately (21x10) mm with interior bright echoes. All standard investigations came back normal. Under spinal anesthesia, the lesion was excised by circumcision and submitted for histopathologic examination (Fig-3, Fig-4, Fig-5) (Fig-5). Histopathologic investigation revealed a cyst wall with a thin layer of squamous epithelium (Fig-6) There weren't any surgical problems, and the patient was discharged on postoperative day 3. Client was seen by the surgical outpatient department every 15 days and there was no reappearance (Fig 7, Fig 8) or pain during

sex. Mucus penile cyst is a rare benign disease that mostly affects young men on the ventral aspect of the glans penis. Epidermal cysts, lipomas, steatocystomas, dermoid cysts, pilonidal cysts, Tyson gland cysts, and urethral diverticulums are all differential diagnoses. 2 Several terminologies should be regarded synonymous, including mucus cyst of the penis, genitoperineal cyst of the median raphe, parameatal cyst, hydrocystoma, and apocrine cystadenoma of the penile shaft³ They are midline cysts that can be found anywhere from the anus to the urinary meatus. The majority of them are present from birth, however they are generally not identifiable until adolescence or age.⁴The cysts form mostly on the penile ventral side, near the glans. They are usually asymptomatic, but might be worsened by infection, trauma, or making coitus difficult, as in the case of the patient in this report. Excision surgery is necessary.⁴

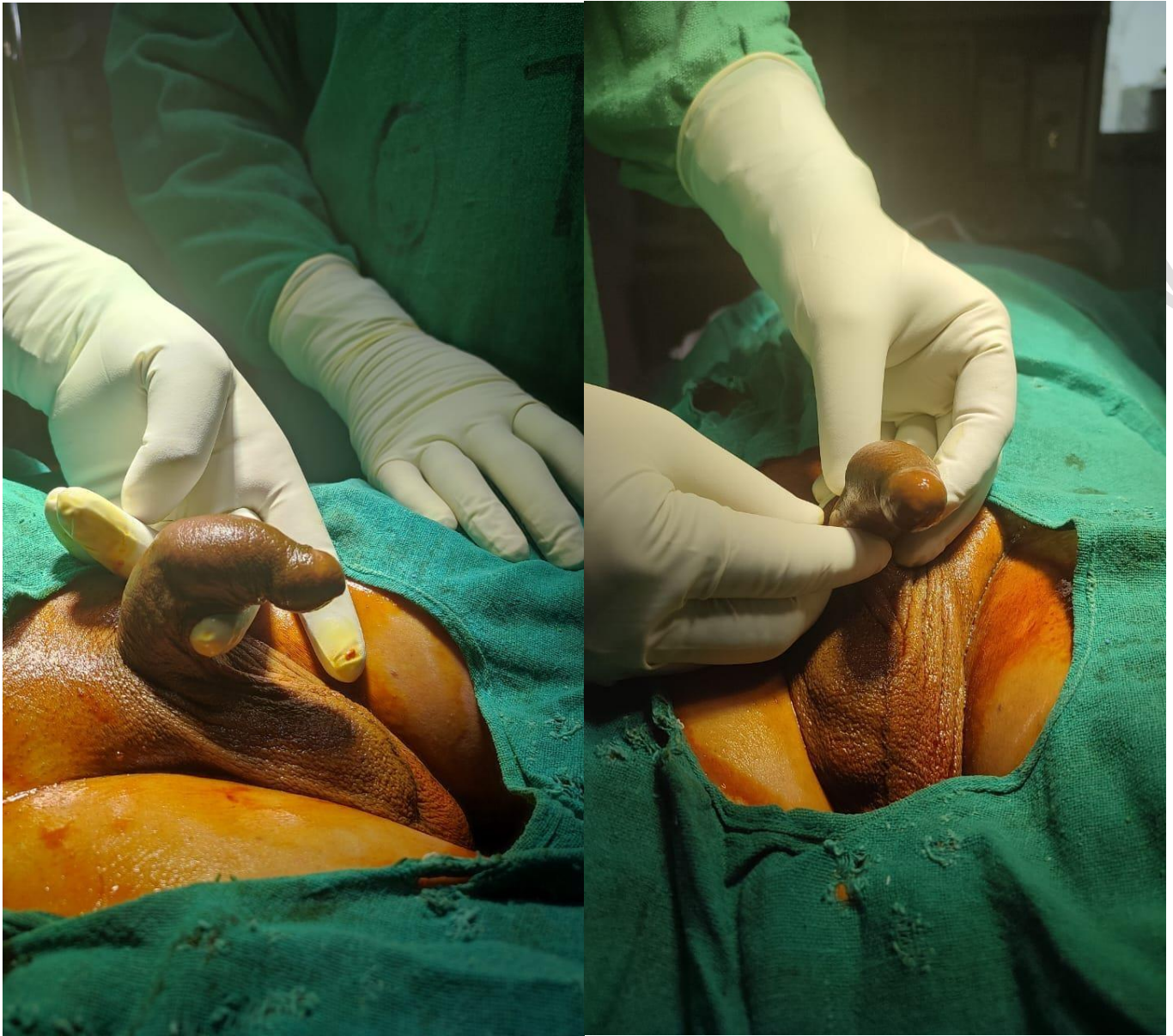


Fig-1, 2. Morphology of Mucoïd Cyst of the Penis

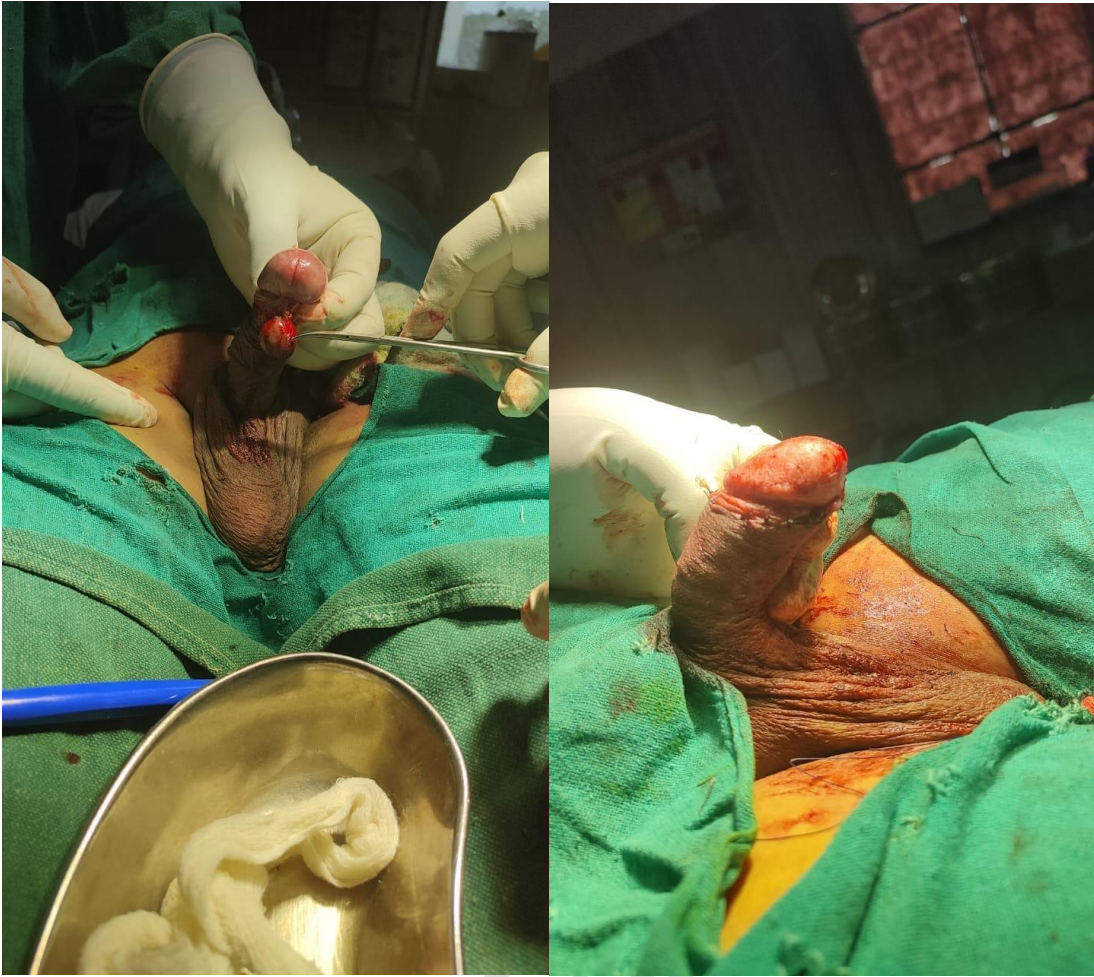

Fig -3,4: Operative phase

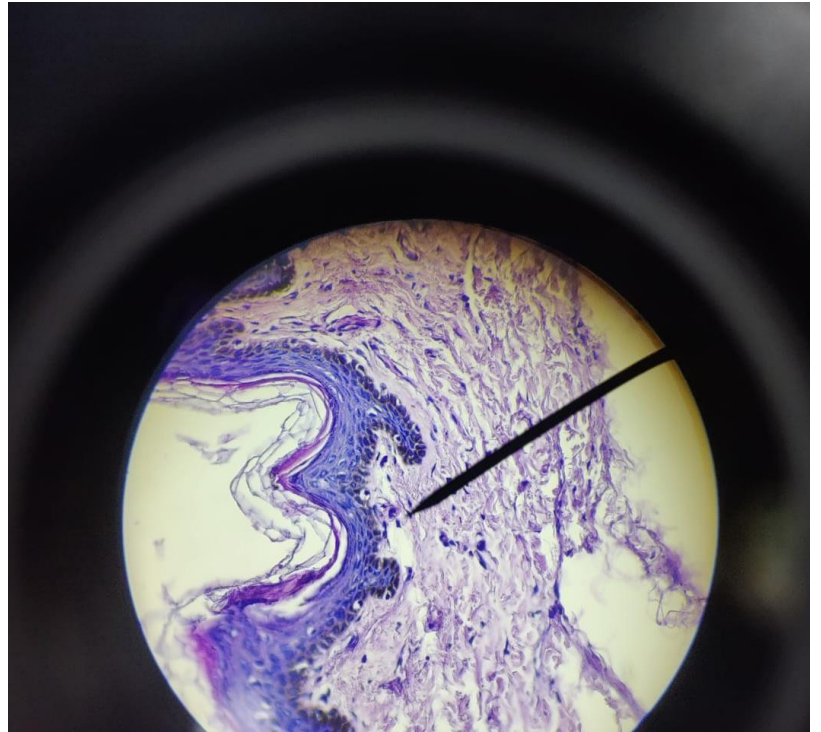
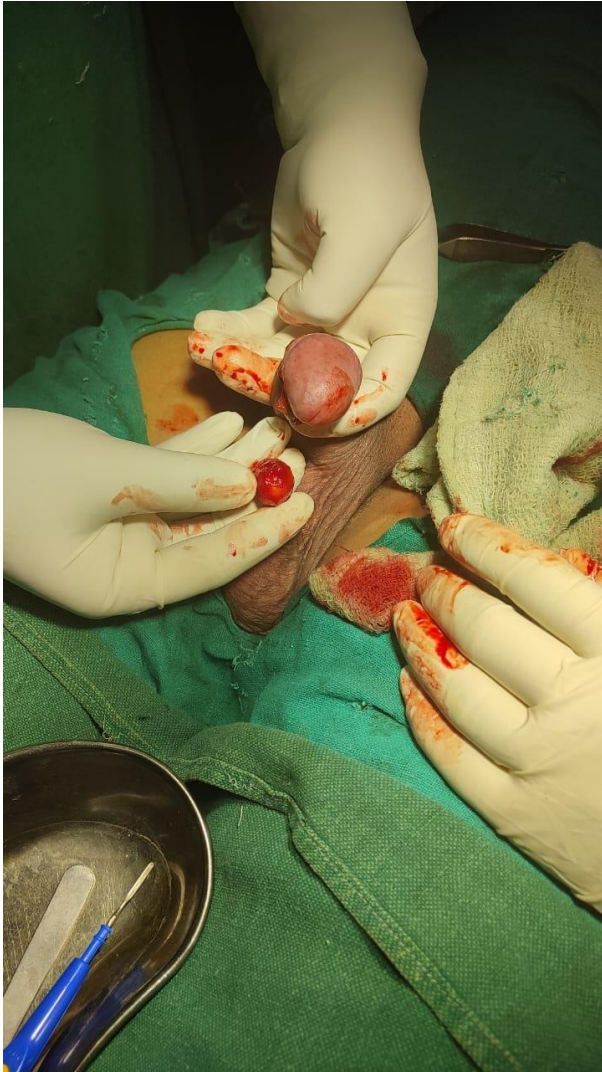

Fig-5,6: Histopathology Section shows evidence of cyst lined by squamous epithelium with on fragment of fibrocollagenous stroma also seen covered by squamous epithelium.

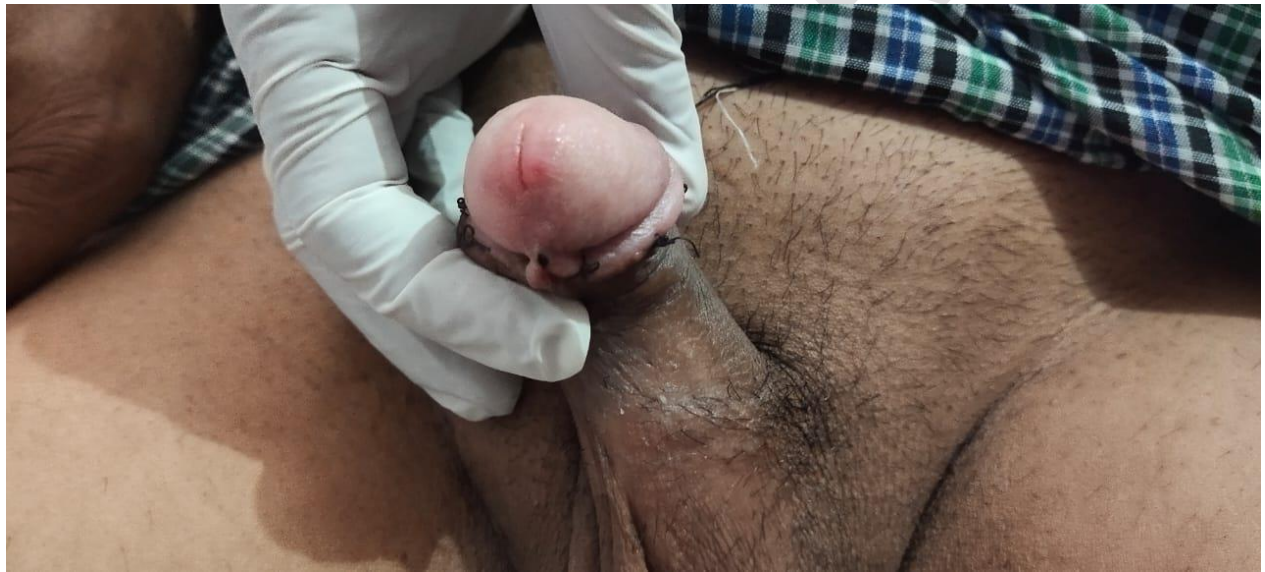
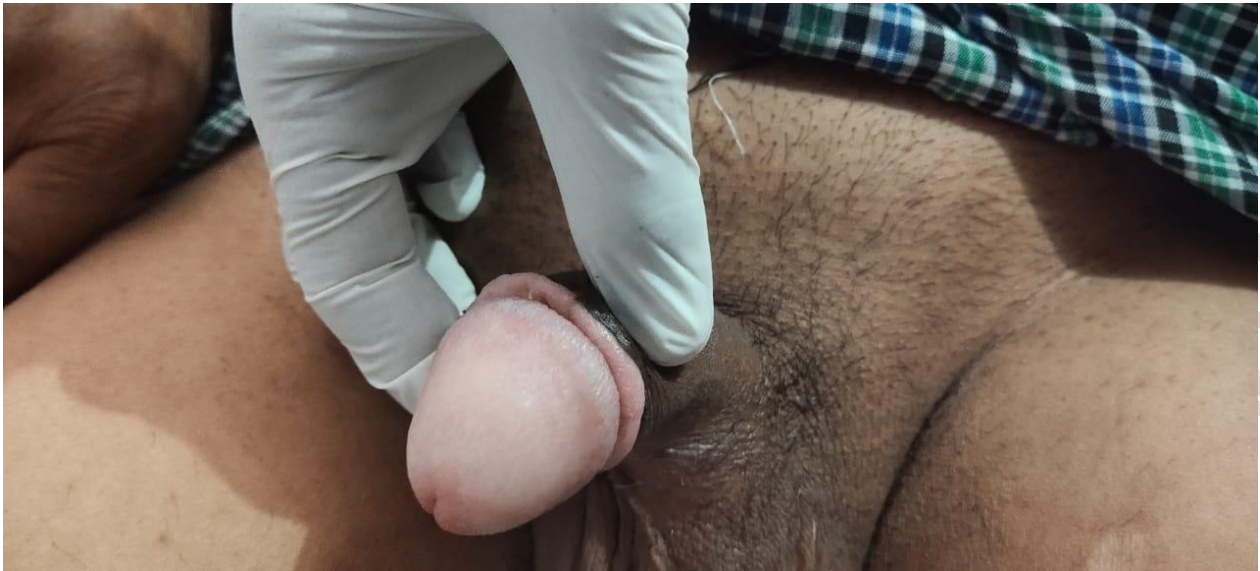
Fig -7, 8: Post operative phase

Discussion:

Mucus penile cyst is a rare benign disease that typically affects young men on the ventral aspect of the glans penis. Epidermal cysts, lipomas, steatocystomas, dermoid cysts, pilonidal cysts, tyson gland cysts, and urethral diverticulums are among the differential diagnosis. ²Mucus cyst of the penis, genitoperineal cyst of the median raphe, parameatal cyst, hydrocystoma, and apocrine cystadenoma of the penile shaft are all words that should be regarded equivalent. ³ From the anus to the urinary meatus, midline-developmental cysts are seen everywhere. Although the bulk of them are present from birth, they are often only noticeable throughout adolescence or adulthood. ⁴ Most cysts develop on the ventral side of the penile, close to the glans. Infection, trauma, or making coitus difficult, like in the case of the patient mentioned in this article, might exacerbate them even though they are often asymptomatic. Excision through surgery is required. 4 **more explanation is required?**

Conclusion:

Penile cysts are an uncommon condition that are present from birth but only become apparent in adolescence or age. They are cut out during circumcision.

What is your recommendations?

Reference : **you need to add at least 3 update references**

1. Cole LA, Helwig EB. Muroid cysts of the penile skin. *J Urol.* 1976;115:397–400. [[PubMed](#)] [[Google Scholar](#)]
2. Velasco E. Muroid cyst of penis skin [in Spanish] *Urol Colomb.* 1993;3:99–104. [[Google Scholar](#)]
3. Otsuka T, Ueda Y, Terauchi M, et al. Median raphe (parameatal) cysts of the penis. *J Urol.* 1998;159:1918–20. [[PubMed](#)] [[Google Scholar](#)]
4. Cardoso R, Freitas JD, Reis JP, et al. Median raphe cyst of the penis. *Dermatol Online J.* 2005;11:37. [[PubMed](#)] [[Google Scholar](#)]
5. P Saini, MN Mansoor, S Jalali, A Sharma. Penile epidermal inclusion cyst. *Indian*

J.Pediatr. 2010;77(7):815–16. [[PubMed](#)] [[Google Scholar](#)]

6. A Amaranathan, SP Sinhasan, SD Dasiah. Median Raphe Cysts of the Prepuccial Skin, with Triple Histological Linings: A Case Report and Review of the Literature. *J Clin Diagn Res.* 2013;7(1):1466–68. [[PMC free article](#)] [[PubMed](#)] [[Google Scholar](#)]

UNDER PEER REVIEW