

Case study

Ascaris Lumbricoides Infestation of Bile Ducts: Case report

Formatted: Font: Italic

Formatted: Font: Italic

Abstract

Background

Ascariasis is a common helminthic disease that affects the gastrointestinal tract of human beings and is caused by the Ascaris lumbricoid worm. Most of the time, this parasite resides in the intestinal lumen, but it can occasionally travel to the biliary tract through the ampulla of Vater. The most serious and potentially fatal complication of intestinal ascariasis is biliary ascariasis, which can appear in different ways.

Formatted: Font: Italic

Case Report

A non-diabetic, non-alcoholic female reported to the emergency department with a one-day history of abdominal pain and vomiting with worms. The pain began gradually with a score of 7/10 and rapidly deteriorated during the day, reaching 10/10 at the hospital presentation. The patient also had a significant medical history. ~~Prior to~~ Before papillotomy, she underwent endoscopic retrograde cholangiopancreatography with the removal of one common bile duct (CBD) stone, but no stent was implanted. She had her laparoscopic cholecystectomy done as well. Laboratory examination revealed normal liver function tests and C-reaction protein. While abdominal ultrasound confirmed the presence of hepatic pericholangitis and on ultrasound imaging, the CBD common bile duct was found to be enlarged approximately 7 mm in diameter, and had a linear tubular structure with centre faint echogenicity and periphery tubularity. The

ultimate diagnosis of the patient was cholangitis brought on by *Ascaris lumbricoides* **Lumbrosoides**. After the diagnosis, endoscopic retrograde cholangiopancreatography showed sphincterotomy with CBD dilation. The worm was extracted by grasping it with biopsy forceps and pulled out of the papilla using a balloon catheter. The length of the worm was 18 centimeters.

Formatted: Font: Italic

Conclusion

Ascaris is the most frequently occurring disease that can cause biliary complications, such as cholangitis. This case report suggests that cholangitis caused by *Ascaris lumbricoides* can be successfully treated with the endoscopic approach, indicating that endoscopy could be a viable option to manage ascaris.

Keywords: *Ascaris lumbricoides*, *Ascaris lumbricoides* infestation, Biliary infestation, Ultrasonography, Cholangitis, Endoscopic retrograde cholangiopancreatography

Introduction

Ascaris lumbricoides is the most prevalent nematode, causing human ascariasis, affecting an estimated 33 percent of the global population(1). This nematode is described in ancient Greco-Roman and Chinese sources, making it the first known recorded helminthic infection among human beings (2). In 1758, Linnaeus provided the very first official description of the genus *Ascaris*, and a century later, Grassi and Epstein (please check this 'Grassy and Epstein') demonstrated that egg intake precedes infection(2).

Additionally, it primarily affects children and people living in underdeveloped countries with inadequate sanitation (3). This disease can also have a significant impact on health and quality of

life and is predicted to affect millions of people, causing problems such as malnutrition and long-term cognitive impairment(4).

Furthermore, ~~despite the fact that~~ even though the majority of *A. lumbricoides* infections are asymptomatic or manifest with moderate symptoms such as periodic stomach pain, severe consequences can occur. For example, individuals with significant parasite loads may present with partial or total intestinal obstruction, requiring surgical intervention at times(5). Rarely, ascariasis can affect ectopic sites such as the gall bladder, lower airways, and appendix(6). In biliary ascariasis, roundworms invade the bile tract and can induce mechanical obstruction and inflammatory responses, leading to cholecystitis, acute cholangitis, or biliary colic (6).

Recently, more cases of hepatobiliary and pancreatic ascariasis are being discovered ~~thanks through~~ to the advancement in diagnostic imaging techniques (computed tomography scan, ultrasound, etc.). Abdominal ultrasonography can identify biliary Ascaris by revealing a moving worm with central hypoechogenicity and the presence of an echogenic wall in the gall bladder and bile ducts with a sensitivity of up to 86%(7).

Case Report

A non-diabetic, non-alcoholic female patient presented to the emergency department with a major complaint of abdominal pain and vomiting mixed with worms past one day. The patient stated that she was having severe intermitted gastric pain for the past 12 hours. She reported that she was functioning well in the early morning when the pain gradually began with a score of 7/10 and progressively worsened during the day, reaching 10/10 at presentation. The pain was colicky ~~in character~~ and radiates into the back. No prior episodes of such pain ~~were~~ have been reported except for an occasional mild burning epigastric sensation that waxed and waned. The

Formatted: Font: Italic

pain continued, and she reported that she felt nauseous before vomiting approximately six times, and in her vomiting, she saw clear fluid but with bright blood traces. There was no associated complaint of fever. Additionally, no loose stools were reported, however, the patient detected worms in her feces in the morning. Moreover, the patient had a significant ~~past~~ history. On 26 November 26 (2018), she underwent endoscopic retrograde cholangiopancreatography with the retrieval of 1 CBD stone with papillotomy done, but no stent ~~was~~ inserted. She also underwent laparoscopic cholecystectomy.

She did not smoke and was not an alcoholic. There was no other record of a history of chronic illness.

Laboratory investigations revealed normal liver function tests and normal C- reactive protein. Ultrasound abdomen was performed, which revealed liver pericholangitis. During an ultrasound examination, CBD was found to be enlarged approximately 7 mm in diameter and it had a linear tubular structure with central faint echogenicity and peripheral tubular structure. The doctors suspected that it could be a stent or worm infestation, as the patient reported passing worms and the records showed no convincing stent placement. The diagnosis was more in the favor of a possible worm infestation. Furthermore, the rest of the liver showed no focal lesion. The findings of the pancreas, spleen, kidneys, and urinary bladder were found to be unremarkable. The portal vein was found to be unaffected. There was no marked evidence of free fluid floating in the abdomen.

~~On the basis of~~ Based on these laboratory findings and ultrasound examination, the ultimate diagnosis of the patient was cholangitis caused by *Ascaris lumbricoides* ~~Lumbricoides~~. After the diagnosis, endoscopic retrograde cholangiopancreatography was done and sphincterotomy was performed with dilation of CBD. During the procedure, the large *Ascaris lumbricoides*

Formatted: Font: Italic

Formatted: Font: Italic

Lumbricoid was found lying in the right intrahepatic area and common bile duct. The worm was pulled down into the papilla with a balloon catheter and then grabbed with biopsy forceps and pulled out the mouth. The worm is 18 cm long. The patient was given Albendazole 400mg daily for three days.

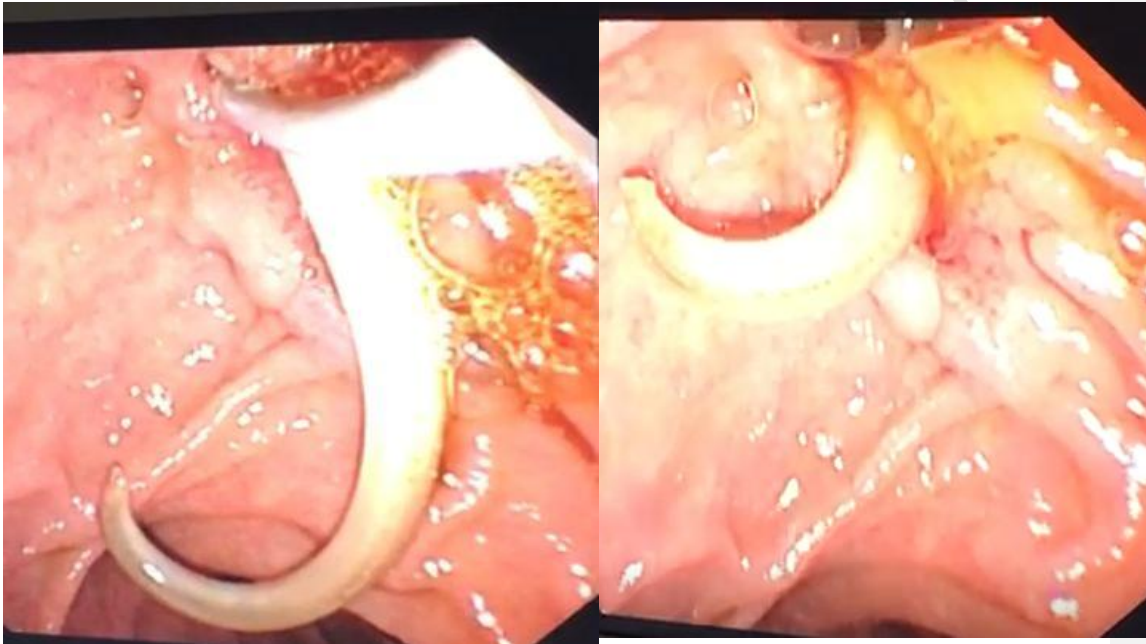


Fig A: Endoscopic retrograde cholangiopancreatography showed an active worm was seen from the common bile duct

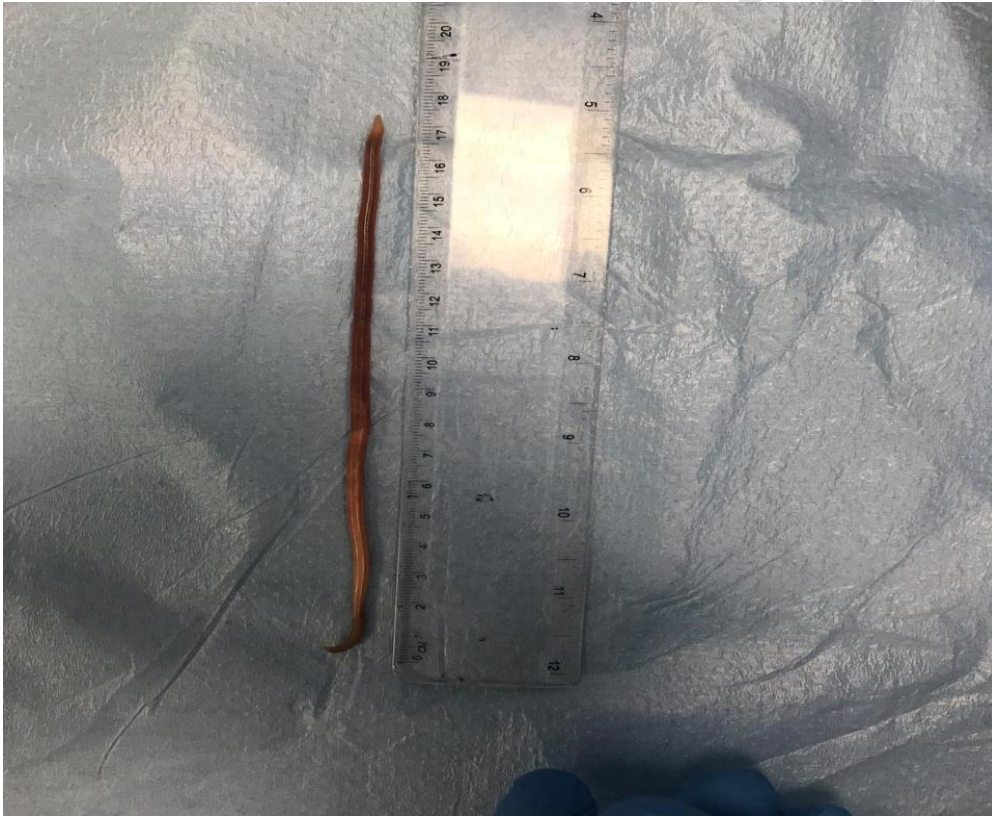


Fig B: Dead Ascaris worm

Discussion

Ascaris lumbricoides is a parasitic disease that can result in acute cholangitis and biliary blockage. Ascariasis is predicted to affect up to 1.2 billion people around the world(8). The life cycle of *A. lumbricoides* begins with the ingestion of eggs, which then develop in the small intestine. The larvae attack the mucosa of the small intestine, travel through the systemic circulation to the lungs, reach the bronchial tree, and are subsequently absorbed into the small intestine, where they grow into their adult form(9). Adult ascarids are often found in the small intestine, although they can move to other organs, including the biliary system, bladder, and lungs(9).

The disease may manifest differently depending on the organs and systems affected. Ascariasis manifests clinically as appendicular, lung, hepatobiliary, intestinal (including [bowel obstruction](#) ~~intestinal blockage~~), and pancreatic illness(10). Several factors enhance the risk of biliary *Ascaris*, which include pregnancy, prior experience in hepatobiliary surgery (endoscopic sphincterotomy, sphincteroplasty choledocholithotomy, cholecystectomy,) the feasible surrounding environment for the worm, such as fever, prolonged fasting, etc(11). Additionally, according to previous research, 30 percent of individuals with biliary ascariasis have a history of cholecystectomy (12). Following cholecystectomy, dilation of the common bile duct (CBD) and an increase in cholecystokinin occurs, which relaxes the sphincter of ~~o~~O_{ddi}. As our patient had previously had a cholecystectomy, it was suspected these factors likely contributed to worm migration into the biliary tree. Furthermore, our patient also underwent a previous endoscopic sphincterotomy (EPT), which has been established to be a risk factor for biliary worm migration in endemic regions (13) There is a preponderance of females in HBA since studies have indicated that females are more likely than males to have roundworm infestations, (F: M ratio of

3:1)(12), and it typically affects people between the ages of 30-70 in their mid-thirties(12). Our patient was also female.

Furthermore, ultrasound imaging is the technique of choice for demonstrating both worms and their motion in the biliary system over time due to its sensitivity(4). The results demonstrate a typical longitudinal image of a hyperechoic tubular structure without acoustic shadow or surrounding a hyperechoic structure, with a hypoechoic center (parallel echoic strip). In our case, ultrasound imaging was also performed which indicated an enlarged CBD approximately 7 mm in diameter and a linear tubular structure with central faint echogenicity and peripheral tubular structure(13).

Currently, three major treatment approaches have been identified to manage *Ascaris lumbricoides* ~~Lumbricooids~~. These include treatments such as using integrated traditional Chinese and Western medicine, surgical treatment, and endoscopic treatment (14). The non-surgical options for treating biliary ascariasis include choleric medicine, antibacterial, analgesic, and antispasmodic drugs. However, these treatments progress slowly and have variable therapeutic outcomes(7, 15). Additionally, these drugs could result in the death of the *Ascaris* worm in the biliary tract, which would result in gallstones and other complications(16).

The best method to treat biliary *Ascaris* is Endoscopic retrograde cholangiopancreatography (ERCP) in combination with anthelmintic medications. ~~Endoscopic retrograde cholangiopancreatography (ERCP)~~ is an alternate technique for detection that can also be used to remove *Ascaris* from the pancreatic ducts and intestinal lumen (14). Such intervention was also performed in our case to remove *Ascaris Lumbricoides*.

Conclusion

Formatted: Font: Italic

Ascaris is the most frequently occurring disease that can cause biliary complications such as cholangitis, cholecystitis, and other biliary inflammatory ~~disorders~~ diseases. Therefore, an accurate diagnosis upon admission is crucial. The primary symptom of biliary ascariasis is gut pain, which is readily misinterpreted as gallstones, liver cancer, cholecystitis hepatitis, and other diseases. Therefore, a thorough medical history and physical examination should be undertaken. Additionally, instrument examinations and laboratory examinations such as ultrasound should be performed quickly ~~and emphasis should be given to differential diagnosis~~ and differential diagnosis should be emphasized. The Endoscopic approach and anti-ascariasis medication are more effective in ~~the treatment of~~ treating biliary ascariasis. Surgery may be a viable option to remove *Ascaris L~~u~~mbricoides*.

Formatted: Strikethrough

Formatted: Strikethrough

Formatted: Strikethrough

Formatted: Font: Italic

Formatted: Font: Italic

References

1. Wang X, Lv YL, Cui SN, Zhu CH, Li Y, Pan YZ. Endoscopic management of biliary ascariasis: A case report. *World J Clin Cases*. 2021;9(20):5695-700.
2. Das AK. Hepatic and biliary ascariasis. *J Glob Infect Dis*. 2014;6(2):65-72.
3. de Lima Corvino DF, Horrall S. Ascariasis. In: *StatPearls*. StatPearls Publishing, Treasure Island (FL); 2022. PMID: 28613547
4. ~~e~~De Almeida BL, Silva DV, do Rosário MS, Gonçalves BSD, Nunes MG, Ney ALCM, et al. Biliary ascariasis and severe bacterial outcomes: Report of three cases from a pediatric hospital in Brazil. *International Journal of Infectious Diseases*. 2020;95:115-7.
5. Uysal E, Dokur M. The helminths causing surgical or endoscopic abdominal intervention: A review article. *Iranian Journal of Parasitology*. 2017;12(2):156.
6. Rujeeapaiboon N, Kaewdech A. Massive biliary ascariasis: an unusual cause of acute cholangitis. *BMJ Case Reports*. 2021;14(3):e239784.
7. Das AK. Hepatic and biliary ascariasis. *Journal of Global Infectious Diseases*. 2014;6(2):65.

8. Karshima SN. Prevalence and distribution of soil-transmitted helminth infections in Nigerian children: a systematic review and meta-analysis. *Infectious diseases of poverty*. 2018;7(04):1-14.
9. Avokpaho EF, Hounbégnon P, Accrombessi M, Atindéglá E, Yard E, Rubin Means A, et al. Factors associated with soil-transmitted helminths infection in Benin: Findings from the DeWorm3 study. *PLoS neglected tropical diseases*. 2021;15(8):e0009646.
10. Kabatende J, Mugisha M, Ntirenganya L, Barry A, Ruberanziza E, Mbonigaba JB, et al. Prevalence, intensity, and correlates of soil-transmitted helminth infections among school children after a decade of preventive chemotherapy in Western Rwanda. *Pathogens*. 2020;9(12):1076.
11. Yang D, Yang Y, Wang Y, Yang Y, Dong S, Chen Y, et al. Prevalence and risk factors of *Ascaris lumbricoides*, *Trichuris trichiura* and *Cryptosporidium* infections in elementary school children in Southwestern China: a school-based cross-sectional study. *International Journal of Environmental Research and Public Health*. 2018;15(9):1809.
12. Temesgen R, Abebe H, Abera Y. Hepatobiliary and Pancreatic Duct Ascariasis: An Unusual Cause of Obstructive Jaundice and Severe Acute Cholangitis. *International Medical Case Reports Journal*. 2022;15:281.
13. Jethwani U, Singh G, Sarangi P, Kandwal V. Laparoscopic management of wandering biliary ascariasis. *Case Reports in Surgery*. 2012;2012.
14. Wang Y, Liu J. Biliary ascariasis: particular cause of biliary tract infection. *Hepatobiliary Surgery and Nutrition*. 2020;9(1):119.
15. Azhar M, Sheikh ASF, Khan A, Mustafa S, Shah IA, Hameed B. Hepatobiliary ascariasis complicated by pancreatitis. *Journal of Ayub Medical College Abbottabad*. 2015;27(2):479-81.
16. Balasubramanian G. An unusual cause of biliary colic. *BMJ Case Rep*. 2014;2014.