

Scorpion envenomation, a sting to the heart : A rare case report

Abstract :

Scorpion envenomation (SE) remains a public health problem in Morocco, with a severity of lesions and a mortality rate correlated with a young age.

These bites are harmless in most cases, but sometimes have serious clinical sequelae that can go as far as death.

Severity is greater in children under 15 years old and morality is particularly important in children under 6 years old.

Such bites can have serious clinical sequelae including cardiovascular damage: myocardial infarction, acute pulmonary edema, cardiogenic shock and even death.

We report the case of a SE causing a fatal cardiac complication in a 50 year old patient.

Key words :

Scorpion envenomation, cardiovascular damage, myocardial infarction, acute myocarditis, case report

Introduction :

SE are common and usually harmless but sometimes have serious clinical sequelae, which can go as far as death.

Most often, the manifestations are local, limited to the site of the sting, such as intense pain or burning, but systemic complications can ensue, in particular cardiovascular or central nervous system damage [1].

These cardiovascular manifestations may be related to the effect of the venom on the sympathetic nervous system or to the adrenal secretion of catecholamines as well as to the toxic effect of the venom on the myocardium itself.

The venom can cause myocardial lesions by several pathogenic mechanisms: Myocardial ischemia by coronary spasm [2] Direct cardiotoxic effect of the venom [3], anaphylactic reaction [4].

As in this case report, these bites can have serious clinical sequelae, including myocardial infarction, acute pulmonary edema, cardiogenic shock and even death [5].

Case presentation :

We report the case of a 50-year-old man, with no particular pathological history: in particular no smoking history, no toxic habits, not known to be hypertensive or diabetic or dyslipidemic.

The patient presented to the emergency room following a scorpion bite on the level of the right knee (figure 1). 4 hours later the symptomatology worsened by the installation of constrictive chest pain retrosternal and radiating to the left upper limb never felt previously associated with sudden onset respiratory discomfort.

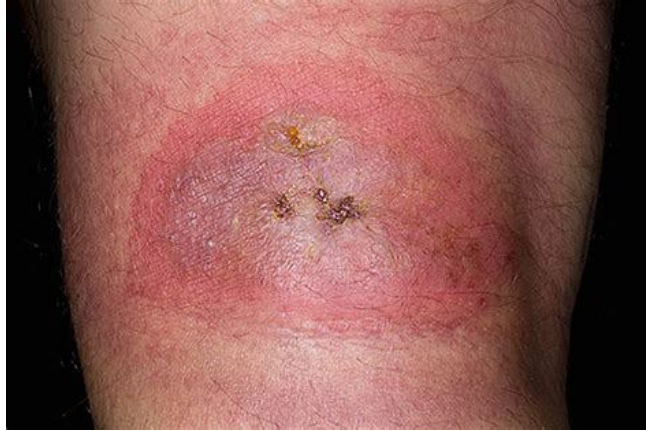

Figure 1 : erythematous lesion with traces of a scorpion bite on the right knee

The clinical examination in the emergency room found a normotensive patient at 154/62 mmHg, a heart rate at 90 bpm, polypnea at 26 cycles per minute. On pulmonary auscultation, crackles were found reaching the top, with a saturation of 78% in the open air. There was also edema of the lower limbs to mid-legs.

Skin-mucosal examination showed an erythematous lesion with traces of a scorpion bite on the right knee (figure 1).

Electrocardiogram (EKG) performed in the emergency room showed ST depression and negative T waves in circumferential (figure 2).

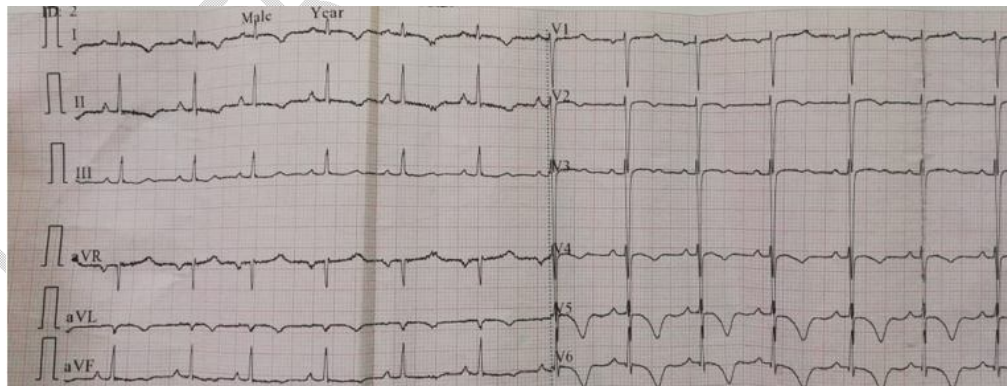


Figure 2 : EKG with negative T waves in circumferential

The patient was hospitalized in the cardiology intensive care unit of the Ibn Rochd university hospital in Casablanca, Morocco.

The patient was monitored, placed in a half-sitting position, oxygen therapy by high concentration mask at 10l/min, taken from a peripheral

venous line, a bolus of 60mg of furosemide was administered urgently then relayed intravenously in a syringe autopusher, two sublingual puffs of nitrates.

The echocardiographic probe objectified hypokinesia of the anterior, anterolateral and anteroseptal walls with an altered ejection fraction of 42% in simpson biplane (figure 3), high filling pressures, severe mitral insufficiency, pulmonary hypertension at 52 mmhg, without pericardial effusion, a non compliant inferior vena cava dilated at 23 mm.

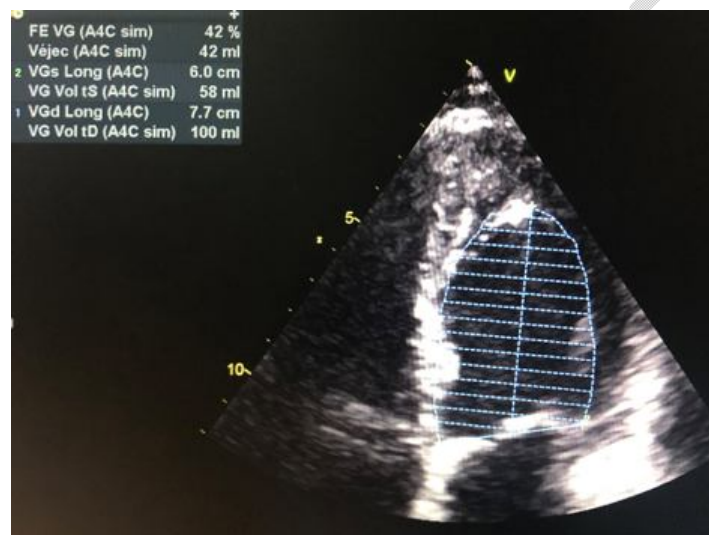

Figure 3 : Ejection fraction of the left ventricle in simpson biplane

A dose of 300 mg of aspirin and 80 IU of UFH was rapidly administered orally, then the patient was taken to the cardiac catheterization room where a coronary angiography was performed, which returned strictly normal with no individualized atheromatous plaque (figure 4) the methyl ergonovine test could not be performed. A ventriculography was performed during the procedure returning normal without the appearance of apical ballooning

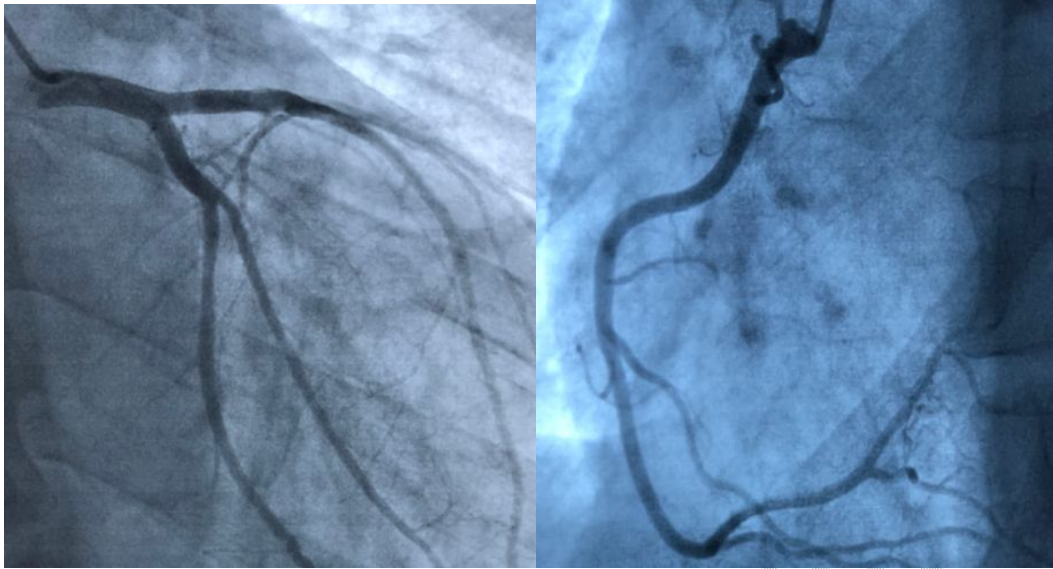


Figure 4 : normal coronary angiography

The biological assessment showed positive ultrasensitive troponins at 14,501, hemoglobin at 16.6 g/dL, the number of white blood cells was 15,660 cells/mm³, platelet count at 343,000/mm³, serum sodium was 145 mmol/L, serum potassium was 4.2 mmol/L; serum urea was 0.59 mg/L, serum creatinine was 12.3mg/L, aspartate transaminase was 101 U/L, alanine transaminase was 30 U/L, and CRP at 16.

Patient remained under close surveillance in a cardiological intensive care unit with monitoring of PA Fc and oxygen saturation, diuresis and EKG

The evolution of the patient on the 3rd day was marked by the regression of crackles becoming discreetly at the base with disappearance of the edema of the lower limbs, a diuresis maintained at 2800 ml, a significant improvement in his dyspnoea, then the patient was declared discharged after 7 days on anti-platelet agents, ACE inhibitor, anti-aldosterone and statin.

The follow-up at 1 month showed a regression of the undershift anterior to the ECG, an improvement in the LVEF in the simpson biplane becoming 50% without notable disturbances in the kinetics.

A cardiac MRI was not performed due to a lack of resources.

The spectacular evolution led to the diagnosis of cardiac involvement secondary to scorpion venom; it is either an acute myocarditis or a myocardial infarction type 2.

DISCUSSION :

SE remains a public health problem in Morocco [6]. Epidemiological data established by the Moroccan anti-poison center (CAPM) show that scorpion stings are at the top of all poisonings noted by the center (60%) with an incidence rate ranging from 0 to 2.4% depending on the region and an overall fatality rate of 0.82%, which can reach 5.3% in the southern regions [7,8]. The infant mortality rate between 1999 and 2008 was 100 deaths on average [9].

According to the D'Abroug classification adopted by the WHO [12], scorpion stings are of 3 types depending on the severity of the lesions, in the case of our patient the bite was classified in class 3 characterized by cardiovascular failure.

Severe forms require admission to intensive care and are often associated with high mortality. Moreover, the correlation between young age and the severity of clinical manifestations after scorpion envenomation has been well established [10,11]. Severity is greater in children under 15 years of age and mortality is particularly important in children under 6 years of age [12,13].

Despite the entomological differences between the different species, there is a great homology between the toxic effects of their venoms and their antigenic structures [14,15]. This makes it possible to summarize the physiopathology of SE in 3 essential points:

- a direct toxic action;
- a massive discharge of the neurotransmitters contained in the venom causing a systemic inflammatory reaction (systemic inflammatory response syndrome)

Thus, cardiovascular dysfunction during severe ES is multifactorial and may be linked either to a

-Adrenergic myocarditis or Tako-tsubo syndrome:

It occurs under the effect of a massive discharge of catecholamines by stimulation of nerve endings [16,17].

-Toxic myocarditis:

It occurs following a general disorganization of myocardial tissue visible on histological examination (intravascular platelet and leukocyte aggregation, interstitial and capillary edema) [18].

-An acute coronary syndrome of multifactorial origin:

It is the result of damage to the coronary microcirculation with localized myocardial pain [17]. This hypothesis is based on clinical [17, 19], scintigraphic and echocardiographic studies. Or also less likely to epicardial coronary vasospasm or microvascular spasm following the toxic catecholergic discharge [20].

-Hemodynamic OAP:

The release of catecholamines under the effect of scorpion neurotoxins induces an increase in systemic arterial pressure and peripheral resistance, ventricular arrhythmia, an increase in left ventricular end-diastolic pressure and a decrease in left ventricular compliance [17-20]. In addition, plasma renin activity and aldosterone are increased, thus increasing peripheral vascular resistance [21]. These phenomena lead to both systolic and diastolic left ventricular dysfunction, thus explaining the hemodynamic nature of pulmonary edema.

The management of scorpion envenomation in Morocco is essentially symptomatic and includes the administration of vasoactive drugs (dobutamine) in the event of a state of shock, oxygen therapy and artificial ventilation in the event of respiratory distress and the administration of anticonvulsant in case of seizures.

Specific treatment with antiscorpion immunotherapy is very controversial and is not recommended in Morocco. Adequate symptomatic management and monitoring in an intensive care unit allowed a very favorable evolution of our patient.

CONCLUSION:

Scorpion envenomation represents a real public health problem due to the morbidity and mortality attributed to it and its heavy socio-economic repercussions.

SE can cause heart damage by different mechanisms as mentioned above.

This case is among the rare cases of cardiac damage secondary to SE, which should lead to a better awareness and education of the population in this sense to avoid fatal complications.

Declarations :

Consent:

Written informed consent was obtained from the patients for publication of this case report and any accompanying images.

Ethical Approval:

As per international standard or university standard written ethical approval has been collected and preserved by the author(s).

Availability of data and material :

All data generated or analysed during this study are included in this published article.

References :

- [1]-[[Google Scholar](#)] Erfati P. Epidemiology, symptomatology and treatment of buthinae stings. In: Bettini S, editor. Arthropod Venoms: Hand Book of Experimental Pharmacology. New York: Springer Verlag; 1978. p. 312-5.
- [2]-Yang HP, Chen FC, Chen CC, Shen TY, Wu SP, Tseng YZ. Manifestations mimicking acute myocardial infarction after honeybee sting. Acta Cardiol Sin 2009;25:31-5. [[Google Scholar](#)]
- [3]-Rahav G, Weiss AT. Scorpion sting-induced pulmonary edema. Scintigraphic evidence of cardiac dysfunction. Chest 1990;97:1478-80. 8. Bawaskar HS, Bawaskar PH. Management of scorpion sting. Heart 1999;82:253-4. [[PubMed](#)] [[Google Scholar](#)]
- [4]-Bawaskar HS, Bawaskar PH. Gestion des piqûres de scorpion. Cœur. 1999 ; 82 : 253-4. [[Article PMC gratuit](#)] [[PubMed](#)] [[Google Scholar](#)]
- [5]-[[PubMed](#)] [[Google Scholar](#)] 3-Bawaskar HS, Bawaskar PH. Indian red scorpion envenoming. Indian J Pediatr 1998;65:383-91.
- [6]-Bouaziz M, Ben Hamida C, Chelly H, Rekik N, Jeddi H-M. Envenimation Paris: Arnette; 1996. L'envenimation scorpionique: étude épidémiologique, clinique et éléments de pronostic; pp. 11-35. [[Google Scholar](#)]
- [7]- Soulaymani RB. Épidémiologie des piqûres de scorpion au Maroc: étude prospective (Abstract) Infotox. 2002;15:11. [[Google Scholar](#)]
- [8]-Soulaymani R. Stratégie marocaine 2001 contre les piqûres et les envenimations scorpioniques (Abstract) Infotox. 2002;15:11.
- [9]-Centre antipoison du Maroc. Stratégie nationale de lutte contre les piqûres et les envenimations scorpioniques; Toxicologie Maroc; 2009. p. 7. N°2. [[PubMed](#)] [[Google Scholar](#)]
- [10]-Bahloul M, Rekik N, Chabchoub I, et al. Neurological complications secondary to severe scorpion envenomation. Med Sci Monit 2005 ; 11 : CR196-202.

[11]-Bahloul M, Chaari A, Khlaf-Bouaziz N, et al. Gastrointestinal manifestations in severe scorpion envenomation. *Gastroenterol Clin Biol* 2005 ; 29 : 1001-5.

[12]-Abroug F, Elatrous S, Noura S, et al. Serotherapy in scorpion envenomation : a randomised controlled trial. *Lancet* 1999 ; 354 : 906-9.

[13]-Bouaziz M, Ben Hamida C, Chelly H, et al. « L'envenimation scorpionique : étude épidémiologique, clinique et éléments de pronostic ». In : *Envenimations*. Paris : Arnette. pp. 11-35.

[14]- El Ayeb M, Martin MF, Delori P, Bechis G, Rochat H. Immunochemistry of scorpion alpha-neurotoxins. Determination of the antigenic site number and isolation of a highly enriched antibody specific to a single antigenic site of toxin II of *Androctonus australis* Hector. *Mol Immunol* 1983 ; 20 : 697-708.

[15]-Bertke EM, Atkins JH. Effect of *centruroides sculpturatus* venom upon rat tissue: a histopathologic study. *Toxicon* 1964 ; 2 : 205-9.

[16]-Noura S, Abroug F, Haguiga H, et al. Right ventricular dysfunction following severe scorpion envenomation. *Chest* 1995 ; 108 : 682-7.

[17]-Bouaziz M, Bahloul M, Hergafi L, et al. Factors associated with pulmonary edema in severe scorpion sting patients: a multivariate analysis of 428 cases. *Clin Toxicol (Phila)* 2006 ; 44 : 293-300.

[18]- Bouaziz M, Bahloul M, Kallel H, et al. Epidemiological, clinical characteristics and outcome of severe scorpion envenomation in south Tunisia: multivariate analysis of 951 cases. *Toxicon* 2008 ; 52 : 918-26.

[19]-Bahloul M, Ben Hamida C, Chtourou K, et al. Evidence of myocardial ischaemia in severe scorpion envenomation. Myocardial perfusion scintigraphy study. *Intensive Care Med* 2004 ; 30 : 461-7.

[20]-Sofer S, Shahak E, Slonim A, Gueron M. Myocardial injury without heart failure following envenomation by the scorpion *Leiurus quinquestriatus* in children. *Toxicon* 1991 ; 29 : 382-5.

[21]-Sofer S, Gueron M. Respiratory failure in children following envenomation by scorpion *Leirus Quinquestriatus*: hemodynamic and neurological aspects. *Toxicon* 1998 ; 26 : 931-9.

UNDER PEER REVIEW