

Spine Implant Failure after C1-C2 Fixation

Abstract

The paper presents two clinical cases of the patients with different congenital craniovertebral junction deformities who developed rare delayed complications after the treatment and provides critical analysis of related literature data. CAAD is a complex multiplanar deformation, whose treatment requires a differential approach and depends on a kind of congenital anomalies and a load placed on instrumentation fixing points. Maximally symmetric positioning of the implants can help to avoid the recurrence or formation of a new anomaly in the postoperative period. A facet joint block prevents the formation of postoperative lateral atlantoaxial dislocation (LAAD).

Keywords: atlantoaxial dislocation (AAD), torticollis, congenital spine deformity.

UNDER PEER REVIEW

Introduction

Congenital atlantoaxial dislocation (CAAD) is a complex anomaly of the craniovertebral junction (CVJ) that may develop for a long time without any visual manifestations. The patients' complaints normally include pain and stiffness in the cervical spine (70%) [1]. While C1 occipitalization is one of the most common CAADs with its frequency varying from 0.08 to 3.63 % [2; 3], C2 anomaly occurs only in 0.9% of cases according to Avinash et al. [4].

The etiology enables us to subdivide the disease into three main categories such as traumatic, spontaneous and congenital AADs. The classifications available in the literature provide surgery [5], facet [6], dislocation [7] and CVJ anomaly [8]-based classifications. By date, no general classification has been devised, but considering that CAADs can be due to different CVJ anomalies, the classification used in this paper is CVJ anomaly-based and considers that C1 can be displaced relative to C2 in several planes including vertical, lateral transverse, lateral oblique and rotational ones [9].

CJV screw fixation has been the golden standard of CAAD treatment. The first attempt to treat AAD being a plate combined with C1 lateral mass screw fixation and C2 partial and transpedicular fixation was presented in 1994 by Goel and Laheri [10]. In 2001, the technique was modified to be used with polyaxial screw and rod fixation [11]. According to the metanalysis performed in 2014, the modification was found safe and effective for C1-C2 fixation [12]. More complex occipital condylar cervical fixation was offered in 2008 by La Marca et al., whose cadaver research had proved the safety and efficacy of the technique [13]. In 2013, Kosnik-Infinger et al. reported its successful use in 4 children patients [14].

Despite the efficacy of the technique, C1-C2 fixation may lead to delayed complications such as bone graft nonunion and redislocation [15]. Effective retreatment of such patients is determined not only by the features of the original CAAD but also by the consequences of the performed treatment. The present paper presents 2 clinical cases of the patients with different

congenital CVJ anomalies who developed rare delayed complications after CAAD treatment and provides critical analysis of related literature data.

Case presentation

Clinical case 1

A 6-year-old girl turned to our medical center to complain about the CVJ deformation she had developed due to an impelled left-sided chin-down head tilt. According to her mother torticollis had been progressing since the age of three, which was confirmed by the X-ray investigation performed in a local clinic.

In our center, the patient underwent X-ray and MSCT and MRI assessment (Fig. 1). According to Classification of Bony Malformations of the CVJ according to Embryogenesis [8], the deformation was classified as malformations of the surrounding rings; disturbance of the lateral component and hypochordal bows of the proatlas and C1 resegmented sclerotome; proatlas anomalies (non-resegmentation, assimilation of anterior arch and lateral masses) and aplasia/hypoplasia of the lateral sclerotome (C1 left posterior archhypoplasia).

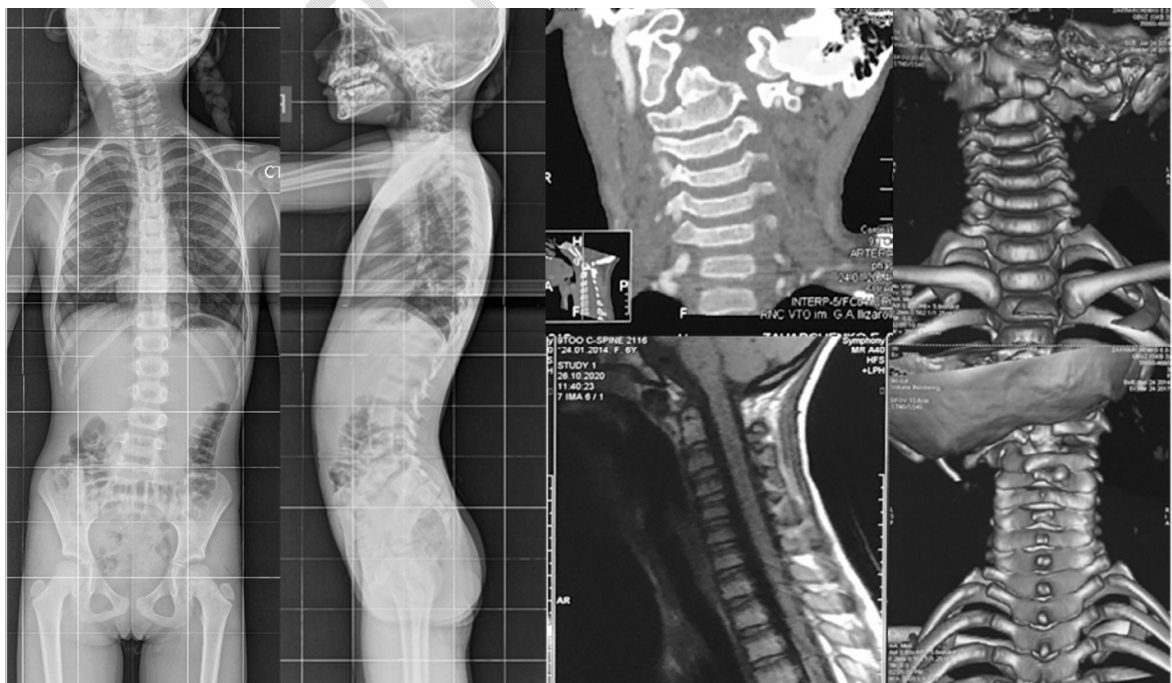

Fig. 1. Spinal X-ray image (1a -frontal, 1b-lateral) shows the patient's CAAD and unstructured scoliotic compensatory curve in the thoracolumbar spine. The sagittal projection of CVJ MRI image (2) demonstrates a spinal canal deformation in the middle section. Neither deformity nor compression. MSCT images (3 a,b,c) show a congenital LAAD [6; 16] due to C1 rotation in presence of the proatlas; the C1 right lateral mass forms a bone block with the occipital bone condyle; a fully formed odontoid bone is displaced cranially to the right. The left part of C1 arch and the left part of C1 vertebra are displaced distally to C2.

The surgical treatment was planned in a way to eliminate the rotational deformation of axial dislocation of the C2 vertebra. For that purpose, we performed a posterior screw fixation involving the lateral masses and residual arch of C1; C2 transpedicular fixation; C1-C2 release and C1-C2 deformity correction. Dorsal fusion was achieved using a deproteinized allogenic bone matrix.

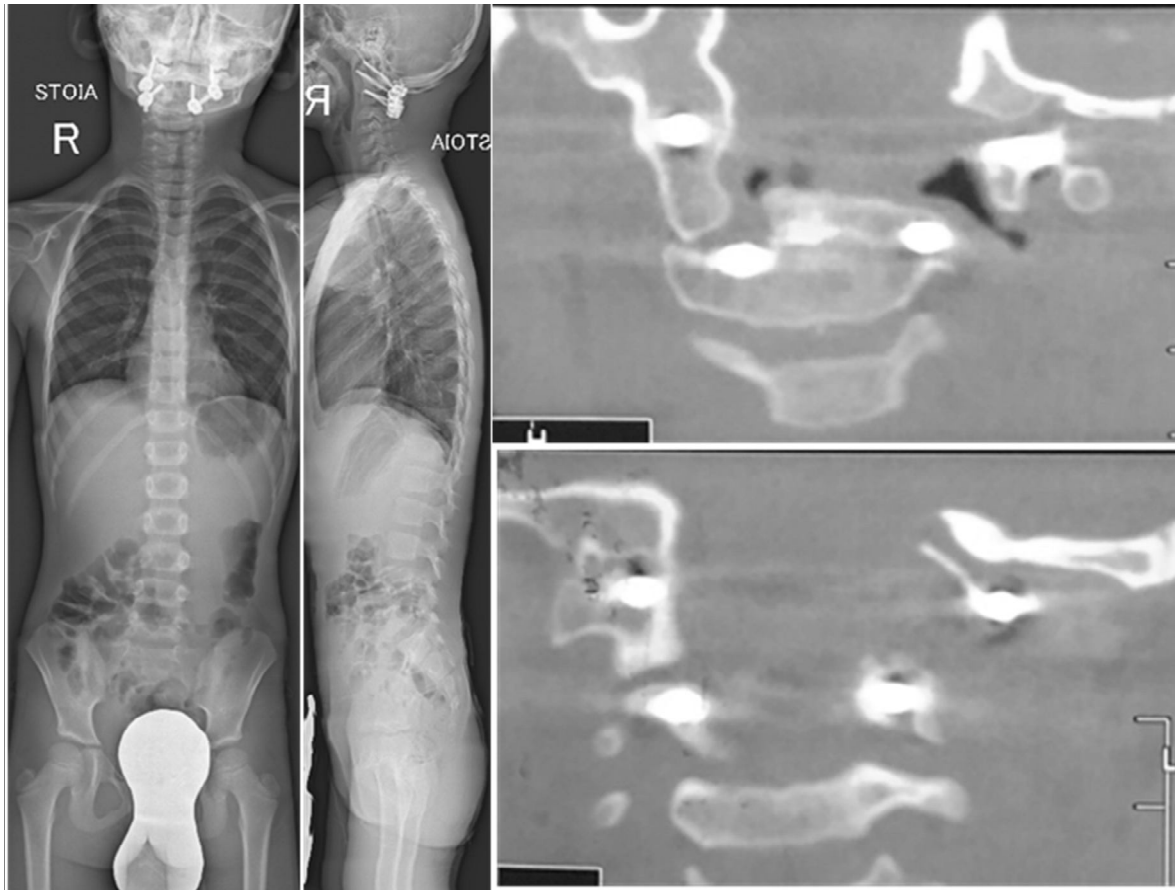

Fig. 2. Spinal X-ray image (2a -frontal, 2b-lateral). CVJ MRI image after axial reconstruction (2c).

In the postoperative period, proper lateral atlantoaxial dislocation (LAAD) correction was observed as well as that of nonstructural thoracic and lumbar spine scoliosis due to elimination of the original deformity (Fig. 2a). According to MSCT data (Fig. 2c), both axial and lateral C2 dislocations were eliminated and C1 was derotated. The fixing rods were asymmetric relative to one another. Additional 6-month cervical immobilization with a Philadelphia collar was recommended. At 6-month follow-up (Fig.3), a progressing prominent LAAD was noted for the instrumentation had migrated 90 degrees on the left side. A reoperation was performed at 9 months. The patient's assessment data before the intervention can be seen in Fig. 4. To

understand the dislocation mechanism and assess the positioning of the bone structures, a 3D model was produced (Fig. 5).

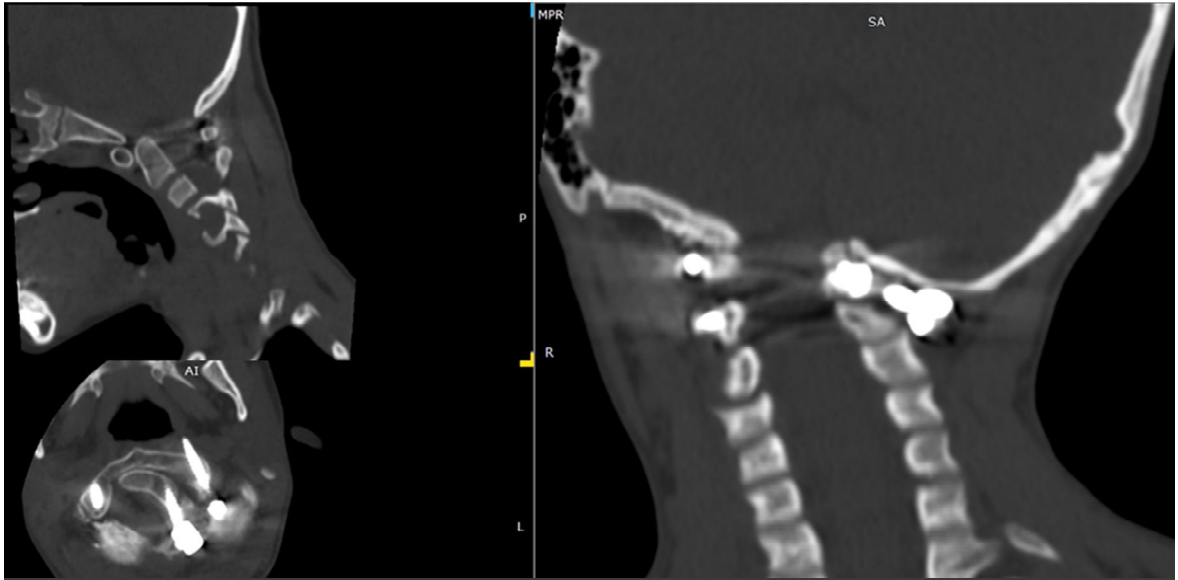


Fig 3. CVJ MRI image (a-lateral, b-axial, c-frontal reconstruction) demonstrates a pronounced left-sided LAAD and a 90-degree instrumentation malposition. No resorption area can be seen around the screws, meaning they preserve their fixed position despite the dislocation.

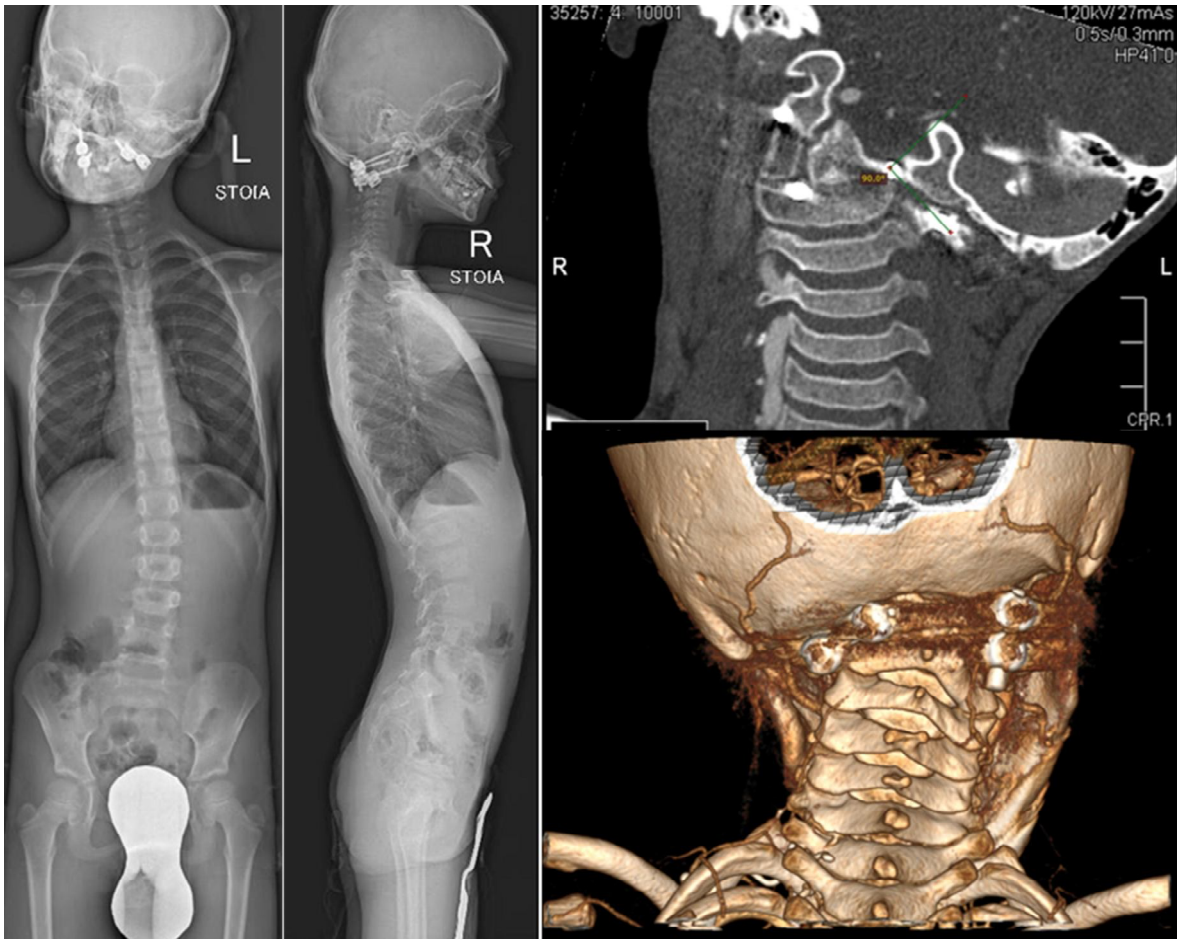


Fig.4. Spinal X-ray image (4a - frontsl, 4b- lateral) shows LAAD recurrence causing an unstructured compensatory curve in the thoracolumbar spine. MSCT image (4a-frontal, 4b- 3D reconstruction) demonstrates C1 LAAD reformation after C1-C2 screw fixation due to a large axial load accompanied by left posterior arch aplasia and right-atlas occipitalization. Note migration by 90 degrees on the left side, while on the right side it remains stable.

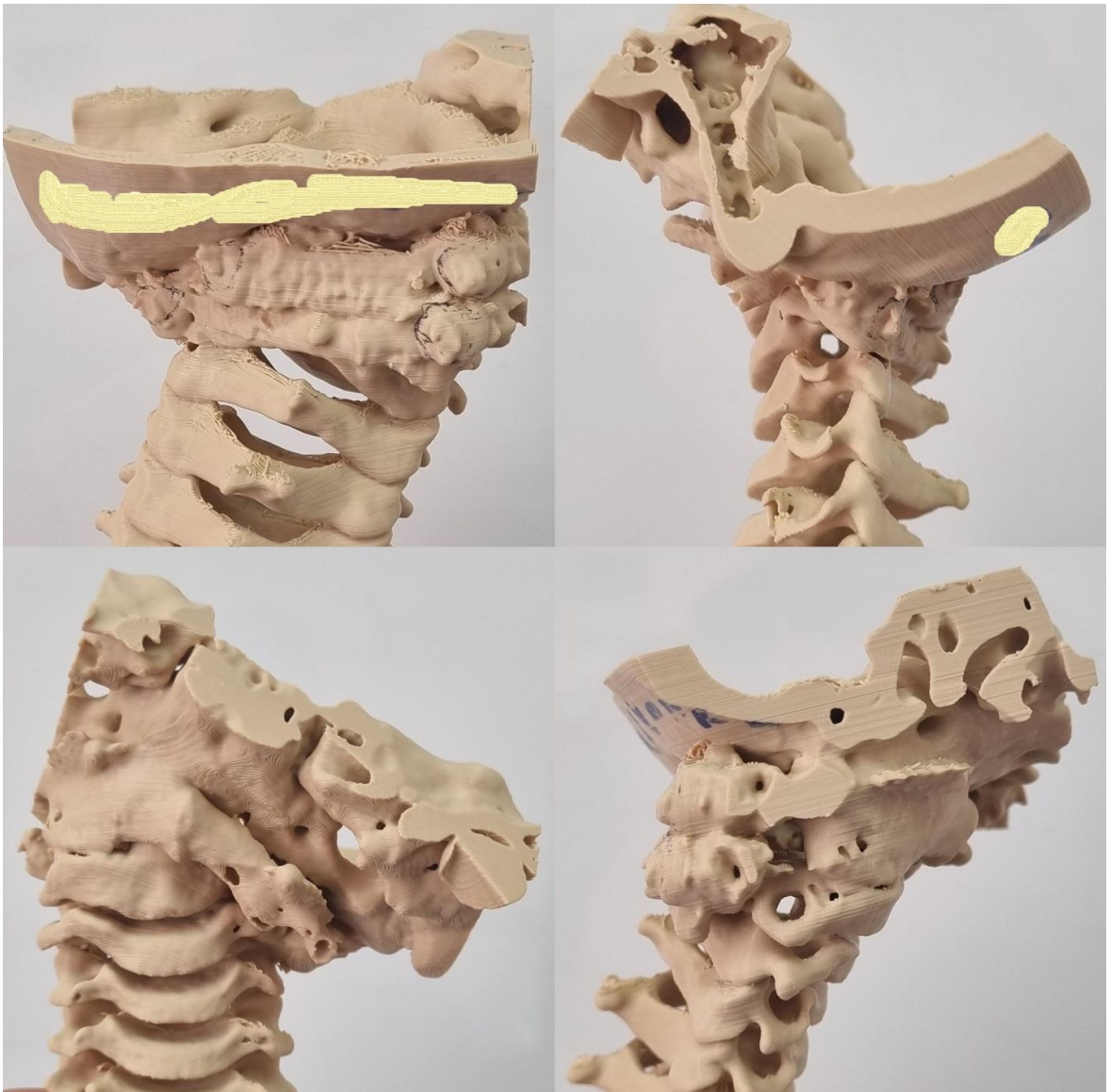

Fig. 5. 3D model (posterior, anterior and lateral views).

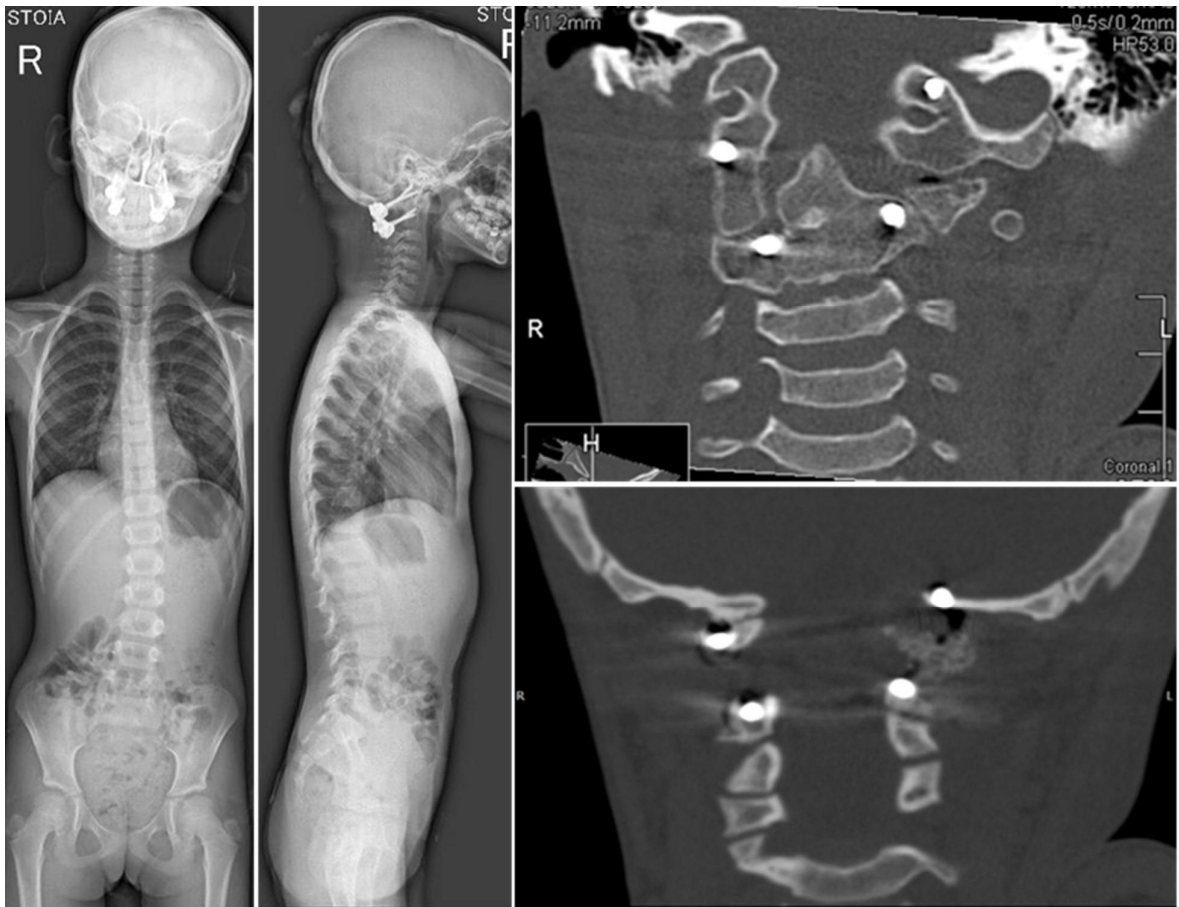

Fig. 6. Spinal X-ray image (5a -frontal, 5b -lateral). Coronal CVJ MSCT images (5c, d). During the intervention, the bone/fibrous block on the right side was resected as well as the hypoplasied part of the C1 arch and a part of the occipital foramen. A screw was put in the occipital bone's left condyle and a new C1-C2 fusion was formed on the left side. Dorsal fusion was achieved using a deproteinized allogenic bone matrix.

During the postoperative period, a proper correction of the LAAD and nonstructural thoracic and lumbar spine scoliosis was observed (Fig. 6a). MSCT imaging (Fig. 6 c) demonstrated C2 axial dislocation elimination and C1 derotation. The fixing rods were symmetrical relative to one another (Fig. 6 d). A 3D model was built to estimate the patient's progress. Additional cervical immobilization with a Philadelphia collar was recommended.

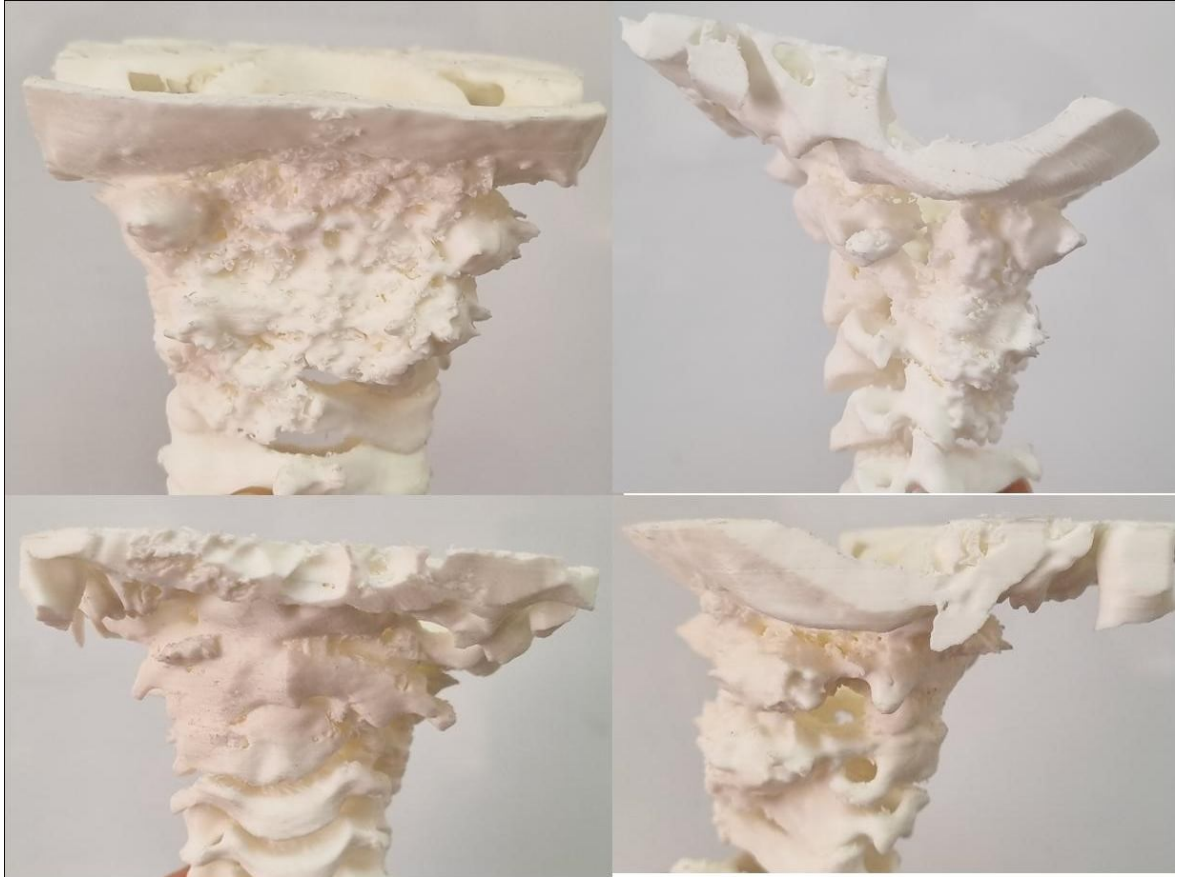

Fig. 7. 3D model (posterior, anterior and lateral views).

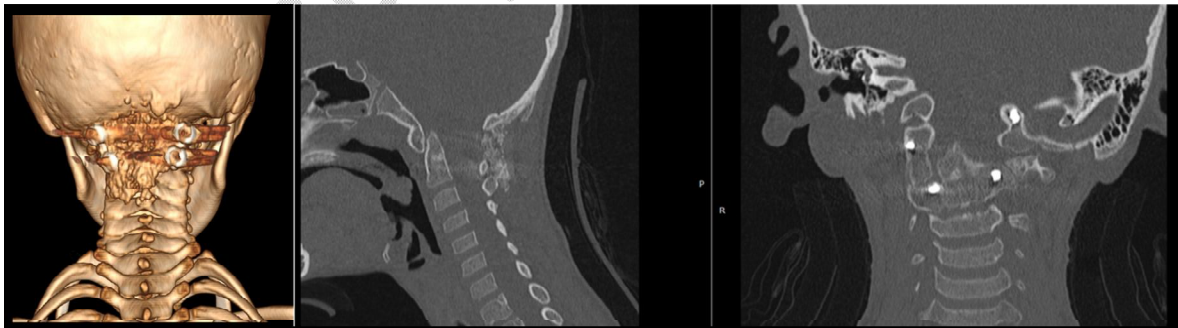


Fig. 8. MSCT images (6a - 3D reconstruction, 6b - sagittal, 6c - axial).

A control MSCT examination administered in three months showed no instrumentation instability or deformation progression (Fig. 8).

This case has demonstrated that AAD requires thorough preoperational planning that accounts for future loading on the fixing structures and enables for proper selection of optimal fixation points. For follow-up purposes, one is better to rely upon MSCT for the first three months after the procedure since x-ray imaging does not provide sufficient clinical evidence.

Clinical case 2.

An 8-year-old girl turned to our medical center with complaints on torticollis and the disharmonious head positioning causing neck stiffness. According to the patient's mother, she had fallen off a bed at the age of one year that had led to a cervical spine injury. At the age of 7, a major-airway inflammation had provoked Grisel's syndrome that was treated conservatively. X-ray and MRI examination in a local hospital had found a vertebral canal stenosis at the CVJ level.

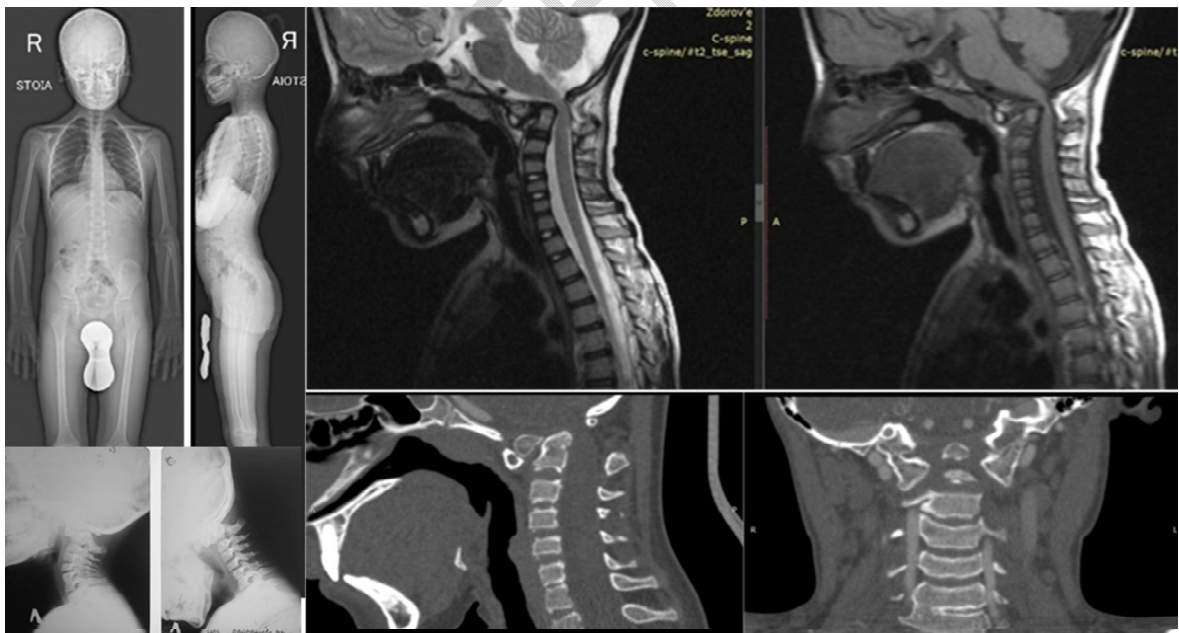


Fig. 9. Spinal X-ray image (1a-frontal, 1b-lateral, 1c -after maximum bending and extension) shows the patient's AAD and C1-os odontoideum dislocation. Sagittal CVJ MRI image (1 d,e) demonstrates the expressed basilar kyphosis with Wackenheim's angle reduced to 99 degrees,

and spinal canal stenosis causing spinal-cord compression (minimum sagittal spinal-cord size at C2 is reduced to 0.45 mm). MSCT image (1e – sagittal and axial) show a joint forming between the osodontoideum and the posterior part of C1 arch. Anterior C1 dislocation. Right-sided C2-C3 concrecence.

In our center, the patient underwent X-ray and MSCT and MRI assessment (Fig. 9). According to Classification of Bony Malformations of the CVJ according to Embryogenesis [8], the deformation was classified as malformations of the central pillar; disturbance of the axial component of the occipital sclerotome; proatlas and C1 resegmented sclerotome; odontoid dysgeneses; disturbance of odontoid synchondroses (osodontoideum).

The intervention was planned considering a need to eliminate the AAD, reduce the C1 anterior dislocation and perform an indirect decompression of the spinal cord at the level of C2. The operation included bilateral screw fixation through C1 lateral masses; transpedicular C2 fixation; C1-C2 vertebral release; C1 anterior dislocation reduction to increase the craniovertebral angle and decompress the spinal cord. The correction involved skull traction performed under neurophysiological control. Dorsal fusion was achieved using a deproteinized allogenic bone matrix.

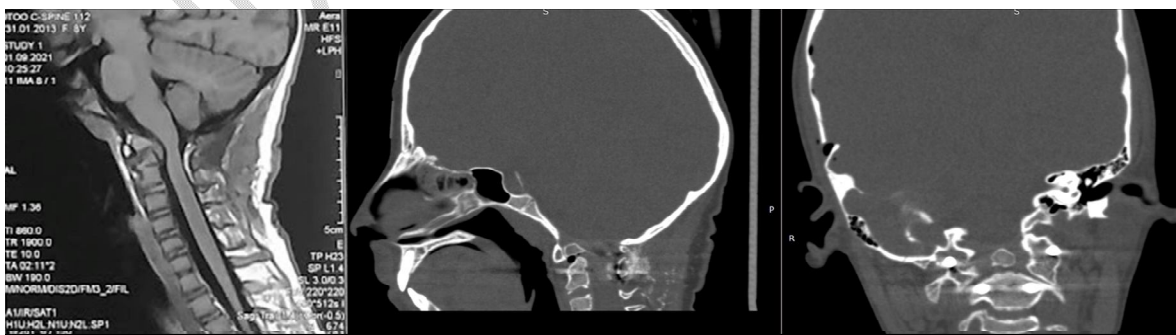


Fig. 10. CVJ MRI (2a– sagittal) and MSCT (2b - sagittal, 2c–axial) images

During the postoperative period, MRI showed a critical increase of the intracranial distance at the level of C2 up to 1 cm (Fig. 10a); reduction of the anterior dislocation and AAD; correction of the kyphotic deformation, so the Wackenheim's angle increased up to 138 degrees. An insignificant LAAD was observed together with fixing-rod asymmetry (Fig. 10b, c). Additional 3-month cervical immobilization with a Philadelphia collar was recommended.

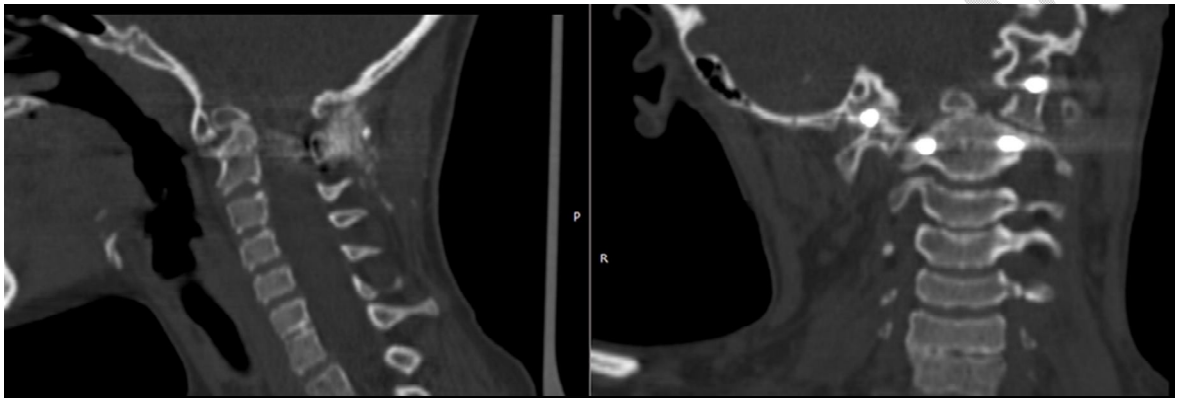


Fig 11. CVJ MSCT image demonstrates expressed right-sided torticollis due to instrumentation migration by 30 degrees to the right.

A follow-up at three months (Fig.11) demonstrated significant LAAD progression due to migration dislocation by 30 degrees. The right-sided screws, however, had no resorption around them, meaning they were still properly fixed.

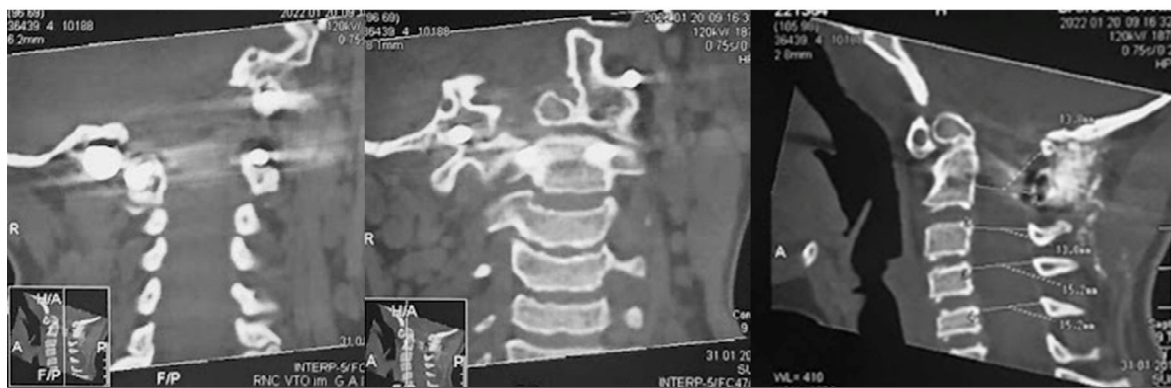

Fig. 12. MSCT image (12a, 12b) shows C1 axial dislocation recurrence after C1-C2 screw fixation due to higher axial load. The instrumentation has migrated by 5 degrees to the right.

In four months after the first correction, a reoperation was performed following an MSCT assessment of the patient's cervicothoracic junction (Fig.12). The correction involved skull traction performed under neurophysiological control and included putting bilateral transpedicular screws in C3; C1-C2 right-sided fusion, and instrumentation repositioning. Dorsal fusion was achieved using a deproteinized allogenic bone matrix.

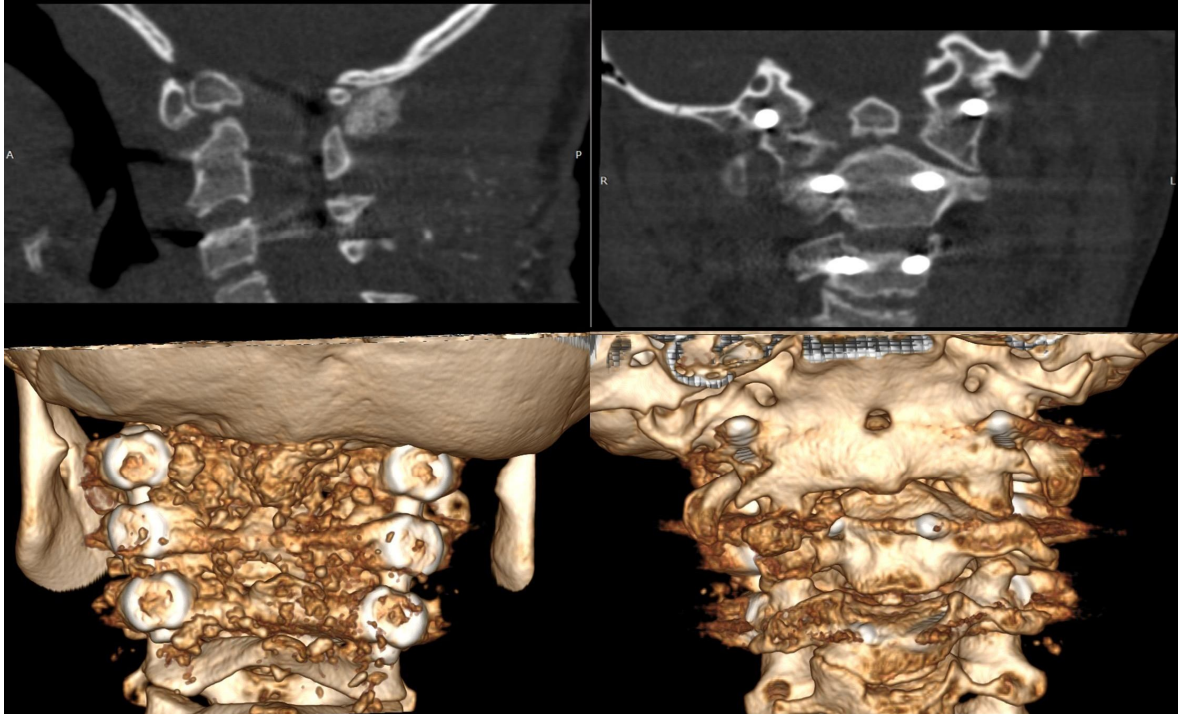


Fig. 13. MSCT image (11a - sagittal, 11b-axial, 11c-3D reconstruction). The craniovertebral angle is 136 degrees.

A postoperative MSCT study showed a proper correction of the LAAD. The axial dislocation was eliminated (Fig. 13a). The fixing rods were symmetrical relative to one another (Fig. 13b, c). At 3-month follow-up, MSCT and MRI images demonstrated that the instrumentation remained stable; the deformity did not progress, and a bone block started to form at the level of facet joint (Fig. 14). At the same time, the osodontoidum started to fuse with the C2 vertebra.

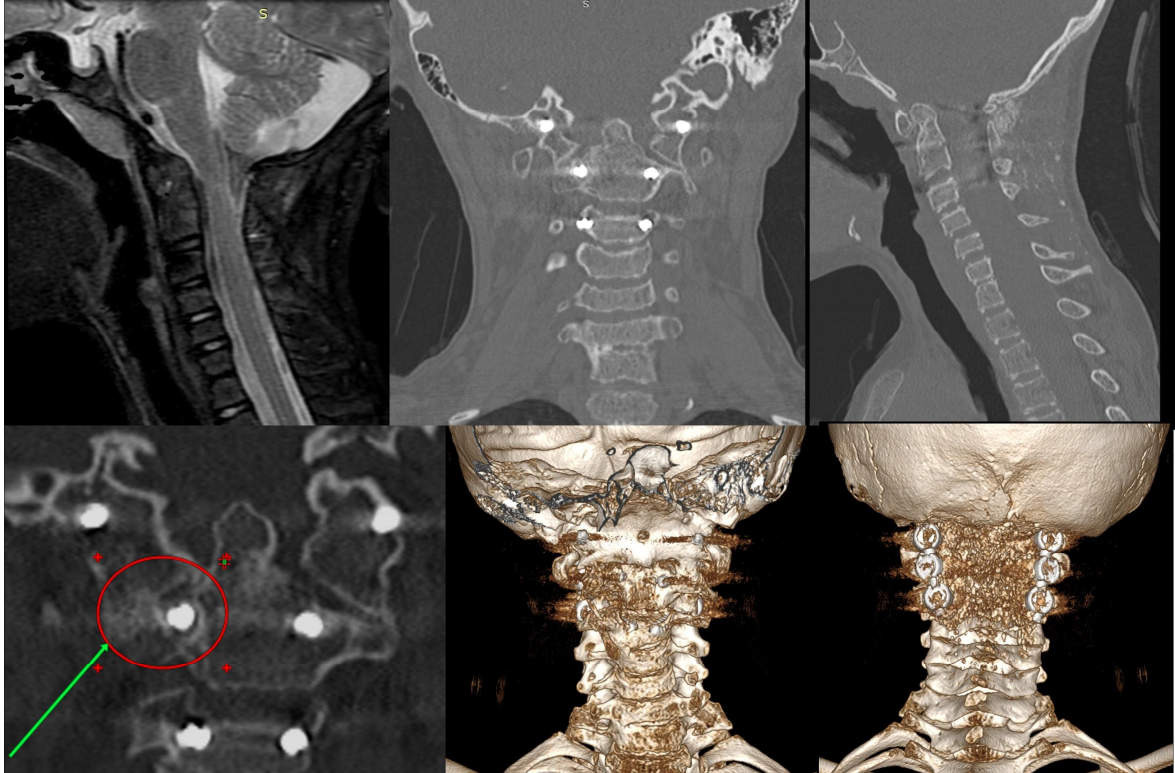


Fig. 14. MRI (14a - sagittal) and MSCT (14b - axial, 14c - sagittal, 14d – axial; the arrow marks bone block formation at the level of facet joint, 14e–3D reconstruction) images.

This case has demonstrated that AAD required the differential approach [17] that includes maximally symmetric positioning of the implants; individual selection of the fixation points and setting up the conditions for proper formation of a bone block at the level of facet joints.

Discussion

C1-C2 stabilization by Harms arthrodesis has been the golden standard for CVJ treatment [18] and provides a good result within the first 6 month [18, 11]. This approach can also be used for a staged treatment of complex CAADs. In case of unreducible dislocations, one may perform transoral decompression followed by dorsal fixation and occipital cervical fusion [19].

Delayed postoperative complications after C1-C2 stabilization by Harms arthrodesis can be divided into 2 groups: pseudoarthrosis without dislocation, and a dislocation due to instrumentation migration (see Table 1).

Table 1 : Complications with and without reoperation

Reference	Number of patients	Complications requiring reoperation	Complications without reoperation
adults			
Lee, Sun-Ho et al. (2010) [20]	27	1 - Non-union, loosening of rod, and needed repeated wound debridement.	1 - Pseudoarthrosis
Rezvani M. et al. (2021) [21]	27	No	1 - Pseudoarthrosis
Zheng, Y. et al. (2016) [22]	86	No	2 - Pseudoarthrosis
Guo J. et al. (2020) [24]	86	1 - patient developed infection after anterior release surgery, and needed repeated wound debridement. .	NET
Children			
Salunke P. et al. (2018) [9]	56	1 - patient in whom the joint was drilled incompletely, showed redislocation and reappearance of lateral angulation with increasing neck pain. The joints were remodeled again and fused.	1 - patient had vertical redislocation but no clinical worsening. The bones fused in this re-dislocated position.
Wang S. et al. (2016) [24]	32	1 - recurred torticollis followed by revision	No

The term LAAD was coined by Salunke et al. in 2016 [16]. The available data on the delayed complications caused by the condition are rather scarce since pseudoarthrosis has been registered in only 0.02% of operated adults and the redislocation – in 0.009%. In children, the redislocation has only been found in 0.03% of cases. To treat this pathology, screw fixation by Harms and facet joint spacer implantation are recommended [25], which is undoubtedly a reliable technique that provide a three-point fixation in addition to the screw fixation by Harms. However, a question arises whether it is necessary to immediately apply this rather traumatic technique in CAAD. Another issue is the spacer itself for it is very difficult to find specialized implants in case of children patients. In our center, we use tricortical autogenous bone grafts harvested from the spinous processes of cervical vertebrae or a fragment of a deproteinized allogenic bone matrix.

In the considered cases, LAAD recurrence was observed in the first case, and a lateral AAD formation concurrent to reduced anterior dislocation – in the second. It is noteworthy that the patients suffering from different original pathologies (congenital lateral and axial AADs, respectively) developed similar delayed complications (LAAD).

In both cases, the treatment included polyaxial screwing; bone block formation at the level of the dorsal column, and primary asymmetrical fixation relative to the C2 vertebral dent. As a result, the cranial screw turned relative to the caudal one, and the fixing rod changed its position that led to dislocation due to the sufficient continuous load on the instrumentation and absence of a facet joint block. In the first case, to resolve the issue and exclude instrumentation malposition, a longer mechanical level was used, setting up a fixation point in the occipital bonecondyle to provide an additional stability area on one side of the vertebrae. The effect given by a facet joint spacer was doubtful due to the vertical orientation of the pathologically changed vertebra, while the formed bone block significantly increased the cervical structure's rigidity. As

for the second case, using all possible fixation points including intra-articular ones to provide proper fusion produced an expected good result.

Having analyzed available literature data and our own experience, we have come to a conclusion that planning such corrective interventions requires an individual approach that accounts for the features of bone pathology. The procedure must include symmetrical rod fixation at the CVJ level. In absence of proper fixation, the rods may be extended to the occipital bone condyles and caudal segments to the degree of occipital cervical fusion. A facet joint spacer on the side of LAAD can be used for additional fixation and deformity correction. Another option is monoaxial screws that will limit screw head rotation in the frontal plane.

Conclusion

CAAD is a complex multiplanar deformity that requires a differential approach that accounts for the type of anomaly and the load put on the fixation points. Maximally symmetrical instrumentation positioning may help one avoid a recurrence of a formation of a new deformity in the postoperative period. A facet joint block prevents postoperative LAAD formation.

Ethical Approval:

As per international standard or university standard written ethical approval has been collected and preserved by the author(s).

Consent

As per international standard or university standard, Parentels' written consent has been collected and preserved by the author(s).

References:

1. Kumar, R., & Kalra, S. K. (2007). Pediatric atlantoaxial dislocation: Nuances in management. *Journal of Pediatric Neurology*, 5(1), 1-8.
2. Menezes A. H. (2008). Craniovertebral junction database analysis: incidence, classification, presentation, and treatment algorithms. *Child's nervous system : ChNS : official journal of the International Society for Pediatric Neurosurgery*, 24(10), 1101–1108. <https://doi.org/10.1007/s00381-008-0605-9>
3. Wang, S., Wang, C., Liu, Y. et al. (2009). Anomalous vertebral artery in craniovertebral junction with occipitalization of the atlas. *Spine*, 34(26), 2838–2842. <https://doi.org/10.1097/BRS.0b013e3181b4fb8b>
4. N V, A., Avinash, M., K S, S., Shetty, A. P. et al. (2019). Congenital Osseous Anomalies of the Cervical Spine: Occurrence, Morphological Characteristics, Embryological Basis and Clinical Significance: A Computed Tomography Based Study. *Asianspinejournal*, 13(4), 535–543. <https://doi.org/10.31616/asj.2018.0260>
5. Wang, S., Wang, C., Yan, M., et al. (2013). Novel surgical classification and treatment strategy for atlantoaxial dislocations. *Spine*, 38(21), E1348–E1356. <https://doi.org/10.1097/BRS.0b013e3182a1e5e4>
6. Ma, F., He, H., Liao, Y. et al. (2020). Classification of the facets of lateral atlantoaxial joints in patients with congenital atlantoaxial dislocation. *European spine journal : official publication of the European Spine Society, the European Spinal Deformity Society, and the European Section of the Cervical Spine Research Society*, 29(11), 2769–2777. <https://doi.org/10.1007/s00586-020-06551-z>
7. Sardhara, J., Behari, S., Sindgikar, P. et al. (2018). Evaluating Atlantoaxial Dislocation Based on Cartesian Coordinates: Proposing a New Definition and Its Impact on Assessment of Congenital Torticollis. *Neurosurgery*, 82(4), 525–540. <https://doi.org/10.1093/neuros/nyx196>

8. Pang, D., & Thompson, D. N. (2011). Embryology and bony malformations of the craniovertebral junction. *Child's nervous system :ChNS : official journal of the International Society for Pediatric Neurosurgery*, 27(4), 523–564. <https://doi.org/10.1007/s00381-010-1358-9>
9. Salunke, P., Karthigeyan, M., Sahoo et al. (2018). Improve, adapt and overcome-challenges in management of pediatric congenital atlantoaxial dislocation. *Clinicalneurologyandneurosurgery*, 171, 85–94. <https://doi.org/10.1016/j.clineuro.2018.05.024>
10. Goel, A., & Laheri, V. (1994). Plate and screw fixation for atlanto-axial subluxation. *Actaneurochirurgica*, 129(1-2), 47–53. <https://doi.org/10.1007/BF01400872>
11. Harms, J., & Melcher, R. P. (2001). Posterior C1-C2 fusion with polyaxial screw and rod fixation. *Spine*, 26(22), 2467–2471. <https://doi.org/10.1097/00007632-200111150-00014>
12. Elliott, R. E., Tanweer, O., Boah, A. et al. (2014). Atlantoaxial fusion with screw-rod constructs: meta-analysis and review of literature. *World neurosurgery*, 81(2), 411–421. <https://doi.org/10.1016/j.wneu.2012.03.013>
13. La Marca, F., Zubay, G., Morrison, T. et al. (2008). Cadaveric study for placement of occipital condyle screws: technique and effects on surrounding anatomic structures. *Journal ofneurosurgery. Spine*, 9(4), 347–353. <https://doi.org/10.3171/SPI.2008.9.10.347>
14. Kosnik-Infinger, L., Glazier, S. S., & Frankel, B. M. (2014). Occipital condyle to cervical spine fixation in the pediatric population. *Journal ofneurosurgery. Pediatrics*, 13(1), 45–53. <https://doi.org/10.3171/2013.9.PEDS131>
15. Yin, Q. S., & Wang, J. H. (2015). Current Trends in Management of Atlantoaxial Dislocation. *Orthopaedicsurgery*, 7(3), 189–199. <https://doi.org/10.1111/os.12196>
16. Salunke, P., Sahoo, S. K. et al. (2016). 'Atlas shrugged': congenital lateral angular irreducible atlantoaxial dislocation: a case series of complex variant and its

management. *European spine journal : official publication of the European Spine Society, the European Spinal Deformity Society, and the European Section of the Cervical Spine Research Society*, 25(4), 1098–1108. <https://doi.org/10.1007/s00586-015-4370-7>

17. Gubin, A. V., Ulrikh, E. V., Ryabykh, S. O. et al. (2017). Surgical roadmap for congenital malformations of the cervical spine. *Journal of Clinical and Experimental Orthopedics. GA Ilizarov Volume*, 23(2).DOI: <https://doi.org/10.18019/1028-4427-2017-23-2-147-153>
18. Bourdillon, P., Perrin, G., Lucas, F. et al. (2014). C1-C2 stabilization by Harms arthrodesis: indications, technique, complications and outcomes in a prospective 26-case series. *Orthopaedics & traumatology, surgery & research : OTSR*, 100(2), 221–227. <https://doi.org/10.1016/j.otsr.2013.09.019>
19. Tian, Y., Xu, N., Yan, M. et al. (2020). Atlantoaxial dislocation with congenital "sandwich fusion" in the craniovertebral junction: a retrospective case series of 70 patients. *BMC musculoskeletal disorders*, 21(1), 821. <https://doi.org/10.1186/s12891-020-03852-8>
20. Lee, S. H., Kim, E. S., Sung, J. K et al.. (2010). Clinical and radiological comparison of treatment of atlantoaxial instability by posterior C1-C2 transarticular screw fixation or C1 lateral mass-C2 pedicle screw fixation. *Journal of clinical neuroscience : official journal of the Neurosurgical Society of Australasia*, 17(7), 886–892. <https://doi.org/10.1016/j.jocn.2009.10.008>
21. Rezvani, M., Sourani, A., & Nikzad, H. (2021). Postoperative complications of Goel-Harms C1-C2 screw-rod fixation technique for C1-C2 instability after C2 nerve sacrifice, a prospective study over two years follow up. *Journal of clinical neuroscience : official journal of the Neurosurgical Society of Australasia*, 88, 52–56. <https://doi.org/10.1016/j.jocn.2021.03.012>

22. Zheng, Y., Hao, D., Wang, B. et al. (2016). Clinical outcome of posterior C1-C2 pedicle screw fixation and fusion for atlantoaxial instability: A retrospective study of 86 patients. *Journal of clinical neuroscience : official journal of the Neurosurgical Society of Australasia*, 32, 47–50. <https://doi.org/10.1016/j.jocn.2015.12.045>
23. Guo, J., Lu, W., Ji, X. et al. (2020). Surgical treatment of atlantoaxial subluxation by intraoperative skull traction and C1-C2 fixation. *BMC musculoskeletal disorders*, 21(1), 239. <https://doi.org/10.1186/s12891-020-03273-7>
24. Wang, S., Yan, M., Passias, P. G. et al. (2016). Atlantoaxial Rotatory Fixed Dislocation: Report on a Series of 32 Pediatric Cases. *Spine*, 41(12), E725–E732. <https://doi.org/10.1097/BRS.0000000000001414>
25. Salunke P. (2018). Congenital Atlantoaxial Dislocation: Nature's Engineering Gone Wrong and Surgeon's Attempt to Rectify It. *Journal of pediatric neurosciences*, 13(1), 1–7. https://doi.org/10.4103/JPN.JPN_73_17