

1
2
3
4
5
6
7
8
9
10

Replacement of the crown in a fractured tooth using the coronal tooth structure: A CLINICAL CASE REPORT

11 **ABSTRACT**

12 The anterior teeth are relatively prone to trauma. According to research, 37% of trauma cases involve the upper central incisors. Anterior tooth trauma resulting in a fracture fragment demands rapid care because of the psychological effects it has on the patient as well as the destruction it does to the dentition. This paper highlights a patient with the anterior tooth fracture which is managed immediately with re attaching the mobile tooth structure with successful result.

13 *Keywords: fracture tooth, anterior tooth fracture, crown attachment, fragment re attachment*

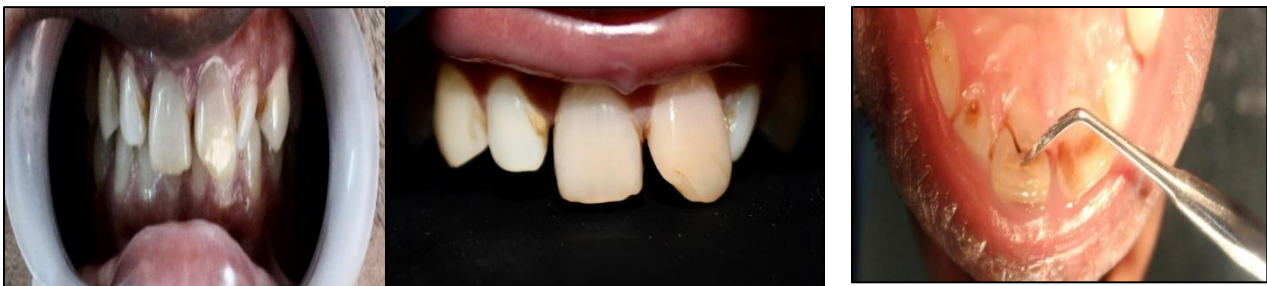14
15
16
17 **1. INTRODUCTION**

18 The anterior teeth are relatively prone to trauma. According to research, 37% of trauma cases involve the upper central incisors^[1]. Anterior tooth trauma resulting in a fracture fragment demands rapid care because of the psychological effects it has on the patient as well as the destruction it does to the dentition. ^[1] Depending on the degree and extent of the fracture, the treatment includes simple to extensive restorative intervention^[2,3].Tennery was the first to document the application of the acid-etch procedure as part of repair a broken fragment^[4]. Starkey and Simonsen have since documented such related cases^[5,6].Reattaching the original tooth fragment aids in preserving the restoration's translucency, morphology, wear resistance, and tooth colour. The patient's emotional and social response to the preservation of the original tooth structure is also positive^[7].The progress and improvement of adhesive techniques and restorative materials have made it possible to reattach a broken fragment^[8]. The therapy of a broken maxillary right central incisor treated endodontically, followed by reattachment of the same fragment, is described in the relevant case report.

11
12
13
14
15
16
17
18
19
20
21
22
23
24
25
26
27
28
29
30
31
32
33

34 **2. CASE PRESENTATION**

35
36 A 32-year-old male patient was referred to the D A P M R V Dental College and Hospital's
37 Department of Conservative Dentistry and Endodontics with a broken upper front tooth as his main
38 complaint. A comprehensive history from the patient revealed that the right central incisor (11) of the
39 maxilla was cracked three days prior due to biting force applied to the upper tooth region. The
40 maxillary right central incisor was found to have a mesiodistal fracture at the cervical third labially and
41 middle third palatally without the fragment being displaced after an intraoral examination. Due to the
42 incoherence of the fracture and the anchoring effect of the soft tissue palatally, the fragment was
43 movable (fig.1). A radiograph of the intraoral periapical area (IOPA) revealed no associated root
44 fracture. The periapical tissues and the alveolar bone both showed signs of inflammation. Regarding
45 the maxillary right central incisor, an Ellis Class III complex crown fracture (including the pulp
46 chamber) diagnosis was made. Due to the complexity of the fracture, a single-visit endodontic
47 procedure was chosen after obtaining patient's consent on the same. Reattachment of the same
48 fragment was intended because the broken pieces were still intact and still had some palatally
49 attached supporting tissue. Access was made labially through the broken area after local anaesthetic
50 was administered. The mobile fragment was then disengaged/extracted and kept in saline for future
51 operation. The chamber was irrigated with 5.25% sodium hypochlorite (NaOCl) and normal saline
52 after the coronal pulp tissue was removed. Initial root canal negotiations were carried out. With a no.
53 10 K-file, the root canal was initially negotiated, and a working length radiograph was taken. The root
54 canal was cleansed using 17% ethylenediaminetetraacetic acid (EDTA) and 5.25% sodium
55 hypochlorite. The root canal was then shaped using K files up to a size of 60K, followed by the step-
56 back technique up to a size of 110K, and then hand protaper files and K files. The root canal was
57 sealed with zinc oxide eugenol sealer and 2% gutta percha points after being dried with absorbent
58 paper points. After obtaining a post-obturation IOPA radiograph,(fig.2) it was determined that the root
59 canal filling was adequate.
60
61



62
63
64 (A)

(B)

(C)

65
66
67
68 Fig.1(A-C): pre operative view of 11
69 Labially and palatally
70
71
72

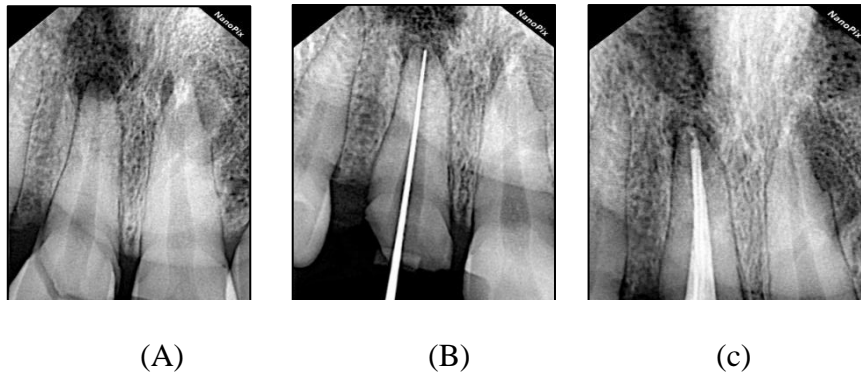


Fig.2: radiograph of a)pre operative; b) working length determination; c) obturation

2.1 Gingival tissue preparation techniques

It was done to contour the tissue well over buccal surface, measuring 1.5 mm from the mesial to the distal surface.

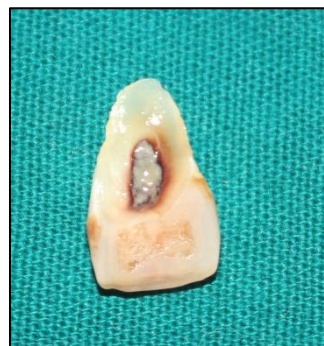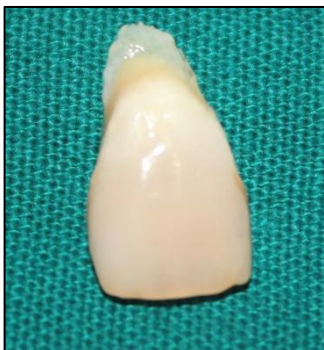The steps were taken to prepare the tooth's post space for a root canal, after obturation, the patient was brought back 24 hours later. This was followed by the preparation of the post space, during which the leftover gutta percha measured approximately 4.7mm. The appropriate post size was chosen to be a size 2 fibre post, and IOPAR was obtained for final confirmation. Once the fit was established, the post was bonded using single cure resin cement.

2.1.1 Technique for reattachment

The fragmented tooth surface was etched with 37% orthophosphoric acid for 15 seconds before being thoroughly washed with water and allowed to air dry (fig.3). The relocated fragment, etched surface, and tooth surface were all treated with a dentin bonding agent (Adper Single Bond, 3M ESPE). Prior to light curing, it was confirmed that the fragment had adapted to the tooth surface. On the labial and palatal sides, visible light curing was performed for 20 seconds each. Using a round bur, a 1-mm deep chamfer was created on the buccal surface medially and distally along the fracture line. The chamfer surface was treated with surface etching and bonding before a coating of microhybrid composite (Filtek Z250TM 3M ESPE) was applied.

In order to splint the piece to the tooth surface, ribbon was applied palatally. With Sof-Lex™ discs from 3M ESPE, the repaired surface was completed and polished. A final assessment of occlusion and aesthetics was performed.

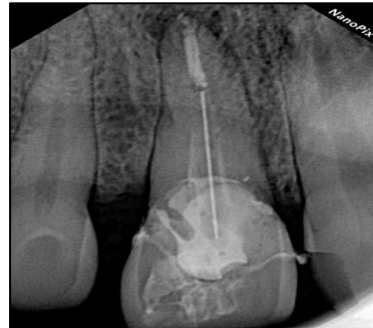
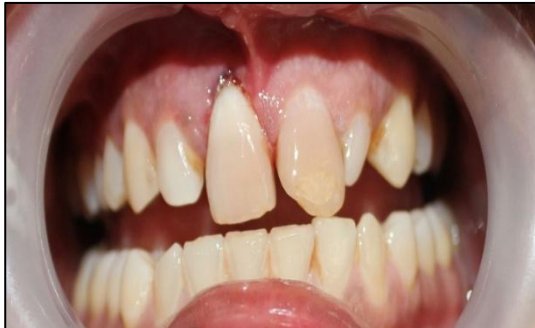The patient received postoperative instructions on how to avoid loading the anterior teeth, and one month later recall visits were scheduled. The postoperative time was documented and went well, had satisfactory results(fig. 4).



109 (A)

110 (B)

111 Fig.3(A-B): tooth mobile fragment
112 labially and palatally
113



117 (A)

118 (B)

119 Fig.4:a) re attached tooth fragment
120 clinically view
121 b) re attached tooth fragment
122 radiograph (post operative)
123
124
125
126
127

128 3. DISCUSSION

129
130 Dental trauma (DT) is a significant public health problem because of its occurrence , impact on economic
131 productivity, and quality of life. Trauma affecting younger age group and its prevalence ranges from 7.4% to
132 58%,most commonly involved teeth are the maxillary incisors, uncomplicated type crown fracture in the
133 permanent dentition is the most common type of injury and success rates can vary. Trauma in anterior teeth
134 region is a relatively a common frequency, as it involves patient's emotional response for preservation of
135 natural tooth structure. Hegde, R. J. [7] "Reattachment of broken tooth structure which involves both enamel
136 and dentin has been found to be satisfactory after a period of 1 year". Hegde, R. J. [7] "fractures involving
137 incisal edge of anterior teeth have been successfully tried and attempted by reattachment". Oz IA et al. [9]
138 Complicated "fractures involving pulp have been treated by reattachment of tooth fragment of anterior teeth
139 with additional support that is post and core".[10]

140
141 Use of isolation protocol that is rubber dam yields successful management of endodontic complications and
142 leads to conducive environment for quality adhesive dentistry. The following reattachment techniques have
143 been tried for reattaching the tooth fragment[11]:

- 144
- 145 1. A circumferential bevel
 - 146 2. an external chamfer at the fracture line
 - 147 3. creating a V-shaped enamel notch
 - 148 4. an internal groove
- 149

150 In the present case, the enamel notch technique was used, as it yields to increased strength than just simple
151 reattachment of fragment. Reis et al. have reported 60% recovery of fracture strength with incorporating

152 chamfer technique with minimal loss of natural fit of the fragment compared to any other methods which
153 increased the strength recovery, as it expose more resin surface to oral environment. [11] Reattachment of
154 fragment may offer the following advantages:

- 155 1. it is simple and conservative management
- 156 2. Better esthetics majorly translucency was maintained
- 157 3. Incisal edge wear at a rate similar to that of the adjacent teeth
- 158 4. A positive feedback as it maintains the emotional and social response from the patient

160 The disadvantages includes:

- 161 1. esthetics as in attached fragment
- 162 2.the attached tooth fragment is dehydrated
- 163 3. longevity is still questionable

164 Recent advances and newer generations adhesive system and resin based composites has made
165 reattachment of tooth fragments a procedure that is simple, conservative, satisfactory treatment with good
166 follow up it yields to favorable prognosis. However, this technique can be possible with preservation of broken
167 tooth fragment saved and conserved and to have actual fit as before or to maintain originality .[12] [13]
168 "Reattachment of the fractured tooth fragment with endodontic treatment and additional support of post and
169 core was possible in the present case as the fragment was intact".

172 **4.CONCLUSION**

173 Cases with esthetic management of traumatic injury demands judicious planning which involves sound
174 knowledge of the corresponding techniques available and their indications, along with risk benefit ratio. In case
175 of incisal re attachment procedure it offers simple, effective, conservative, aesthetic restorative option if incisal
176 edge segments are present. With the current adhesive systems available it provides the optimal bonding
177 strengths to withstand the masticatory forces in oral cavity but this interface is also susceptible to the effects of
178 cyclic fatigue and hydrolytic degradation with time. With all the given facts and protocol the case reports and
179 studies have presented functional and aesthetic success rate and time period of more than 7 years.

181 **COMPETING INTERESTS**

182 Authors have declared that no competing interests exist.

183 **CONSENT**

184 All authors declare that 'written informed consent was obtained from the patient (or other approved parties) for publication
185 of this case report and accompanying images.

186 **ETHICAL APPROVAL**

187 As per the international standard or university standard written ethical approval has been collected and
188 preserved by the authors.

189 **REFERENCES**

- 190 1. Andreasen et al JO, Andreasen FM. Textbook and color atlas of traumatic injuries to the teeth. Copenhagen:
191 Munksgaard; 1993.
- 192 2. Baratieri et al LN, Monteiro S. Tooth fracture reattachment: Case reports. Quintessence Int 1990 ;21:261-
193 70.

- 202 3. Chu FC, Yim TM, Wei SH. Clinical considerations for reattachment of tooth fragments. Quintessence Int
203 2000;31:385-91.
- 204 4. Tennery NT. The fractured tooth reunited using the acid bonding technique. Tex Dent J 1988;96:16-7.
- 205 5. Starkey PE. Reattachment of a fractured fragment to a tooth. J Indiana Dent Assoc 1979; 58:37-8. 6.
206 Simonsen RJ. Restoration of a fractured central incisor using original teeth. J Am Dent Assoc 1982;105:646-
207 64.
- 208 7. Hegde RJ Tooth fragment reattachment - an esthetic alternative: Report of a case. J Indian Soc Pedod Prev
209 Dent 2003; 21:117-9
- 210 8. Baratieri LN, Monteiro S. Tooth fragment reattachment: Fundamentals of the technique and the case report.
211 Quintessence Int 2003;34:99-107.
- 212 9. Oz IA, Haytaç MC, Toroglu MS. Multidisciplinary approach to the rehabilitation of a crown-root fracture with
213 original fragment for immediate esthetics: a case report with 4-year follow-up. Dent Traumatol. 2006 ;22:48-52.
- 214 10. Lehl G, Luthra R. Reattachment of fractured fragments of maxillary central incisors report of a case. J
215 Indian Soc Pedo Prev Dent 2004;22:54-5.
- 216 11. Reis A, Francci C, Loguercio AD, Carrilho MR, Rodrigues Filho LE. Re-attachment of anterior fractured
217 teeth: Fracture strength using different techniques. Oper Dent 2001;26:287-94.
- 218 12. Simonsen RJ. Traumatic fracture restorations: An alternative use of the acid etch technique. Quintessence
219 Int Dent Dig 1979; 10:15-22
- 220 **13.** KUMARI NB, SUJANA V, SUNIL CR, REDDY PS. REATTACHMENT OF COMPLICATED TOOTH FRACTURE: AN
221 ALTERNATIVE APPROACH. CONTEMPORARY CLINICAL DENTISTRY. 2012 APR;3(2):242.
222
223
224
225
226
227
228
229