

### **Atrioventricular block in young subjects induced by vagal hyperactivity and interest of exploring the autonomic nervous system. (About 4 cases)**

#### **Abstract**

Vagal hyperactivity, which corresponds to excessive activity of the parasympathetic system, is a frequent cause of syncope, fainting and dizziness, hence the interest of exploring the autonomic nervous system (ANS) for confirmation.

High-degree atrioventricular (AV) block in patients with a history of syncope usually requires pacemaker implantation, therapeutic strategies should also be considered in young patients especially in the case of non-structural cardiopathy.

We report 4 cases of repeated episodes of syncope in young patients who presented at the emergency with an atrioventricular block (AV-block) of different degrees without any structural cardiopathy. The completion of the etiology findings in these patients came out positive for vagal hypersensitivity after ANS test. The patients were placed on diet and pharmacological therapy with a good clinical outcome without the immediate need for cardiac pacemaker implantation.

**KEYWORDS:** Atrioventricular block; vagal hyperactivity; ANS test; Ethyl-phenyl- ephrine

#### **Introduction**

Conduction disorders in young subjects can have several etiologies. Most cases of dizziness or syncope referred to the emergency department or to services of internal medicine are caused by vasovagal syndromes. They comprise relative bradycardia with vasoplegia, the cardiovascular response to a neurological stimulus [1]. It should be noted that cardiac investigations are necessary, regardless of the diagnosis of syncope, whether reflex or orthostatic, in a patient with cardiovascular risk factors or an abnormality on the ECG. Indeed, it is important to eliminate a cardiovascular cause of syncope before concluding on the diagnosis of dysautonomic syncope [2]. Vagal hyperactivity, which corresponds to excessive activity of the parasympathetic system, is a frequent cause of syncope and fainting, hence the interest of exploring the autonomic nervous system (ANS) in young patients with conductive disorders without structural cardiopathy.

We report 4 cases of repeated episodes of syncope in young patients who presented at the emergency with an atrioventricular block (AV-block) of different degrees without any structural cardiopathy.

#### **Case Presentation**

We report the cases of 4 young patients aged 22, 28, 29 and 32 years respectively, with no particular history, followed in the cardiology department at the University teaching Hospital, Ibn Rochd of Casablanca. The first two patients initially presented at the emergency department for recurrence syncope whiles the two other patients consulted at the cardiology outpatient

department for dizziness during work efforts without syncope. The clinical examination was normal apart from arterial hypotension in the first patient. The baseline ECG was normal in the first patient (Figure 1), while the ECG of the second and third patient showed a second-degree AV-Bloc (Figure 2a and b) and fourth patient a high degree AV bloc with 2/1 conduction (Figure 3).

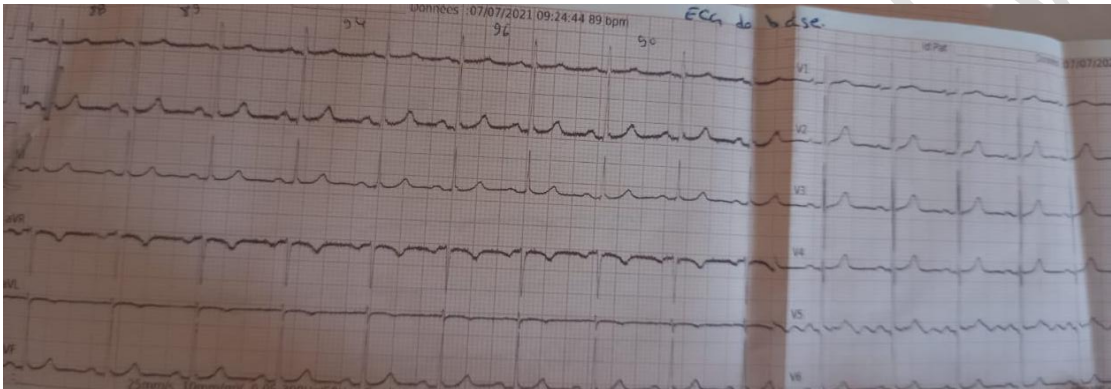


Figure 1: Electrocardiogram of Patient 1: Absence of abnormality.

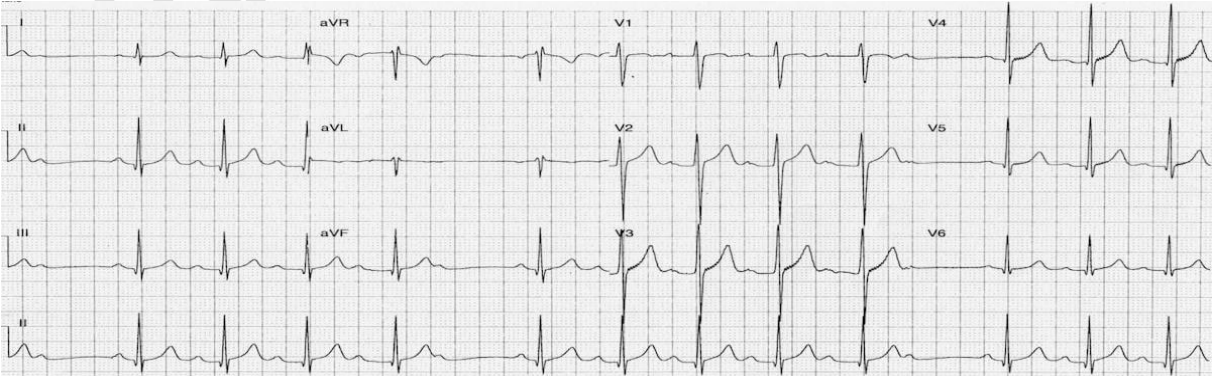


Figure 2: Electrocardiogram of Patient 2: 2<sup>nd</sup> Degree AV block Mobitz I

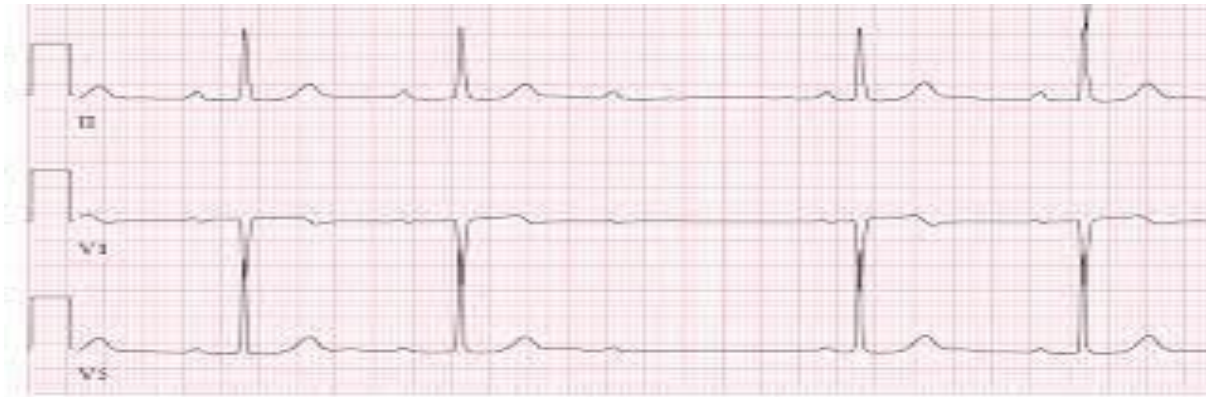

Figure 2b: Electrocardiogram of Patient 3: 2<sup>nd</sup> Degree AV block Mobitz II

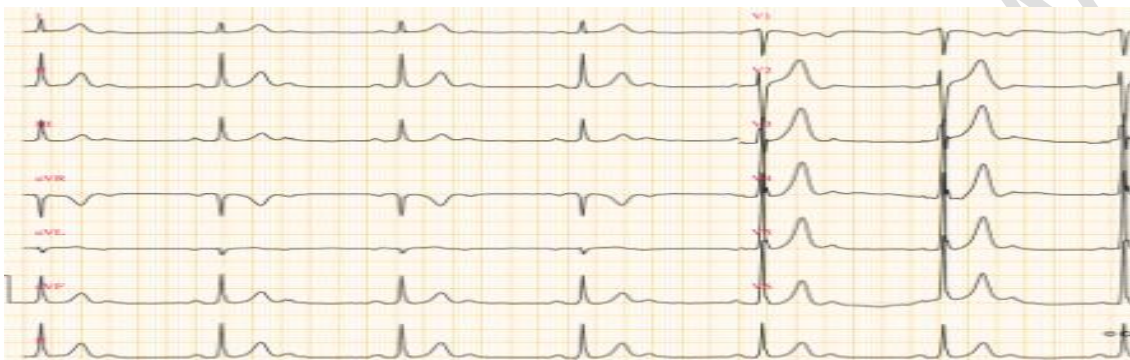

Figure 3: Electrocardiogram of Patient 4: High degree AV block 2/1 conduction.

The 24 hours holter ECG showed nocturnal paroxysmal first-degree AV block in the first patient whilst the other patients had a 2/1 atrioventricular block (Figure 4).

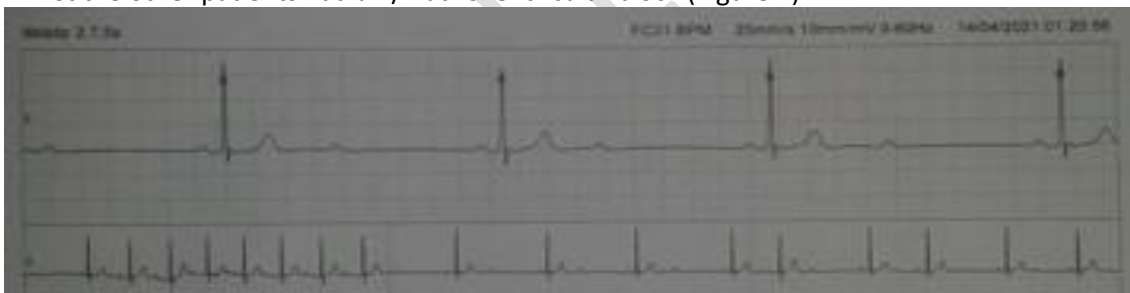


Figure 4: 24 Hours Holter ECG of our third Patient showing a high degree AV block of 2/1 conduction during the night recording.

A complete blood analyses was carried out in the patients including complete blood count test, electrolytes (especially magnesium, calcium, parathormone and thyroid hormones levels in the blood) came out within normal limits. Transthoracic echocardiography was done in all the patients which was normal. A complementary exam, the ANS tests was done in all patients, include deep breathing, isometric contraction, hyperventilation, orthostatic test, and mental stress. During deep breathing, the patient is asked to take a deep inspiration, block, then a deep expiration for one minute during which an ECG is recorded and the blood pressure is taken 3 times, which tends to drop during the deep breathing, on the ECG we calculate the difference between the longest RR space and that of the shortest RR space divided by the shortest RR space which is considered normal if its 30%, whereas a ratio greater than 30% is considered as vagal hyperactivity and vagal deficit if less than 30%. This exam showed a very high vagal response, a normal central and peripheral alpha and beta sympathetic response and a severe decrease in supine blood pressure (orthostatic hypotension) in all 4 patients after 3 minutes blood pressure recordings in supine position, concluding a vagal hyperactivity which was

responsible for the AV-block in the patients. These patients were put under nutritional diet based on enough rehydration with portable water up to a liter and half daily with additional salty food to bring up the blood pressure. This diet was associated at the same time with pharmacological therapy based on Ethyl-phenyl- ephrine, which is a stimulant of the cardiovascular system related to adrenaline and increases the flow of the heart and fights against the dilation of the blood vessels (Effortil drops, 10 drops par day titrated in respond to the blood pressure). Regular follow-ups in the patients were conducted, a good clinical outcome was observed in the patients 1 month after the treatment installation.

## Discussion

The causes of syncope can be categorized into three groups; 48% non-cardiogenic (including reflex syncope and orthostatic hypotension), 18% cardiogenic, and 34% unknown. Of the non-cardiogenic, 5% can be attributed to situational syncope syndromes, including defecation, micturition, cough, and swallow due to the deficiency of the autonomic nervous system [8]. The Autonomic Nervous System (ANS), also called the Vegetative or Involuntary Nervous System, is responsible for the rapid and permanent regulation of the very unstable internal environment, to modulate, regulate and harmonize the vegetative life of the different organs, thus contributing to the maintenance of homeostasis [3].

The parasympathetic innervation is distributed mainly to the sinus node, atrioventricular node and, to a lesser extent, to the biauricular and ventricular myocardium [4]. The sympathetic innervation concerns the whole of the heart with a distribution as marked at the level of the ventricle as elsewhere. Parasympathetic modulation has a negative chronotropic effect [5]. At rest, the HR is mainly under the vagal brake. Acetylcholine (ACh) released by parasympathetic neurons decreases the frequency of nervous discharge at the level of the sinus node. It has also a negative effect on the release of norepinephrine and attenuates the response to adrenergic stimulation[6].

Although high-degree atrioventricular (AV) block in patients with a history of syncope usually requires pacemaker implantation, therapeutic strategies should also be considered in young patients especially in the case of non-structural cardiopathy [7]. In this case report, our patients presented different type of AV blocks whilst there clinical, biological and echocardiography findings were without abnormalities despite the history of recurrence syncope in two of our patients, further exams were carried out to avoid pacemaker implantation since patients were of young age. The ANS test which finally confirmed a vagal hyperactivity with a ratio of more than 30%, helped in choice of therapy strategies thus the interest of ANS test in young patients before invasive therapy.

Manifestations related to vagal hyperactivity can take many forms. The set of clinical manifestations is called vagal syndrome [9,10] which was observed in our patients in this study ranging from dizziness, fainting and syncope.

Once the diagnostic of vagal syndrome was confirmed a medical treatment was chosen as a therapy strategy for our patients. In some case studies, Disopyramide a strong anti-cholinergic drug that acts not only on ventricular ectopic beats but also AV block and associated symptoms showed an effect on transient AV block related to vagal nerve activity. It has been proved that midodrine, an  $\alpha$ -1 adrenergic agonist, may be recommended rather than disopyramide in case of neural mediated syncope[11,8]. In our patients, a simultaneous food diet and pharmacological therapy was opted based on enough rehydration up to a liter and half of water, fairly high salty food and Ethyl-phenyl- ephrine ("effortil" at a starting dose of 10 drops par day titrated in respond of the blood pressure). However, in another study, phenobarbital was reported to insignificantly alter cardiac vagal discharge. Although ethyl-phenyl-ephrine is less known for improving AV conduction and used largely in the treatment of orthostatic hypotension compared to phenobarbital, some case

confirmed its benefits vagal hyperactivity [12,14]. It improves functional signs by the reduction in vagal activity [12]. Our patients presented orthostatic hypotension associated with vagal hyperactivity do our choice of treatment with ethyl-phenyl-ephine instead of phenobarbital. It has been noted in another study that cardiac pacemaker should be considered as alternative therapy in older patient [13].

The clinical outcome was positive in our patients one month after therapy installation and until present our patients did not need a pacemaker implantation which implies that in the case of orthostatic hypotension associated with vagal hyperactivity in young patients with AV bloc, ethyl-phenyl-ephine may improve clinical symptoms and AV conduction. The real challenge is if medical therapy should be interrupted after a short or long period of time after good evolution in our patients or continued permanently.

### Conclusion

Vagal hyperactivity can be a common cause of AV-block of different degrees especially in young subjects with no structural cardiopathy which needs further exploration, a complete ANS test in order for adequate patient management. Invasive therapy such as pacemaker implantation should be considered in patients with failed pharmacological therapy.

### Reference

1. J M Davy , L Beck, M Pons, F Raczka, M Ferrière. Vasovagal syndromes. Arch Mal Coeur Vaiss 1998; 91; 1:33-9.
2. K. Loubaris, H. Benjelloun. Thèse, Les syncopes dysautonomiques, apport diagnostic de l'exploration cardiovasculaire du système nerveux autonome, à propos de 60 cas. Google scholar 2015 : <http://ao.um5.ac.ma/xmlui/handle/123456789/15222>
3. Mathias CJ and Bannister R. Autonomic failure. A text book of clinical disorders of the autonomic nervous system 4th edition (1999).
4. Lahlaidi A Anatomie topographique, le système nerveux végétatif. 1986a ; 79
5. Lauralee Sherwood, physiologie humaine 2ème édition 2008 ; 191.
6. Serratrice G, Verschueren A : Système nerveux autonome. EMC Neurologie 2010.
7. Yukoh Hirai, Hideya Yamamoto, Yukiko Nakano, Hiroshi Ogi, Shinji Kajiwara, Nobuoki Kohno. Disopyramide for transient high-degree atrioventricular block in a young patient with a history of syncope. Journal of Cardiology 2008; 52; 59—61.
8. Irene Lambiris, Ivan Mendoza, Marcelo Helguera, Jose Baez Escudero & Cesar Bonilla Thirty years of blackouts: a case report of swallow syncope, Journal of Community Hospital Internal Medicine Perspectives, 2013; 3:1.
9. H.Benjelloun, L Coghlan, M Benomar Coghlan HC. Orthostatic intolerance in mitral valve prolapse. SNA: syndromes dysautonomiques, Maroc medical, 2003 ; tome 25 n°1.
10. Christopher J Mathias, Autonomic diseases: clinical features and laboratory evaluation. Journal of neurology, neurosurgery and psychiatry 2003; 74; 31-41.
11. Kaufmann H, Saadia D, Voustianiouk A. Midodrine in neurally mediated syncope: a double-blind, randomized, crossover study. Ann Neurol 2002:342—5.

12. Lathers C. M, Schraeder P. L, Carnel S. B. Neural mechanisms in cardiac arrhythmias associated with epileptogenic activity: the effect of phenobarbital in the cat. *Life Sciences* 1984; 34; 1919-1936.
13. Ronit Shohat-Zabarski, Zaza Iakobishvili, Jairo Kusniec, Alexander Mazur, Boris Strasberg. Paroxysmal atrioventricular block: clinical experience with 20 patients *International Journal of Cardiology* 97, 2004; 399– 405.
14. A.A.Gueboub ,H.El Jadi , A.Meftah A.Moumen, S.Moussaoui, G.Belmejdoub. L'efficacité du phénobarbital dans le traitement des dysrégulations du système nerveux autonome. *Annales d'endocrinologie*, 2014 ; 75 ; 424

UNDER PEER REVIEW