

## **Case study**

Serpentine thrombus of the right cavities of the heart extending to the trunk of the pulmonary artery complicating a uterine leiomyosarcoma without pulmonary embolism: A Case Report and literature review

### **Abstract**

Serpentine thrombus or snake like floating thrombus of the right-side cavities of the heart is a rare diagnosis and constitutes a real therapeutic emergency. Two-dimensional transthoracic echocardiography helps to confirm the diagnosis while Angio CT-Scan confirms the presence of pulmonary embolism. Treatment may involve surgical thrombectomy or intravenous thrombolysis but the use of medical treatment alone is never a solution and depends on case by case.

We report a rare case of a patient followed in the oncology department for locally extended uterine leiomyosarcoma under chemotherapy who presented aggravating symptom of dyspnea at the emergency department where a serpentine thrombus was diagnosed by transthoracic echocardiography. Angio CT SCAN showed no signs of pulmonary embolism and patient was placed on LMWH due high bleeding risk with a good outcome under strict hospital surveillance. This case reflects the difficulty of therapy choice in some population of patients with high risk of mortality in the presence of floating thrombus with high bleeding risk.

### **Abbreviation**

Angio CT SCAN: Angio computed tomography scan

LMWH: Low Molecular Weight Heparin

TTE: Transthoracic echocardiography

HASBLED: Bleeding risk score

i.e: that is

Angiovasc: Cardiopulmonary pump system to remove complex thrombi

### **Introduction**

Floating thrombus (serpentine thrombus) of the right-side cavities of the heart is a rare diagnosis and constitutes a real therapeutic emergency [1]. Serpentine thrombus seen in the right atrial is very pathognomonic of thrombus being dislodged from the deep veins of the lower limbs. It's particularly a serious clinical form of thromboembolic disease as its a sign of impending embolism, often already associated with severe pulmonary embolism [1,2].

We present the case of a patient followed at oncology department for a uterine leiomyosarcoma at the stage of pulmonary metastases, and in whom a transthoracic echocardiography was performed due to aggravating dyspnea symptom, which objectified a serpentine thrombus of the inferior vena cava extended all over the right heart cavities to the trunk of the pulmonary artery without pulmonary embolism.

### Case Report

We report the case of a female patient aged 47, with no cardiovascular risk factors. She has been followed since April 2022 for uterine leiomyosarcoma under chemotherapy, revealed clinically by metrorrhagia of which the diagnosis was retained on histological evidence of a peritoneal sample. Patient presents at the emergency department for worsening dyspnea symptom that has been evolving for 3 weeks, with no other associated clinical symptoms.

Somatic examination found a hemodynamically stable patient, polypnea at 24 cycles per minute with a left parasternal presystolic murmur coded 3/6th at the level of the fourth intercostal space. We also noted a great abundance of ascites during abdominal exam and bilateral white soft pitting sloping and painless oedemas of the lower limbs. Pulmonary auscultation was normal. The biological assessment objectified a microcytic hypochromic anemia at 8g/dl with mild thrombopenia, platelet levels at 135,000U/l.

Transthoracic echocardiography (figures 1, 2) performed showed a “serpiginous” hyperechoic intra-cavitary mass at the right heart side with no adherence to the heart cavity walls, floating and extending to the trunk of the pulmonary artery. In addition, the right cavities were not dilated, the RV/LV ratio  $<1$ , with a conserved biventricular function. There were no other echocardiography abnormalities.

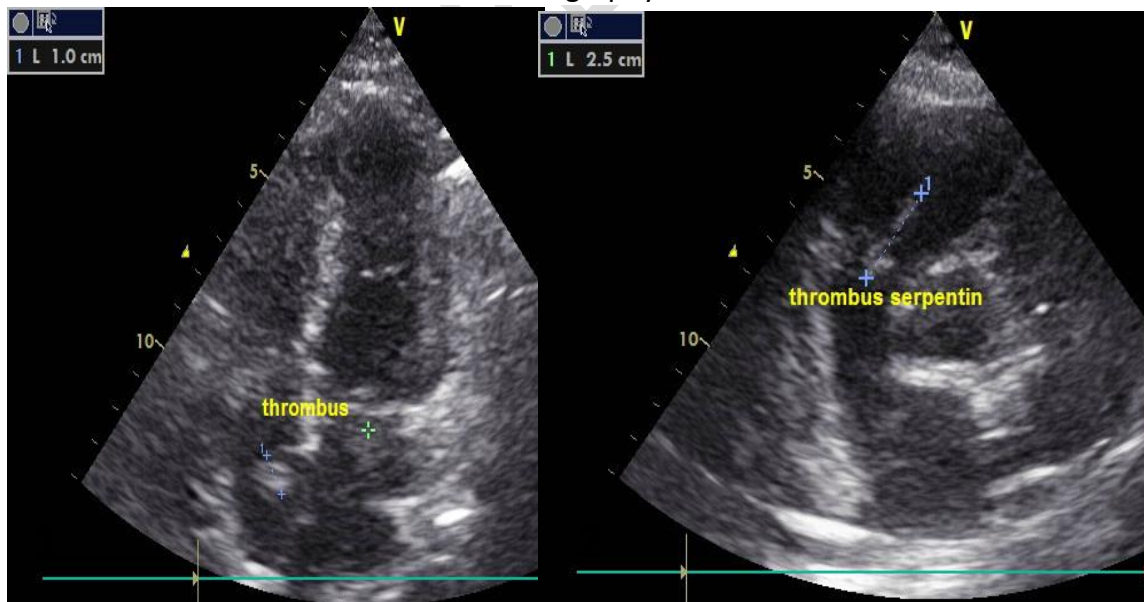


Figure 1:Transthoracic Echocardiography (TTE): 4 apical chamber view: Tail of the serpentine thrombus floating in the right atrium of the heart measuring 1cm long without dilated right atrium.

Figure 2: TEE: Small axis view: Head and the middle piece of the serpentine thrombus in the right ventricle during diastole measuring 2.5cm on its long axis.

A venous vascular doppler ultrasound studying of the deep veinous network of the lower limbs was performed, which confirmed the absents of deep vein thrombosis.

An Angio CT- scan (figure 3) was also performed, revealing no pulmonary embolism neither in the proximal nor the distal segmentation of the lungs.

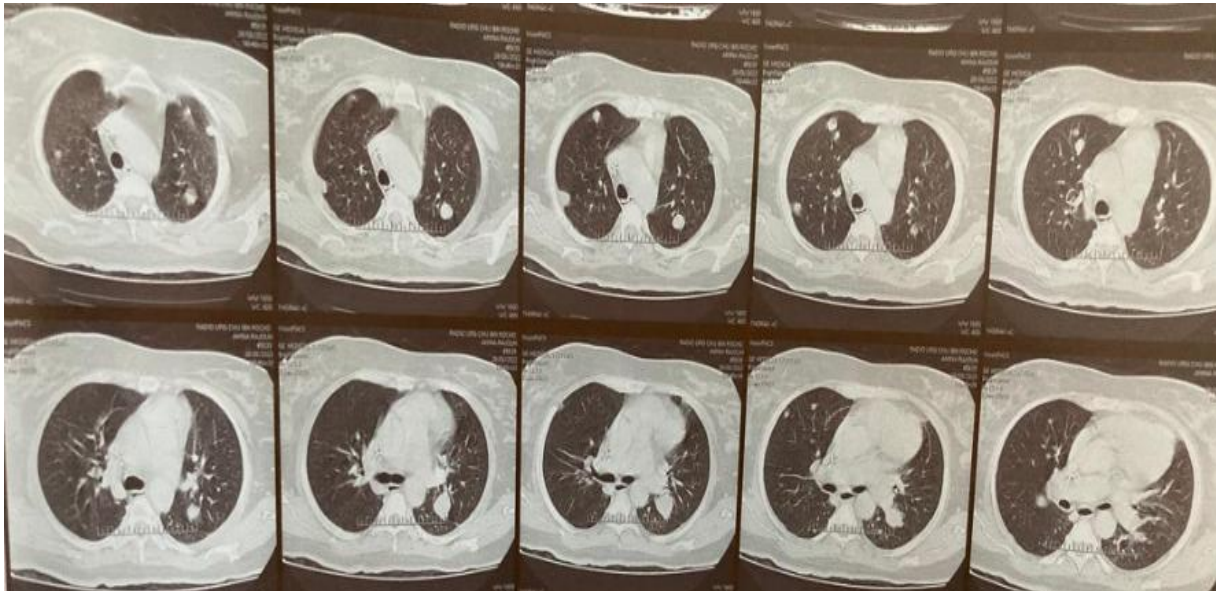


Figure 3: Angio CT-scan: Parenchymal view: Absence of pulmonary embolism

The patient was placed on low molecular weight heparin at a curative dose according to her weight despite the moderate hypochromic microcytic anemia of 8 g/dl and mild thrombopenia. No thrombolysis was performed due to the absence of serious pulmonary embolism and also due to the high risk of hemorrhage with a HASBLED score  $\geq 3$ .

A good clinical and radiological outcome was noted, improvement of the respiratory state of the patient with the disappearance of the intra-cavitary thrombus 1 month after the commencement of the anticoagulant therapy i.e LMWH with a minor vaginal bleeding side effect.

## Discussion

A floating thrombus of the right-side cavities of the heart is rare, it has been the subject of publications each relating to one or more cases. It can be extreme emergency, and is often fatal due to the migration of small thrombus with can completely obstruct the pulmonary trunk. According to studies, it concerns 7 to 11% of thromboembolic diseases, thus justifying the systematic performance of echocardiography as soon as a pulmonary embolism is suspected.

The circumstances of discovery are diverse: most often, there is a context of severe or recurrent pulmonary embolism [3,4], with clinical signs suggestive of acute cor

pulmonale. Thrombosis of the lower limbs is not necessarily present in case of severe pulmonary embolism but can be orienting sign [2,5]. A tricuspid obstruction syndrome can be observed, resulting in paroxysmal syncope [4] or sudden death [6]. Although less common and of unusual location, thrombosis of the inferior vena cava is not exceptional and can be the cause of thrombus in the right cavities by extension. Basically, when it is present, it results in bilateral signs that occur in one or two successive stages (tilting venous thrombosis). On the other hand, in our case, the patient does not present either pulmonary embolism or deep vein thrombosis despite the echocardiographic appearance of a long significant serpentine thrombus of the right-side cavities of the heart.

Two-dimensional transthoracic echocardiography makes the diagnosis [6,7,8].

It most often shows dilated right cavities and a “serpentine” hyperechoic image of the prolapsed right atrium between the tricuspid valves towards the right ventricle [4] whereas in our patient, there was no dilated right atrium which can simply explained by absents of total obstacle of the pulmonary trunk. In the context of pulmonary embolism, echocardiographic images of the floating thrombus and cor pulmonale are sufficient to suggest the diagnosis, without resorting to pulmonary angiography [6,4]. In our case an angio CT-Scan was done as the patient was stable. The prognosis of floating thrombus of the right heart is reserved but mortality is very high, greater than 40% [9, 10]. This poor prognosis is linked to the combination of several factors: very high embolic risk, severe pulmonary embolism associated with detection of the thrombus, peripheral phlebothrombosis, source of recurrent embolic events.

Treatment may involve surgical thrombectomy or intravenous thrombolysis. AngioVac (AngioDynamics) large-bore catheter system can also be used for the removal of large thrombi in various clinical situations [10]. In our case patient was placed on LWMH at a curative therapy dose alone with success given the high risk of bleeding score in the patient. The echocardiographic control of our patient showed the absence of intra-auricular thrombus. The literature reports only a few rare cases of favorable evolution under medical treatment alone [11].

This case report is original, as it concerns a rare case of extensive thrombosis, from the inferior vena cava to the trunk of the pulmonary artery, without echocardiographic signs of acute cor pulmonale, or pulmonary embolism at thoracic CT angio-Scan with a favorable outcome under heparin therapy alone despite the patient's high risk of bleeding.

## **Conclusion**

Floating thrombus “serpentine thrombus” of the right-side cavities of the heart is a rare but extremely serious event. It should be considered an immediate threat; because if left untreated, mortality can reach 90%. The association of right chamber thrombosis and pulmonary embolism has a poor prognosis. Heparin is often insufficient even when the clinical condition is stable, but in the face of a high risk of bleeding, heparin alone can be of benefit to the patient under strict surveillance.

## Reference

- (1) VIDYASHREE HULKOTI , SANDEEP KAMAT , SOURYA ACHARYA , SAMARTH SHUKLA , SUNIL KUMAR , DHRUV TALWAR. Serpentine Thrombus in Right Atrium: A Tell-Tale Sign of Venous Thromboembolism. *Cureus*. 2021 Dec 10; 13: e20336
- (2) Bagga C, Ansari I, Garikapathi A, Irshadv, Naik S, Agrawal S, Kumar S: Status epilepticus presenting feature of pulmonary embolism: rarest of rare combination. *Med Sci*. 2020, 24:3277-80.
- (3) FARFEL Z, SHECHIER M, and al. Review of echocardiographically diagnosed right heart entrapment of pulmonary emboli-in-transit with emphasis on management. *Am Heart J*, 117: 171-178, 1987.
- (4) GRAS D, BEDOSSA M, LEHELLOCO A, et al. Thrombose auriculaire droite et embolie pulmonaire grave. *Arch Mal Cœur*, 85: 253-256, 1992
- (5) TAUPIN JM, CHAPOUTOT L, METZ D, et al. Thrombus flottant de l'oreillette droite dans l'embolie pulmonaire aigue. Aspects chroniques, écho cardiographiques et incidences thérapeutiques. *Ann Cardiol Angéiol*, 37: 243-247, 1988
- (6) BENICHOU M, BERNARD P J, SARRAT P, et al. Détection des caillots intracardiaques par la scintigraphie aux plaquettes marquées à l'indium 111 Confrontation avec l'échographie bidimensionnelle et la scanographie cardiaque. *Arch Mal Cœur*, 77: 1054-1063, 1984
- (7) Agnes Mayr, Gert Klug, Simon Greulich, Bernhard Metzler, Gudrun Feuchtner. Serpentine-like right atrial mass and fulminant bilateral pulmonary embolism during treatment with rivaroxaban. *Int J Cardiovasc Imaging*. 2016 ;3:1001-2.
- (8) *D.Attias, E.Abitbol, S. Russel, J.Paziaud, P.Lim, C.Roiron, J.-L.Monin, P.Guéret, J. Garot* Thrombus serpentin récidivant des cavités cardiaques droites. *Presse Med* 2005; 34: 1337
- (9) FELNER JM, CHURCHWELL AL, MURPHY DA. Right atrial thromboemboli : clinical, echocardiographic and pathologic manifestations. *J Am Coll Cardiol*, 4 : 1041-1051, 1984.
- (10) Patnaik S, Rammohan HS, Shah M, Garg S, Figueredo V, Janzer S, Shah S. Percutaneous Embolectomy of Serpentine Thrombus from the Right Atrium in a 51-Year-Old Man. *Tex Heart Inst J*. 2016 Dec 1;43:524-527
- (11) CORMAN C, ROUDAUT R, GOSSE P, et al. Thromboses de l'oreillette droite : aspect échocardiographies, conduite pratique. A propos de 8 cas. *Arch Mal Cœur*, 79: 464-471, 1986