

Case study

A coronary artery aneurysm with a large subepicardial ischemia in a patient undergoing a valvular heart surgery: Should a coronary artery bypass be combined or not? A Case report

Abstract :

Coronary artery aneurysm (CAA) is a rare coronary disease defined as a dilation of a coronary artery 1.5 times or more its normal size. It is often revealed by an acute myocardial infarction however sometimes it can be completely asymptomatic. Because of the relative rarity of this disease, there is no consensus on its management options and controversy persists regarding the use of medical or surgical modalities. The study report an unusual case of a CAA associated with a large subepicardial ischemia discovered incidentally in a patient undergoing surgery for severe mitral stenosis. The aim of this case report is to show the unusual association between coronary artery aneurysm and mitral stenosis, and to discuss the therapeutic management of coronary artery aneurysm in such an association, thereby demonstrating the necessity of elaborating recommendations for the management of coronary artery aneurysm.

Key words : coronary artery aneurysm –heart surgery-management

1. Introduction

“Coronary artery aneurysms (CAA) is an uncommon condition that is defined as a localized saccular or fusiform dilation of a coronary artery that is larger than the diameter of the normal vessel adjacent segment by 1.5–2 times” (1). It is found in up to 5% of patients undergoing coronary angiography (2) In contrary Ectasia is used to describe a diffuse dilation that involves at least 50% of the length of the artery.(3) The case that we present is an aneurysm of the proximal left anterior descending artery associated with a severe mitral stenosis. The aim of this work is to show the unusual association between coronary artery aneurysm and mitral stenosis, and to discuss the therapeutic management of coronary artery aneurysm in such an association, thereby demonstrating the necessity of elaborating recommendations for the management of coronary artery aneurysm.

2. Case presentation :

A sixty three (63) years old man with no modifiable cardiovascular risk factors and no particular medical history was admitted to our center with complaint of dyspnea and

palpitations. Physical examination found a blood pressure of 120/65 mmHg, a pulse rate of 60 beats per minute, with an irregular heart rhythm and a normal body temperature. The electrocardiogram revealed an atrial fibrillation, a low voltage QRS and negatives T waves (Figure 1). The transthoracic echocardiography showed a severe mitral stenosis associated with an important tricuspid regurgitation, a normal left ventricle systolic function with no wall motion abnormalities (Figure 2). As part of the preoperative assessment, a coronary angiography was performed that showed an aneurysm of the left anterior descending artery with a low flow. There was no atheromatous lesion. The right coronary artery and the left circumflex artery were normal.

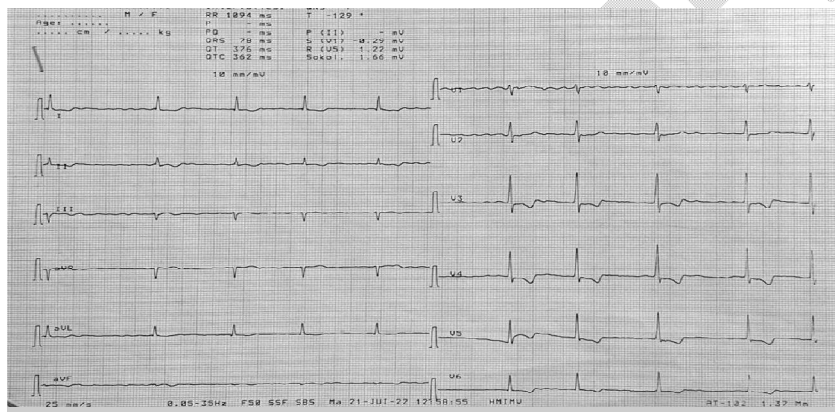


Figure 1 ECG showing a low voltage, negative T waves and an AF

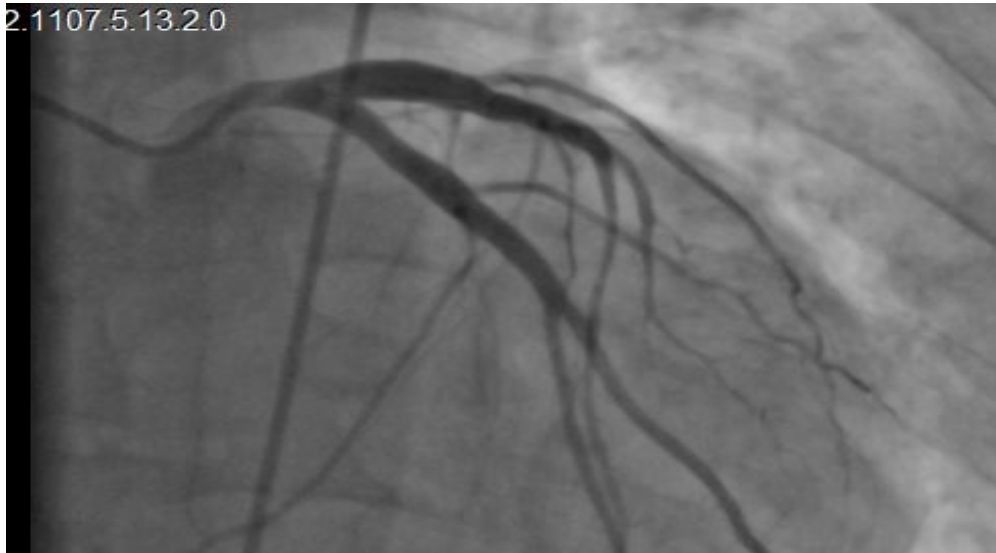

Figure 2 Aneurysm of the left anterior descending artery

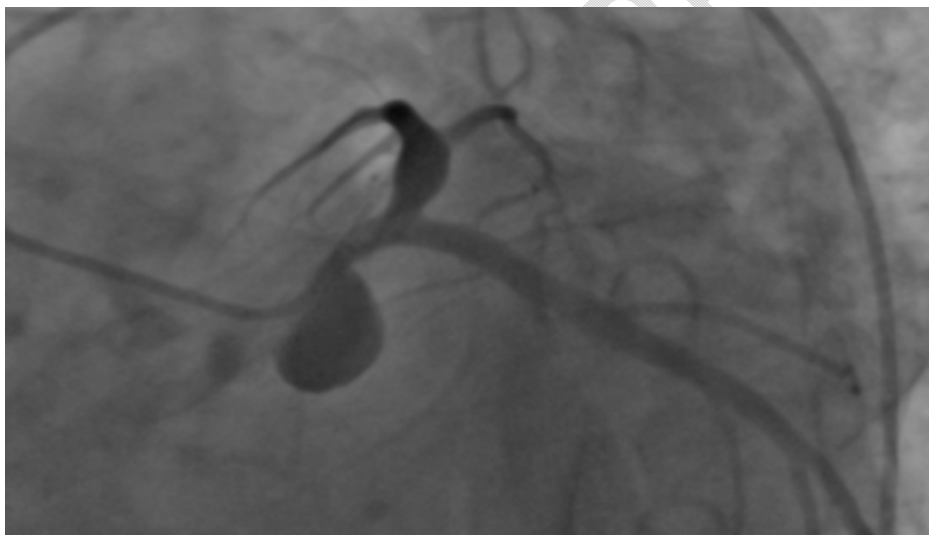


Figure 3 Aneurysm of the left anterior descending artery with a low flow

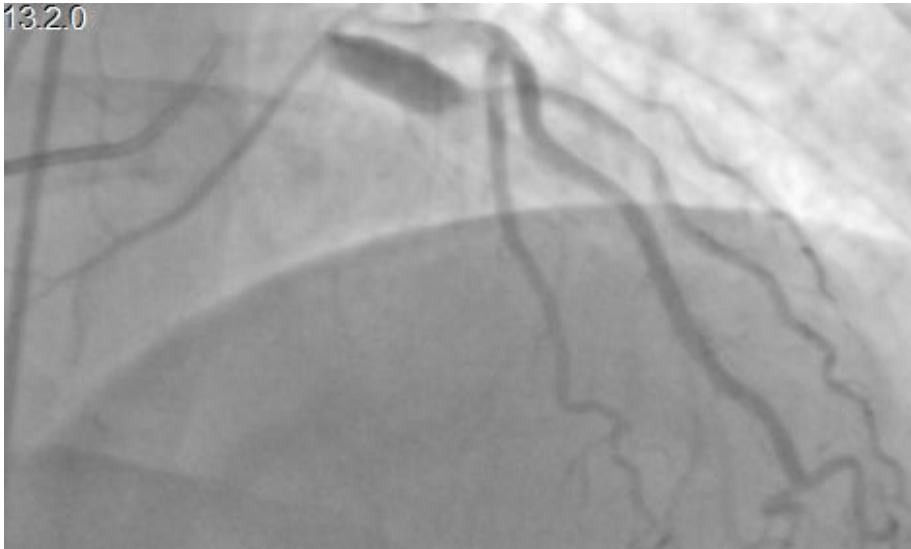


Figure 4 Aneurysm of the left anterior descending artery with a low flow

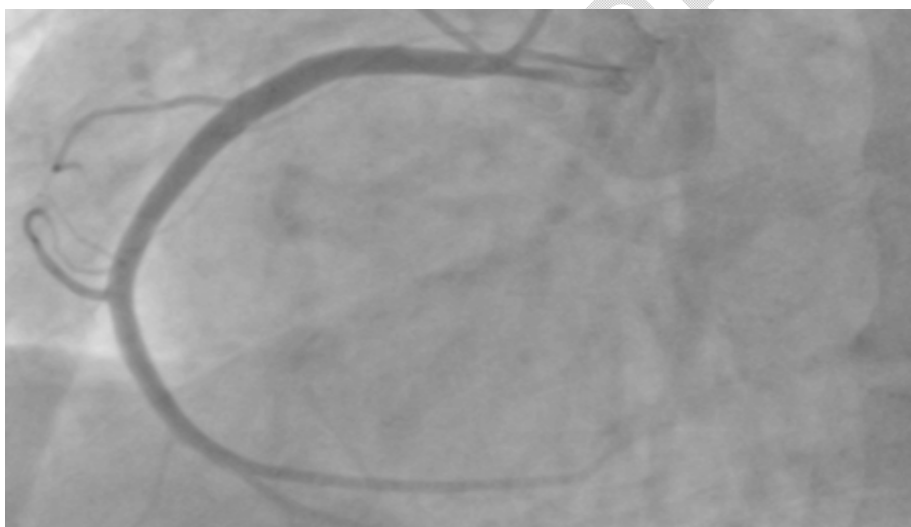


Figure 5 The right coronary artery

3. Discussion :

"The reported incidence of coronary aneurysms ranges from 0.3% to 5%, with predilection to men more than women. And it is most commonly diagnosed in late middle-aged patients".(2,4,5) "The right coronary artery is usually the most affected artery (40%) especially the proximal and middle segments followed by the left anterior descending artery, the left circumflex artery and at last the left main coronary" (6) The left anterior descending artery was the one involved in our case. Physiopathology of CAA is not well established but it is always associated with destruction of the media (4) .Atherosclerosis is the most common cause (50%) followed by congenital heart disease ,and kawasaki in asian countries .(7)Other

aetiologies can be found such as traumatic post coronary intervention , syphilis , Borreliosis, auto immune vasculitis (behcet ...) or connective tissue disease (Marfan , ether Danlos). In our case , atherosclerosis was excluded by coronary angiography and other aetiologies mentioned above were ruled out by history taking, clinical examination, and laboratory tests. However the association with a mitral stenosis raises the question of any correlation between mitral stenosis and coronary aneurysm. Such an association is not classically described. However our literature search found one isolated case of this association reported by Mohammad Masoumi et al .(8) There are no clinical symptoms specific to coronary artery aneurysms . CAA can be revealed with symptomatic acute coronary syndrome, stable angina... However Patients with CAA can be completely asymptomatic, and it can be discovered incidentally during angiography when performed for silent ischaemia or a preoperative check up. In our case, there was no chest pain but a sub-epicardial ischemia.

“The optimal therapy for patients with the coronary artery aneurysm is unknown and controversy persists regarding the use of medical or surgical modalities” .(2)

However most authors agree that invasive therapy such as surgical exclusion of the CAA should be reserved for patients with significant coronary stenosis or those with large CAA.

Percutaneous treatment with covered stent placement have also been used as non-surgical alternative in patients with prohibitive surgical risk

“Conservative or medical management is preferred for small asymptomatic coronary aneurysms. These patients are treated with antiplatelet therapy, anticoagulation to decrease the risk of thromboembolic complications along with the control of cardiovascular risk factors” .(9)

Through out the literature the cases of patients with CAA undergoing a cardiac surgery were rarely reported. And This becomes necessary to discuss particularly when the CAA is responsible of a large sub-epicardial ischemia like the case of our patient.

V. Pham et al discussed the management of the CAA and suggested a surgical exclusion of the CAA when a concomittent surgery is indicated . (7)

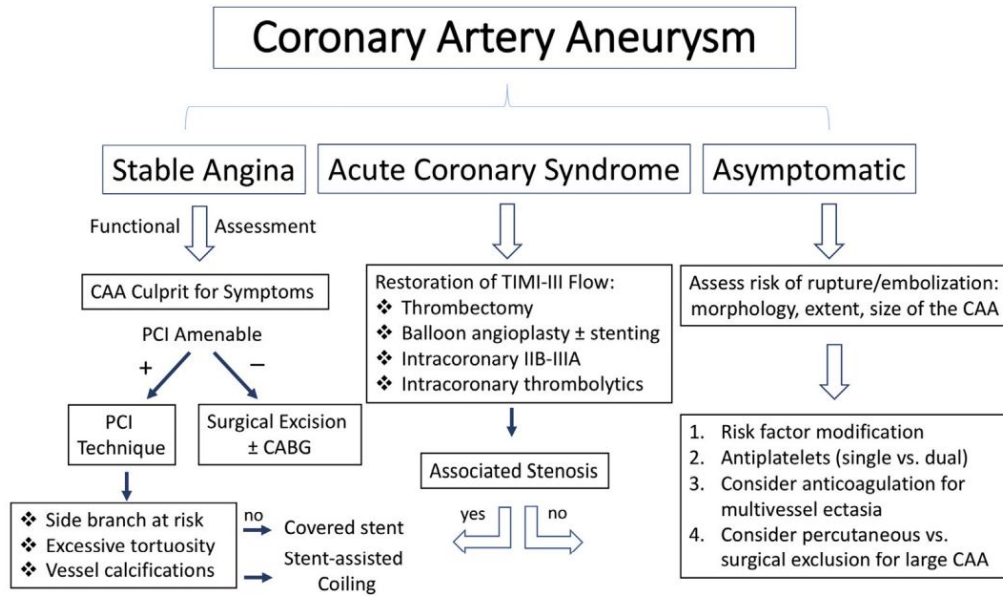


Figure 6 : A Suggested Algorithm for Management of Patients With CAA (2)

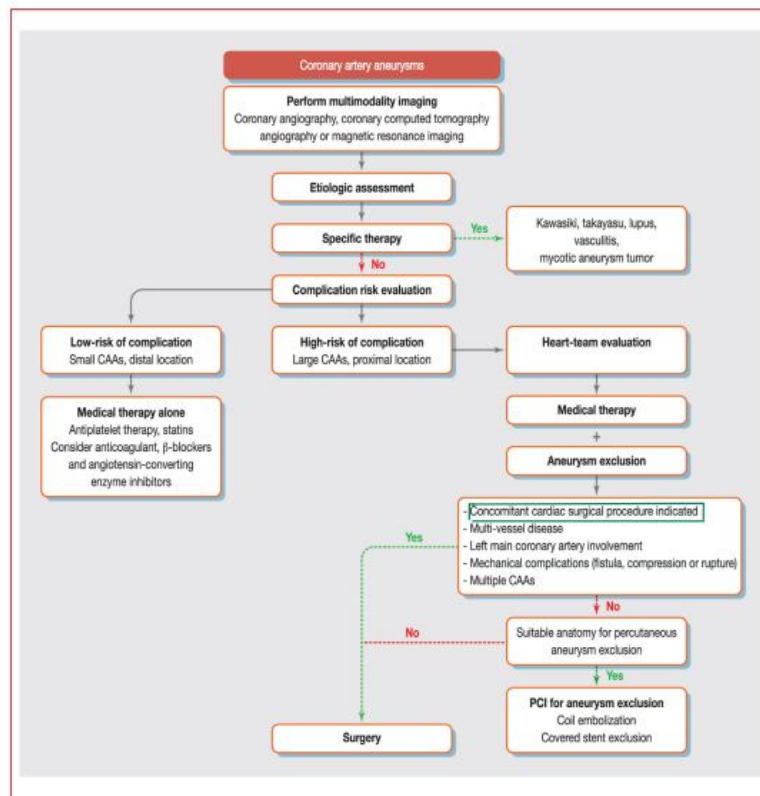


Figure 7 : An algorithm suggested by V. Pham et al. for the management of coronary artery aneurysm (CAA)

In our case , it was clear that the electrical abnormalities in such a large territory are due to the CAA making it unnecessary to undergo any functional ischemia test. This is explained by the stagnation of blood in the CAA compromising the perfusion of the downstream territory. For the treatment, the decision of the multidisciplinary staff was to use medical therapy even though the patient had a valvular heart surgery.

4. Conclusion :

Patients with CAA are usually asymptomatic but sometimes they can present with symptoms of coronary artery occlusion. The atherosclerosis is the most common cause. The optimal therapy for patients with the CAA is unknown. Recommendations become necessary to standardize the management of CAA in general and especially when it's associated with an indication of a heart surgery .

Ethical Approval:

As per international standard or university standard written ethical approval has been collected and preserved by the author(s).

Consent

As per international standard or university standard, patient(s) written consent has been collected and preserved by the author(s).

References :

- 1- Elena Emilia Babeş et al (2020): Multiple and giant coronary artery aneurysm – case report and a review of the literature : Rom J Morphol Embryol 2020, 61(2):551–554
- 2- Kawsara et al (2018): Management of Coronary Artery Aneurysms : JACC: CARDIOVASCULAR INTERVENTIONS VOL. 11, NO. 13, 2018^a 2018 BY THE AMERICAN COLLEGE OF CARDIOLOGY FOUNDATION PUBLISHED BY ELSEVIER
- 3- Z. Lahlafi et al (2021) : ST-ELEVATION MYOCARDIAL INFARCTION REVEALING A CORONARY ARTERY ECTASY : TWO (02) CASES REPORT : Int. J. Adv. Res. 9(09), 26-35
- 4- Nichols et al (2008) : Coronary Artery Aneurysm A Review and Hypothesis Regarding Etiology : Arch Pathol Lab Med—Vol 132, May 2008
- 5- (2020) Coronary Artery Ectasia with Acute Myocardial Infarction, A Case Report : J Saudi Heart Assoc. 2020; 32(2): 336–339
- 6- Devabhaktuni et al. (2016) : Coronary Artery Ectasia-A Review of Current Literature : Current Cardiology Reviews, 2016, 12, 318-323
- 7- V. Pham et al (2019) Giant coronary aneurysms, from diagnosis to treatment: A literature review : Arch Cardiovasc Dis (2019), <https://doi.org/10.1016/j.acvd.2019.10.008>
- 8- Mohammad Masoumi et al. (2013) : An Unusual Case of Mitral Stenosis with Coronary Artery and Left Ventricular Apical Aneurysm : J Teh Univ Heart Ctr 2014;9(1):43-45
- 9- Varuna Kurnauth et al (2019) : Giant right coronary artery aneurysm – A rare presentation : Journal of Medical Imaging and Radiation Oncology (2019) : doi:10.1111/1754-9485.12980

UNDER PEER REVIEW