

**DIAGNOSTIC PITFALLS OF SPIGELIAN HERNIA – CASE
REPORT**

ABSTRACT

Aims: Spigelian hernias are rare type of ventral hernias. They account for 0.1- 2% of all abdominal wall hernias. As they are interparietal, only 50% percentage of patients are diagnosed clinically.

Presentation of Case: 60-year-old woman presented with acute lower abdominal pain of two hours duration. For the last four years, she experienced similar episodes of pain around thirty minutes that subsided spontaneously on arrival to hospital each time. Though she was evaluated on multiple occasions, definitive cause could not be identified. There was a tender abdominal lump on palpation. On USS abdomen, an obstructed spigelian hernia was found. The patient was taken to operation theatre for emergency laparotomy. As her pain improved and hernia reduced spontaneously during the waiting time, surgery was postponed. In routine surgical list, her spigelian hernia was operated.

Discussion: Clinical diagnosis of spigelian hernia is challenging because it is usually small, presents with non- specific symptoms and difficult to palpate due to its interparietal location. Dynamic Ultrasonography and CT abdomen are useful in confirming the diagnosis. Surgical exploration remains the mainstay of treatment.

Conclusion: Clinical diagnosis of Spigelian hernia remains challenging due to its rare presentation. Clinicians should have a high index of suspicion for spigelian hernia in patients presenting with nonspecific abdominal pain without palpable mass. Early diagnosis and prompt management help to reduce acute life-threatening complications such as

incarceration and strangulation. Mode of surgical approach depends on the surgical expertise and availability of resources.

Key word: Spigelian hernia, surgical exploration, incarceration, Spigelian fascia

1. INTRODUCTION

Hernias appearing through the anterior abdominal wall are considered ventral hernias. Spigelian hernia is a rare form of ventral hernia (1) that accounts for 0.1- 2% of all abdominal wall hernias (2). Although the incidence of Spigelian hernia in men and women is nearly equal it is found frequently in women between their 4th and 7th decade of life (3).

Musculoaponeurotic junction of transversus abdominis muscle forms linea semilunaris that is an imaginary line between ninth intercostal cartilage and pubic tubercle. Lateral edge of the rectus sheath runs from the costal margin to pubis. Spigelian hernia occurs through the spigelian fascia that is lined medially by the lateral border of the rectus sheath and laterally by linea semilunaris. Spigelian hernia occurs through spigelian fascia/aponeurosis that is anatomically the medial part of the fused aponeurosis of transversus abdominis and internal oblique. The hernia can occur at any point through the spigelian fascia (2,4).

Spigelian fascia is overlapped by the fibres of internal and external oblique and transverse abdominis muscles. Hence, they are generally interparietal (5). For a spigelian hernia to get palpable, it has to penetrate transverse abdominis and internal oblique muscle and further glide in between the both oblique muscles. Only 50% of patients can be diagnosed preoperatively (6). Most Spigelian hernias are palpable below the umbilicus where the spigelian fascia is widest and therefore potentially weakest (7).

Spigelian hernias can be congenital or acquired. Their formation can be predisposed by obesity, chronic obstructive pulmonary disease, pregnancy, prior abdominal surgery, abdominal trauma and other causes of increased intrabdominal pressure (2). Though small

intestine is the major content of spigelian hernia most of the time, caecum, omentum, appendix and sigmoid colon can also be seen (7).

Spigelian hernias can be diagnosed by USS abdomen and CT abdomen (3). As it possesses a high risk for strangulation, surgical exploration is the definitive treatment option (8). Both conventional open approach and laparoscopic techniques are available.

3. PRESENTATION OF CASE

60-year-old woman admitted to emergency unit with the history of acute onset of right sided lower abdominal pain without nausea or vomiting of 2 hours duration. There was no radiation of pain. The patient suffered similar episodes of pain for less than 30 minutes for the past four years. Each episode of pain subsided before arrival to hospital. She was evaluated in various medical institutions. Her previous X-ray KUB(Kidney-Ureter-Bladder), ultra sound scan-abdomen and colonoscopy reports were normal.

On examination, there was a tender and firm abdominal wall lump in the right lower quadrant. Ultra sound scan of abdomen revealed an obstructed right sided spigelian hernia of 5x5 cm containing bowel loops and fat. An emergency laparotomy was planned. Prior to induction of anesthesia, general appearance of the patient improved, abdominal pain subsided and the hernial sac disappeared spontaneously. Therefore, she was prepared for a routine surgery.

During surgical exploration, an oblique skin incision was directly made over the hernial region. External oblique aponeurosis was divided along its direction. A 5x8cm hernial sac was visualized. Small bowel loops and omentum were found protruding through the aponeurotic defect. Weakened wall was repaired anatomically and polypropylene mesh repair was done. She had an uneventful postoperative recovery and got discharged home after three days of surgery.

4. DISCUSSION

Spigelian hernias are mostly small in size and their fascial defect is usually smaller than the sac. Therefore, it has a high chance of incarceration that warrants emergency laparotomy in patients up to 24% (8).

Spigelian hernia may mimic many intra-abdominal pathologies such as acute appendicitis, twisted ovarian cyst, tubo-ovarian pathologies, mesenteric lymphadenitis, biliary colic, mesenteric ischemia, pancreatitis etc (2). If a patient presented with abdominal pain and found to have a reducible lump, the diagnosis can be easily made. In subclinical cases, the clinician has to be aware of spigelian hernia as one of the causes and he should also be vigilant in excluding other serious intrabdominal pathologies.

In our case, the diagnosis of Spigelian hernia was challenging as the patient remained subclinical for four years. Even the patient experienced abdominal pain each time, it subsided before the clinical and USS examination as the hernia remained easily reducible. Fortunately, abdominal pain remained for a long time during the last presentation and it aided us in diagnosing Spigelian hernia. Therefore, we surgically repaired the hernia and prevented upcoming complications.

Ultrasound scan - abdomen is the investigation of choice and considered to be the first line imaging. It should be done in patients with severe abdominal pain and it can identify hernial defect, sac and its contents. USS can also provide real-time images that help in deciding the time and mode of surgery (2). CT abdomen will show the location and size of hernial sac and its contents and helps to rule out other abdominal pathologies. When these two investigations fail in arriving diagnosis, clinicians can proceed with diagnostic laparoscopy in symptomatic patients and can repair simultaneously when the findings are positive (9).

European Hernia Society (EHS) classification guides the clinicians in deciding the mode of surgery (8). It includes the anatomy of hernia and clinical features of the patient and according to them, the treatment options are stated.

Surgical exploration is the definitive treatment option for these patients as these hernias are more prone to incarceration and strangulation. Surgery lowers the risk of recurrence of Spigelian hernia. (8). Decision of open approach or laparoscopic approach depends on surgical expertise. Whether open or laparoscopy, it is advisable to repair the hernia with the use of mesh (9). Laparoscopic approach is desirable because it is a minimally invasive surgery with less morbidity and warrants a shorter hospital stay with an early return of normal activities (8). There are various approaches in laparoscopic surgery such as Intraperitoneal Onlay Mesh (IPOM) technique, Total extraperitoneal Patch (TEP) approach and Transabdominal Preperitoneal (TAP) approach (3).

4. CONCLUSION

Spigelian hernias are under- diagnosed because they are rare and often present with nonspecific symptoms. As they lie in the interparietal plane, it is difficult to palpate the hernia. Therefore, clinicians should consider Spigelian hernia as a differential diagnosis in a patient presenting with nonspecific abdominal pain. Dynamic ultrasonography and CT abdomen will assist in diagnosis. Early diagnosis and prompt surgical approach will drastically reduce catastrophic complications such as incarceration and strangulation of hernia and improve the quality of life of the patient by reducing the recurrence. Laparoscopic surgery has more advantages than open approach. Surgical expertise and availability of resources determine the mode of surgery.

8. CONSENT

Authors declare "written informed consent was obtained from the patient for publication of this case report and accompanying images. A copy of the written consent is available for review by the Editorial office/Chief Editor/Editorial Board members of this journal."

9. ETHICAL APPROVAL

This case report is exempt from ethical review.

10. REFERENCES

1. Houlihan, T. J. (1976). A review of spigelian hernias. *The American Journal of Surgery*, 131(6), 734–735.
2. Giri Goswami, A., Huda, F., Kumar Singh, S., Kumar, N., & Basu, S. (2022). Spigelian Hernia: Clinical Features and Management. *Hernia Surgery*.
3. Haji Rahman, R., Punjwani, A., Notario-Ringwald, J., Taneja, S., Fahim, S., Varghese, R., & Tiesenga, F. (2022). Non-strangulated Spigelian Hernia: A Case Report. *Cureus*.
4. Webber, V., Low, C., Skipworth, R. J. E., Kumar, S., de Beaux, A. C., & Tulloh, B. (2017). Contemporary thoughts on the management of Spigelian hernia. *Hernia*, 21(3), 355–361.
5. Bhatia, T., Ghimire, P., & Panhani, M. (1970). Spigelian hernia. *Kathmandu University Medical Journal*, 8(2), 241–243.
6. Slaiki, S., Hamdane, A., El Bouhaddouti, H., Ousadden, A., Taleb, K. A., & Benjelloun, E. B. (2020b). Spigelian hernia case report and review of literature. *International Surgery Journal*, 7(3), 880.
7. Foster, D., Nagarajan, S., & Panait, L. (2015b). Richter-type Spigelian hernia: A case report and review of the literature. *International Journal of Surgery Case Reports*, 6, 160–162.

8. Hanzalova, I., Schäfer, M., Demartines, N., & Clerc, D. (2021). Spigelian hernia: current approaches to surgical treatment—a review. *Hernia*.
9. Henriksen, N. A., Kaufmann, R., Simons, M. P., Berrevoet, F., East, B., Fischer, J., Hope, W., Klassen, D., Lorenz, R., Renard, Y., Garcia Urena, M. A., & Montgomery, A. (2020). EHS and AHS guidelines for treatment of primary ventral hernias in rare locations or special circumstances. *BJS Open*, 4(2), 342–353.

11. FIGURE

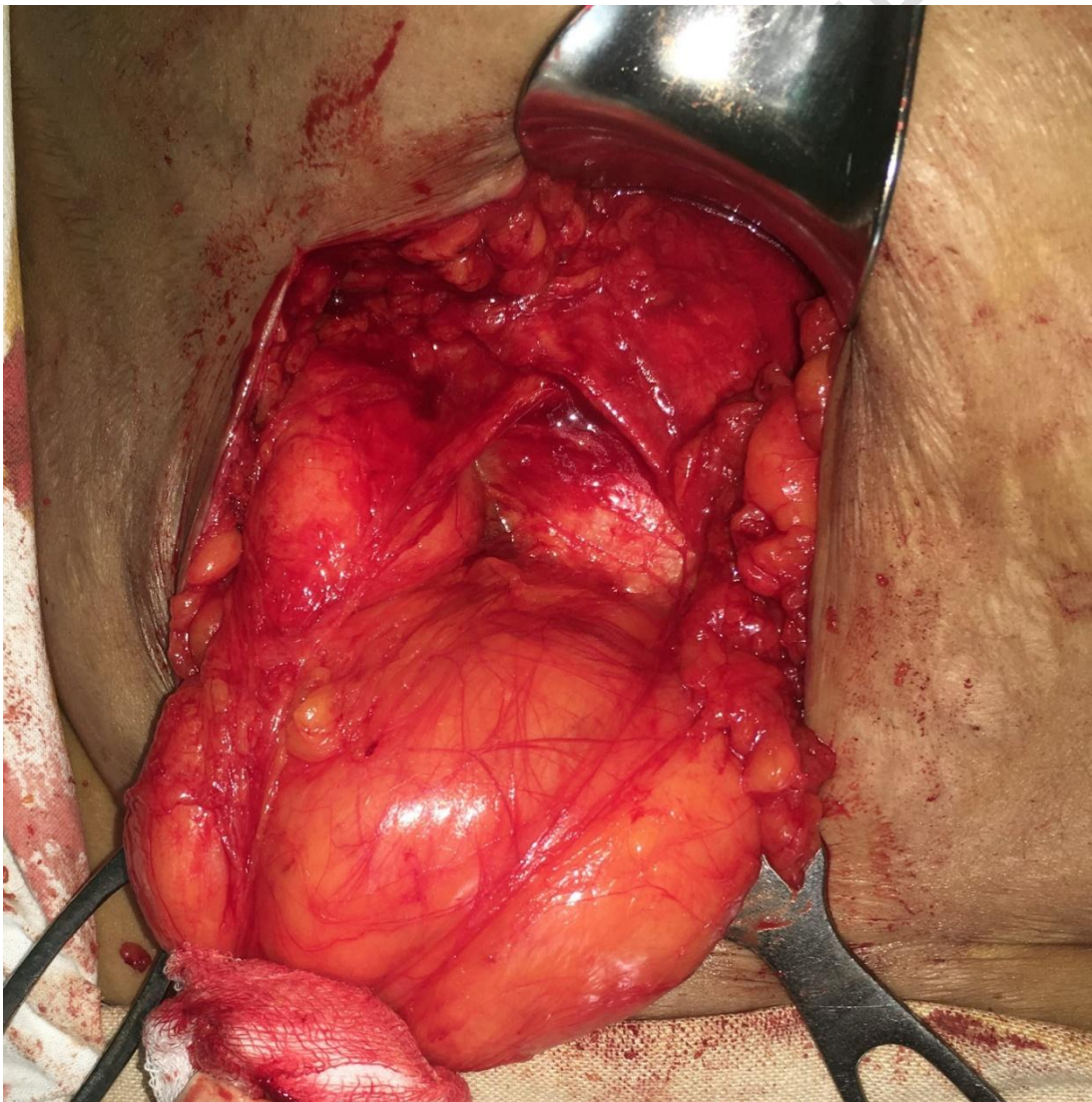


Fig 1: Intra operative image of hernial sac through spigelian belt region

UNDER PEER REVIEW