

Tuberculosis of the middle ear : case report

Abstract

Observation : Tuberculosis of the middle ear is rare. Its diagnosis is often late. We report the case of a 12-year-old child with chronic left otitis resistant to conventional medical treatment, evolving since the age of 5 years, complicated by cophosis and left facial paralysis. Computed tomography imaging of the rocks showed extensive lesions associating middle ear involvement, mastoiditis and sphenoid osteolysis. The diagnosis was oriented by the geographical origin, the notion of tuberculous contagion, the chronic otorrhoea resistant to conventional medical treatment, the facial paralysis occurring in a context of chronic otitis, the histological aspect +/- of the granulomatous tissue sampled in per operation and good post-operative evolution under anti-tuberculosis treatment.

Conclusion : Tuberculosis of the middle ear should be considered in the face of chronic otitis and risk factors for tuberculosis. The search for dissemination must be systematic and treatment early in order to avoid auditory sequelae.

Keywords : tuberculosis, chronic otitis, facial paralysis

1. Introduction

Tuberculosis of the middle ear is a rare condition with difficult and often late diagnosis due to the banality of the symptoms and the usual negative samples, which is often responsible for a delay in diagnosis. Extra-pulmonary localizations represent nearly half of the cases of patients notified (48%) here in

Morocco (1) and auricular localization remains a very rare entity in the forms of extra-pulmonary tuberculosis.

The aim of this work is to draw the attention of our colleagues in otorhinolaryngology, ENT and general practitioners to chronic tuberculous otitis media.

2. Case Presentation

A 12-year-old boy was hospitalized in the service for the etiological investigation of left otorrhea. He is the first child of the siblings born in Morocco to parents from Beni Mellal with a history of tuberculosis contagion, vaccinations were up to date and the child received their TB vaccine

Since the age of 5 years, the child presented with a nauseating and febrile chronic left otorrhea evolving intermittently with episodes of remission resistant to medical treatment, accompanied by progressive hypoacusis, tinnitus and night sweats. This clinical picture was complicated 3 weeks before the day of his hospitalization with grade 4 left facial paralysis

without other associated signs, in particular no neurological signs.

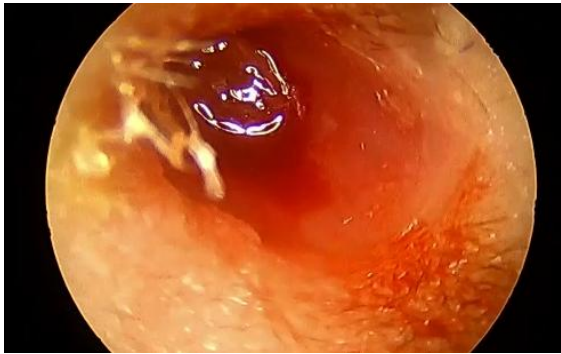

Figure 1 otoscopy : inflammatory polyp completely filling the EAC

The ENT examination found a large inflammatory polyp completely filling the left EAC (figure: 1). The rest of the somatic examination was normal, in particular pulmonary lymph nodes and neurology. The audiogram revealed a cochlosis on the left the CT scan of the rocks (figure: 2) found mucous thickening of the walls of the EAC, filling of the eardrum, bone lysis of the inner wall of the middle ear with a bare appearance of the facial nerve in its tympanic portion, partial lysis of the malleus and incus, filling of the round and oval windows, lysis of the tympani tegmen, a blunt appearance of the wall of the cubicle with filling of the mastoid cells.

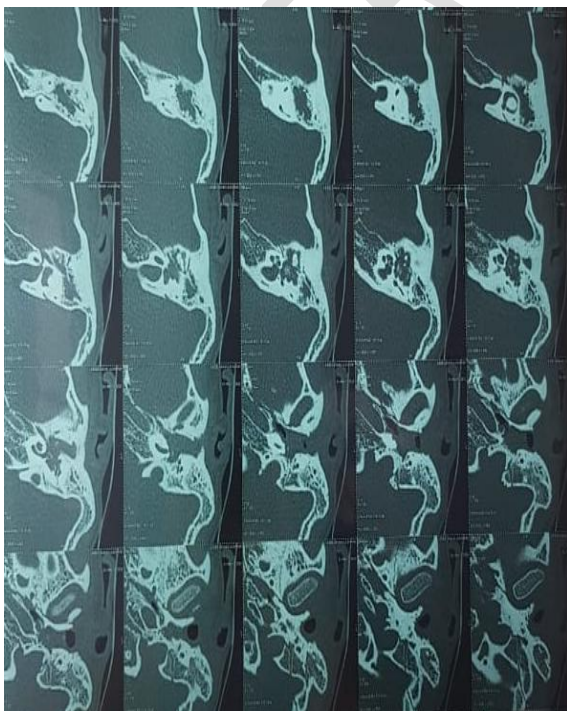

Figure 2: CT of the left petrous bone showing filling of the tympanic cavity, partial lysis of the malleus and incus, bare appearance of the facial nerve in its tympanic portion, lysis of the tympani and antrii tegmen with blunt appearance of the wall of the cell filling of mastoid cells.

The biological assessment showed a moderate inflammatory syndrome.

A biopsy of the polyp then a mastoidectomy with antrotomy were performed. On exploration, the presence of inflammatory granulomatous tissue invading F2 (Figure: 3), the vestibule and the cochlea. Another biopsy was taken for pathological study. An ossified CSL, a chain present but lysed. total excision of the granulomatous tissue of the incus and the stirrup with decompression of the F2 + geniculate and F1 were carried out.

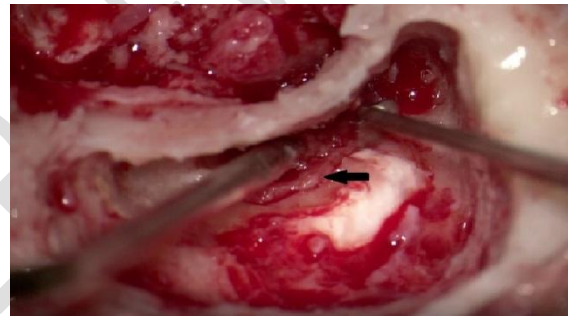


Figure 3: mastoidectomy with exploration of an inflammatory granulomatous mucosa with invaded facial nerve (black arrow)

Histology (figure: 4) showed an inflammatory squamous mucosa with the presence of epithelioid granulomas without multinucleated giant cells and without caseous necrosis

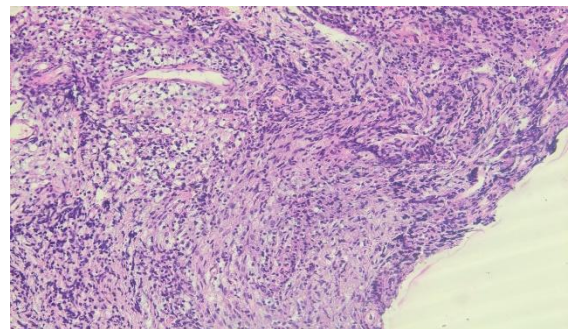


Figure 4: epithelioid granuloma without multinucleated giant cells without caseous necrosis

Quadruple antituberculosis therapy with rifampicin, isoniazid, ethambutol and pyrazinamide was undertaken in combination with local antibiotic treatment for 1 month.

3. Discussion

In Morocco, 26,000 to 27,000 new cases of all forms of tuberculosis have been detected annually for several years. The cumulative incidence of all forms of tuberculosis was always above 100 cases per 100,000 inhabitants. It was not until 2000 that this incidence fell below 100 cases per 100,000 inhabitants. The highest cumulative incidence was recorded in the regions of Greater Casablanca (127) new cases per 100,000 inhabitants, Tangier Tetouan (120), Rabat-Salé-Azemmour-Zaër (111) and Fès-Boulemane (105.) [1, 2]

In 2012, a total of 27,437 new cases of all forms of tuberculosis were notified in Morocco, representing an incidence of 83 new cases per 100,000 inhabitants and 35 new cases of TPM+ per 100,000 inhabitants. The most common form is extra pulmonary tuberculosis with 13,122 cases (47.8%) against 11,572 cases (42.2%) of TPM+, 2,343 (8.5%) TPM – and 400 cases (1.5%) of PIT [3].

Tuberculosis primarily affects the lungs, extra-pulmonary forms represent 15 to 30% of cases and can affect all organs. The relative frequencies of the various visceral attacks of tuberculosis vary according to the terrain and the geography. Lymph node involvement, the most common extra-pulmonary localization (30%), currently affects young adults (20 to 40 years old) in Western countries and children in developing countries. Then come, in order of frequency, pleural damage (20%), genitourinary (16%), osteo-articular (10 to 15%), miliary (10%), neurological damage (about 8%), abdominal (about 6%) and finally, other less frequent disorders (cutaneous, ocular, endocrine, cardiac and ENT) [4]. These data relate to an adult population,

The evolution was marked by a rapid improvement in his general condition, the disappearance of fever and otorrhoea and even an improvement in his facial paralysis (grade 3 after 2 months of treatment).

In general, ENT localization primarily concerns the middle ear. In our observation, the time to diagnosis was 3 months. Vaamonde et al. report a series of ten cases (including two children aged four and 17) over a period of seven years with a delay before diagnosis ranging from two to 72 months [5]. The classic triad of painless otorrhea, facial nerve paralysis and multiple tympanic perforations is rarely seen. Currently, the most common reason for consultation in children is otorrhea refractory to conventional antibiotic therapy. This is exceptionally bilateral; it may be associated with facial paralysis or hearing loss [6.7.8]. In our observation, the clinical signs are the same as already described, refractory left otorrhoea, left facial paralysis and left hearing loss progressing to cophosis. associated pulmonary involvement may facilitate the diagnosis. In their series, two of the ten patients had pulmonary lesions suggestive of tuberculosis compared to 50 to 60% in the literature [9]. In our observation, there was no pulmonary tuberculosis; extra-pulmonary involvement is more frequent in African and Asian populations [10]. Dissemination from the airways to the Eustachian tube is very likely, as suggested by Srirompotong et al. [11]. TOM can also be the consequence of dissemination via the lymphatic route from the cervicothoracic lymph node involvement and, exceptionally, via the hematogenous route. From the middle ear, tuberculous lesions can extend to the mastoid, the temporal bone [12], the central nervous system [13] or even the occipital condyle and the atlas, leading to instability of the craniovertebral junction. High-resolution computed tomography is the reference examination to assess extension to the mastoid cells and the temporal bone and to check the integrity of the ossicular chain, the

facial nerve canal and the labyrinth [14]. Computed tomography can miss a bone sequestration which must be evoked in case of failure of medical treatment. Its frequency would be 30% and its diagnosis often intraoperative [15]. Bacteriological or anatomopathological examinations of biopsy or surgical specimen confirm the diagnosis of TOM, with a sensitivity of 70 to 90% [16]. The histology of the polyp did not find any caseous necrosis and, as in 2/3 of the cases, the diagnosis was therefore established on a range of arguments (geographical origin, notion of tuberculosis contagion, the clinical picture associating fever night sweats chronic intractable otorrhea complicated by PF and cophosis and finally on the histological examination) then on the results of a therapeutic trial. The evolution of tuberculosis of the middle ear under treatment is favorable, but deafness Residuals are common [17,18]. They are explained by the delay in diagnosis because the quality of the recovery depends on the precocity of the treatment. The culture of otorrhea is generally unprofitable (30%). Microbiological diagnosis is also difficult on samples taken during ENT surgery (bone biopsy) [19]. In some cases, the diagnosis of TOM may be based solely on the efficacy of a trial anti-tuberculosis treatment [19]. Antituberculous drugs represent the treatment of TOM. The duration of treatment is usually extended beyond the six months recommended in pulmonary tuberculosis, up to nine months, or even longer depending on the evolution. A surgical procedure may be necessary for diagnostic purposes or in the event of complications. It can be a tympanoplasty, drainage of subperiosteal abscess, excision of bone sequestrum or decompression of the facial nerve [5,15]. In our observation, the treatment was surgical and medical, allowing a priori to control the disease.

Tuberculosis of the middle ear is rare, its diagnosis difficult and often late. It should be considered in the presence of any otitis

resistant to the usual treatment and particularly in populations at risk. Early diagnosis allows optimal care, that is to say anti-tuberculosis treatment. Complications and sequelae are linked to locoregional extension, delay in diagnosis, and the limits of medical treatment, particularly in the event of bone sequestration, which may then justify a surgical procedure which must be considered in the event of failure of medical treatment. . Its frequency would be 30% and its diagnosis often intraoperative [15]. Bacteriological or anatomopathological examinations of biopsy or surgical specimen confirm the diagnosis of TOM, with a sensitivity of 70 to 90% [16]. The culture of otorrhea is generally unprofitable (30%). Microbiological diagnosis is also difficult on samples taken during ENT surgery (bone biopsy) [19]. The diagnosis can also go through the puncture-biopsy of cervical lymphadenopathy, a simple and profitable gesture (diagnosis in 80% of cases). In some cases, the diagnosis of TOM may be based solely on the efficacy of a trial anti-tuberculosis treatment [19]. The duration of treatment is usually extended beyond the six months recommended in pulmonary tuberculosis, up to nine months, or even longer depending on the evolution. A surgical procedure may be necessary for diagnostic purposes or in the event of complications. Microbiological diagnosis is also difficult on samples taken during ENT surgery (bone biopsy) [19]. The diagnosis can also go through the puncture-biopsy of cervical lymphadenopathy, a simple and profitable gesture (diagnosis in 80% of cases). In some cases, the diagnosis of TOM may be based solely on the efficacy of a trial anti-tuberculosis treatment [19]. The duration of treatment is usually extended beyond the six months recommended in pulmonary tuberculosis, up to nine months, or even longer depending on the evolution. A surgical procedure may be necessary for diagnostic purposes or in the event of complications. Microbiological diagnosis is also difficult on samples taken during ENT surgery (bone

biopsy) [19]. The diagnosis can also go through the puncture-biopsy of cervical lymphadenopathy, a simple and profitable gesture (diagnosis in 80% of cases). In some cases, the diagnosis of TOM may be based solely on the efficacy of a trial anti-tuberculosis treatment [19]. The duration of treatment is usually extended beyond the six months recommended in pulmonary tuberculosis, up to nine months, or even longer depending on the evolution. A surgical procedure may be necessary for diagnostic purposes or in the event of complications. simple and profitable procedure (diagnosis in 80% of cases). In some cases, the diagnosis of TOM may be based solely on the efficacy of a trial anti-tuberculosis treatment [19]. The duration of treatment is usually extended beyond the six months recommended in pulmonary tuberculosis, up to nine months, or even longer depending on the evolution. A surgical procedure may be necessary for diagnostic purposes or in the event of complications. simple and profitable procedure (diagnosis in 80% of cases). In some cases, the diagnosis of TOM may be based solely on the efficacy of a trial anti-tuberculosis treatment [19]. The duration of treatment is usually extended beyond the six months recommended in pulmonary tuberculosis, up to nine months, or even longer depending on the evolution. A surgical procedure may be necessary for diagnostic purposes or in the event of complications.

References

- [1] Guide to the fight against tuberculosis. Department of Epidemiology and Disease Control, Ministry of Health KINGDOM OF MOROCCO: Edition April 2011.
- [2] World Health Organization. WHO endorses new rapid tuberculosis test: a major milestone for global tuberculosis diagnosis and care, www.who.int/mediacentre/news/releases/2010/tb_test_20101208/en/ind
- [3] [RESPIRATORY DISEASES DEPARTMENT/DELM] March 01, 2013.
- [4] Y.Aydi, Extra-pulmonary tuberculosis, Rev Med and Mal Infect 2016;46:80.
- [5] Vaamonde P, Castro C, Garcia-Soto N, Labella T, Lozano A. Tuberculous otitis media: a significant diagnostic challenge. Otolaryngol Head Neck Surg 2004;130:759–66
- [6] See H, Aubertin G, Angoulvant F, Baculard F, Soussan V, et al. Chronic otorrhoea and hypoacusis revealing disseminated tuberculosis in children: apropos of a case. Arch Pediatr 2006;13:1233–5
- [7] Duclos JY, Darrouzet V, Ballester M, Bébéar JP, Bébéar CM. Tuberculosis of the middle ear. Encycl Med Chir (Elsevier, Paris). Otorhinolaryngology 1999; 20-235-A-10:4p
- [8] Vital V, Printza A, Zaraboukas T. Tuberculous otitis media: a difficult diagnosis and report of four cases. Pathol Res Practice 2002;198:31–5
- [9] Sierra C, Fortun J, Barros C, Melcon E, Condes E, et al. Extralaryngeal head and neck tuberculosis. Clin Microbiol Infect 2000;6:644–8
- [10] Forssbohm M, Zwahlen M, Loddenkemper R, Rieder HL. Demographic characteristics of patients with extrapulmonary tuberculosis in Germany. Eur Respir J 2008;31:99–105.
- [11] Srirompotong S, Yimtae K, Jintakanon D. Nasopharyngeal tuberculosis: manifestations bet
- [12] Nicolau Y, Northrop C, Eavey R. Tuberculous otitis in infants: temporal bone histopathology and clinical extrapolation. Otol Neurotol 2006;27:667–71.
- [13] Mongkolrattanothai K, Oram R, Redleaf M, Bova J, Englund JA. Tuberculous otitis media with mastoiditis and central nervous system involvement. Pediatr Infect Dis J 2003;22:453–6.
- [14] Rho MH, Kim DW, Kim SS, Sung YS, et al. Tuberculous otomastoiditis on high-resolution temporal bone CT: comparison with nontuberculous otomastoiditis with
- [15] Saunders NC, Albert DM. Tuberculous mastoiditis: when is surgery indicated? Int J Pediatr Otorhinolaryngol 2002;65:59–63.
- [16] Nalini B, Vinayak S. Tuberculosis in ear, nose, and throat practice: its presentation and diagnosis. Am J Otolaryngol 2006;27:39–45.
- [17] Duclos JY, Darrouzet V, Ballester M, Bébéar JP, Bébéar CM. Tuberculosis of the middle ear. Encycl Med Chir (Elsevier, Paris). Otorhinolaryngology 1999; 20-235-A-10:4p
- [18] Vaamonde P, Castro C, Garcia-Soto N, et al. Tuberculous otitis media: a significant diagnostic challenge. Otolaryngol Head Neck Surg 2004;130:759–66.
- [19] Bouayed S, Kos MI, Guyot JP. Tuberculosis of the ear: apropos of two cases. Rev Med Suisse Romande 2005;1:2396, 2399-400, 2402-3.