

# Positional vertigo and arachnoid cyst of the Ponto-cerebellar Angle: a case report

## Abstract :

Arachnoid cysts represent 1% of all intracranial lesions [1]. They can be localized at the level of the posterior fossa. These cysts are usually asymptomatic. But they can sometimes be responsible for a variety of nonspecific symptoms such as headache and dizziness [2]. We present here a clinical case of an arachnoid cyst of the ponto-cerebellar angle causing positional vertigo.

Keywords : Arachnoid cysts, vertigo, cranial fossa, cerebrospinal fluid

## Introduction :

“Arachnoid cysts are benign developmental collections of cerebrospinal fluid (CSF) contained within the arachnoid membrane. Middle cranial fossa is the most common site of occurrence, followed by the cerebellopontine angle (CPA) and suprasellar area” [10]. “The arachnoid cysts of CPA usually remain asymptomatic so they are often diagnosed incidentally during radiological evaluation for other reason. Arachnoid cysts, which contain cerebrospinal fluid (CSF), are benign cystic lesions that develop in the intra-arachnoid space. Although the pathogenesis of those cysts is unknown, they are thought to be congenital; 60% to 90% of the reported patients with an arachnoid cyst are children” [11].

## Presentation of the case

**Interrogation:** Male, 28 years old, with no particular pathological history. History of the disease dates back 3 months with the appearance of a rotatory vertigo attack at the change of position, lasts a few minutes. Without notable otological or neurological signs.

**Physical examination :** Dix and Hallpike, head right: Counterclockwise upbeat and torsional geotropic paroxysmal nystagmus Normal otoneurological examination  
The diagnosis of a benign right posterior paroxysmal positional vertigo was retained.  
Resolution of vertigo after three daily cycles of Epley’s liberating maneuver of liberating maneuvers.

3 weeks later, the patient presents a second attack of rotational vertigo triggered by the movements of rotation to **the right, flexion and extension** of the head. Pitching sensation. Nausea, No vomiting. No headache or neurological signs. Normal hearing. Sometimes bilateral tinnitus.

**Physical examination :** No spontaneous nystagmus. Normal eye movement. Normal gait. No segmental or axial deviation. No cerebellar signse.  
Right hemiface spasms

Dix and Hallpike, head right: longlasting torsional geotropic anti-clockwise nystagmus. No latency. Inhibited by eyes fixation No reversal of the nystagmus when returning to a sitting position. Head left: Lower downbeat nystagmus that lasts over time

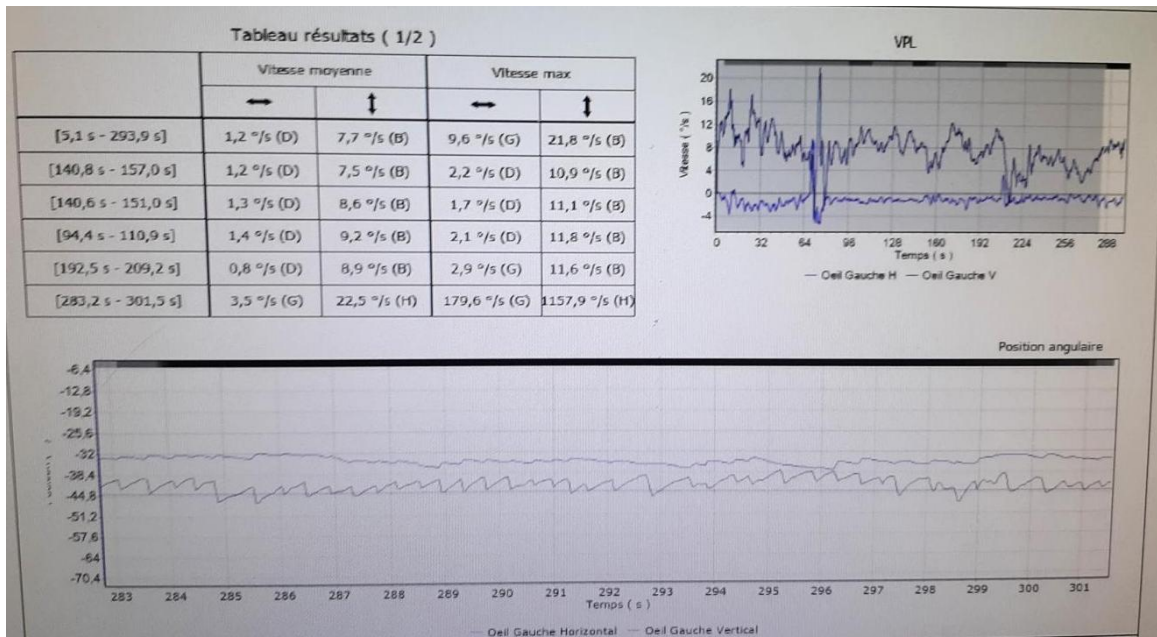


Figure 1 : recording of nystagmus during the Dix and Hallpike maneuvers

VHIT: gain greater than 0.7 for the 6 right and left semicircular canals

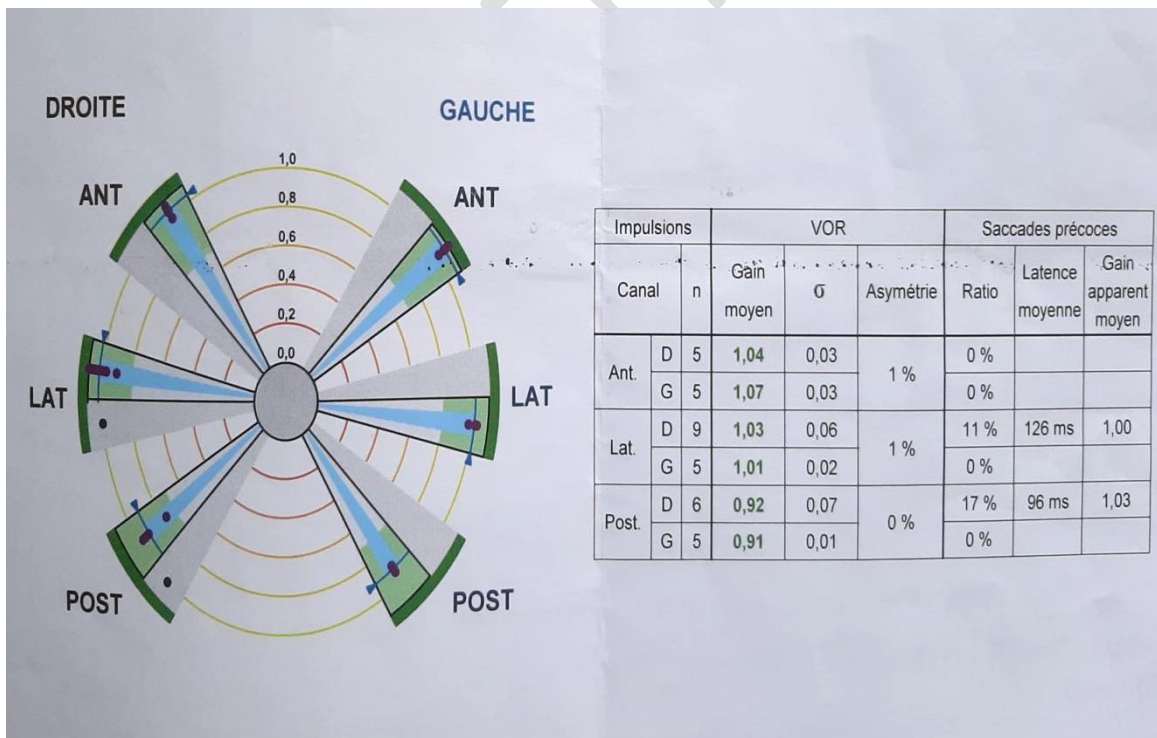


Figure 2: Results of the VHIT of our case

### Oculomotricity:

Saccade test: No delay in the chase. Average speeds: 482 ° / s Right, 502 ° / s Left  
 Sinusoidal slow tracking: Gain on the right: 0.92 / Gain on the left: 0.89

**Caloric tests:**

Slow phase velocity Reflectivity 56.7 %/ s  
 Slight left vestibular deficit at 4% not significant

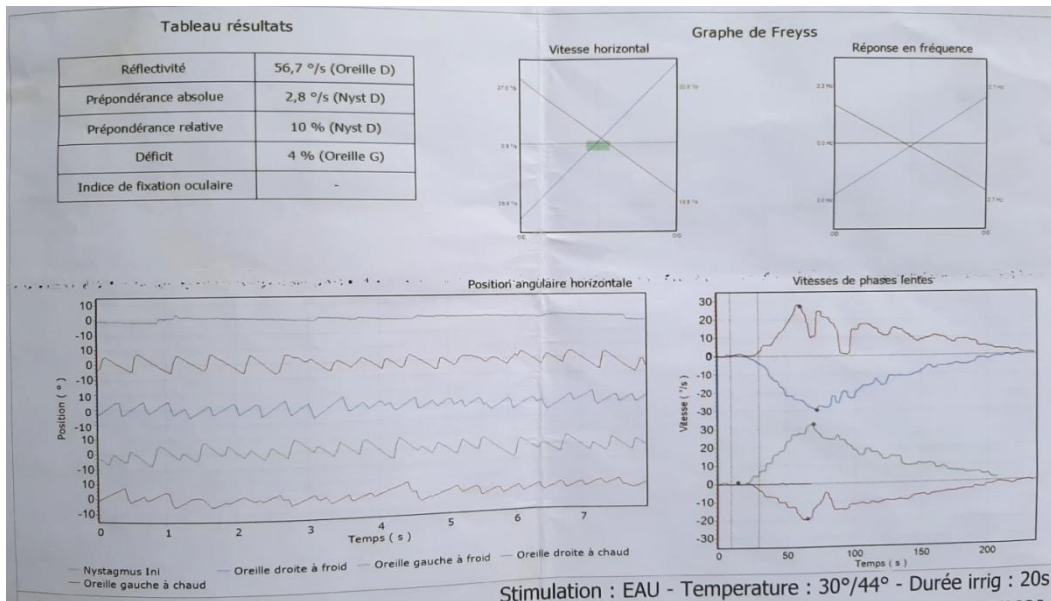


Figure 3: caloric test results in our case

**MRI of the Ponto-Cerebellar Angle:** Well limited oval formation, hypo T1, hyper T2, not enhanced after injection. Without diffusion restriction, measuring 24 x 11 mm. In contact with the Flocculus and the right lateral face of the protuberance and the elongated marrow, the lower face of the cisternal portion of the acoustic-facial bundle evoking an arachnoid cyst of the right PCA

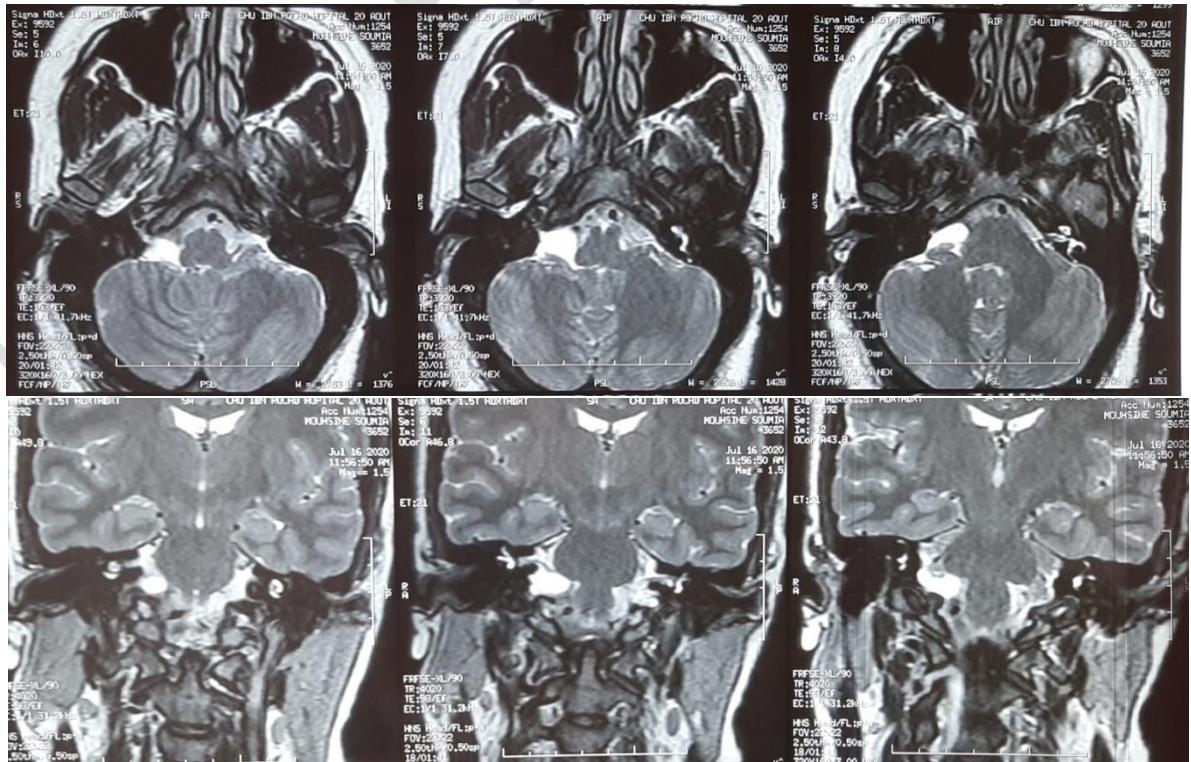


Figure 4: axial and coronal MRI slices of the ponto-cerebellar angle T2 sequence of our case

## Discussion

Arachnoid cysts are usually located in the middle cerebral fossa (50 to 60%), the ponto-cerebellar angle (10%) and the suprasellar region (10%). Its localization in the internal auditory canal is rare: 10%. Indeed, their great majority are asymptomatic and of accidental discovery. In 75% of cases, these cysts are discovered in the pediatric population in the event of a small cyst, located in the center of the internal auditory canal. May cause specific audio-vestibular and / or facial signs depending on the compressed nerve (1)

“Stretching or compressing different nerves can lead to dizziness, tinnitus and sensorineural hearing loss or produce hemifacial spasm or trigeminal neuralgia” (2).

“A larger cyst can push back the cerebellum, causing intentional tremor and ataxic walking. Further expansion through the cyst can obstruct the aqueduct or the fourth ventricle producing hydrocephalus” (2).

CISS 3D Magnetic Resonance Imaging is able to detect the arachnoid cyst wall and neighboring anatomical structures. It is very useful for the preoperative evaluation in endoscopic surgery given the restricted visual field (3).

A meta-analysis of 46 articles showed that arachnoid cysts caused nerve compression syndromes more frequently than nerve displacement.

The cochlear and vestibular nerves were the structures most frequently involved in compression syndromes, while the facial nerve was generally displaced (4).

“In addition, the growth of the arachnoid cyst, whether fast or slow, could damage the cochlear nerve causing a severe to profound form of sensorineural Deafness” (4).

Ungar et al. (5) studied 27 Arachnoid Cysts. Average age was 80 years (47–96 years). On a histological study of the temporal bones, 27 arachnoid cysts were identified in 22 patients. The results were correlated with the pre-mortem clinical data. 18 Arachnoid cysts were symptomatic. The most common presentation was sensorineural hypacusia (94%), followed by tinnitus (22%). Vertigo was present in only 3 cases. The most frequent localization of Arachnoid Cysts was at the bottom (16 cases), followed by the middle part of the internal auditory canal (6 cases), and Arachnoid cysts extending from the porus to the bottom of the IAC (2 KA). The most affected structure was the cochlear nerve (16 cases, 59%) followed by the vestibular nerve (11 cases, 41%). The facial nerve was involved in two cases (7%). The Arachnoid Cyst dissected the cochlear and vestibular nerve fibers (intranearal dissection) in five and three cases, respectively. The relatively low incidence of vertigo (3/18 symptomatic) compared to cochlear symptoms is probably the result of a slow expansion of the Arachnoid Cyst, making central vestibular compensation possible, as the cochlear and vestibular divisions of the VIII have been affected in 59% of cases and 41%, respectively. No correlation between KA volume and clinical symptoms. No association between the location of KA along the CAI and clinical presentation. The relatively low incidence of vertigo (3/18 symptomatic) compared to cochlear symptoms is probably the result of a slow expansion of the Arachnoid Cyst, making central vestibular compensation possible, since the cochlear and vestibular divisions of the VIII have been affected in 59% of cases and 41%, respectively. No correlation between KA volume and clinical symptoms. No association between the location of KA along the CAI and clinical presentation. The relatively low incidence of vertigo (3/18 symptomatic) compared to cochlear symptoms is probably the result of a

slow expansion of the Arachnoid Cyst, making central vestibular compensation possible, since the cochlear and vestibular divisions of the VIII have been affected in 59% of cases and 41%, respectively. No correlation between KA volume and clinical symptoms. No association between the location of KA along the CAI and clinical presentation. No correlation between KA volume and clinical symptoms. No association between the location of KA along the CAI and clinical presentation. No correlation between KA volume and clinical symptoms. No association between the location of KA along the CAI and clinical presentation.

Li et al. (6) studied 6978 patients undergoing MRI of PCA for unilateral cochleo-vestibular symptoms. 37 patients with Arachnoid Cyst, including 16 with Arachnoid Cyst of the Ponto-Cerebellar Angle or Cerebral Trunk. In only 9 patients (25%), the symptoms could potentially be related to the localization of the cyst (Arachnoid cyst in the Ponto-Cerebellar Angle in patients with ipsilateral cochleo-vestibular symptoms or dizziness). No statistically significant association ( $p > 0.05$ ). No association between symptom laterality and AK laterality. Most, if not all, arachnoid cysts have no clinical significance. Arachnoid Cysts should be viewed as a chance discovery rather than a pathological causative entity. Given their indolent behavior, even serial imaging is not essential.

The management of Arachnoid Cysts of the Ponto-Cerebellar Angle remains controversial. Asymptomatic Arachnoid Cysts do not require treatment and these patients should be monitored clinically and radiologically by MRI. Symptomatic PCA arachnoid cysts with elevated intracranial pressure should be treated by shunting or fenestration of the CSF (7). Compression of a cranial nerve can lead to segmental demyelination which can lead to reversible loss of function. However, prolonged compression can lead to the death of Schwann cells, leading to irreversible loss of cranial nerve function (8).

Various surgical procedures including total resection and drainage, cystoperitoneal shunt, and marsupialization can be used.

Stereotaxic puncture and endoscopic fenestration have also been used successfully in the treatment of arachnoid cyst (2).

“With a high probability of clinical improvement and low rates of complications, minimally invasive endoscopic surgery is becoming the treatment of choice for symptomatic or growing arachnoid cysts” (3).

“Surgical treatment frequently improves vestibular symptoms, but hearing deficits are less likely to respond to surgery” (2).

Gangemi, M et al. (9) advise starting with a bit hole approach and attempting to fenestrate through the endoscope only. If the stoma cannot be made in this way, the bur hole is enlarged and an endoscope-assisted microsurgical technique is used.

The endoscope is particularly useful when the fenestration site is located deep, in the anterior wall of the cyst towards the pre-pontic or ambient cisterns. In these cases, the endoscope provides more illumination and helps prevent damage to the cranial nerves and cisternal vessels (9).

## Conclusion

The arachnoid cyst of the APC in adults is a rarely reported pathology. With atypical symptoms noted when questioning the patient or during physical examination, a central nervous system etiology should be mentioned and explored with cerebral MRI. Surgical abstention may be proposed, under long-term surveillance. Surgery is not easy, can be dangerous, and must be well thought out.

## Ethical Approval:

As per international standard or university standard written ethical approval has been collected and preserved by the author(s).

## Consent

As per international standard or university standard, patient(s) written consent has been collected and preserved by the author(s).

## References

- 1- Di Stadio A, Della Volpe A, Ralli M, et al. A minimally invasive endoscope assisted retrosigmoid approach for removal of arachnoid cysts in the internal auditory canal: a step by step description [published online ahead of print, 2019 Aug 6]. *Braz J Otorhinolaryngol.* 2019; S1808-8694 (19) 30085-0. doi: 10.1016 / j.bjorl.2019.06.016
- 2- Anand Sharma, Achal Sharma, Radhey S. Mittal & Ashok Gandhi (2015) Bilateral cerebellopontine arachnoid cyst: A rare entity, *British Journal of Neurosurgery*, 29: 4,576-578, DOI: 10.3109 / 02688697.2015.1015100
- 3- Liang, C., Zhang, B., Wu, L., Du, Y., Wang, X., Liu, C., & Yu, F. (2010). The superiority of 3D-CISS sequence in displaying the cisternal segment of facial, vestibulocochlear nerves and their abnormal changes. *European Journal of Radiology*, 74 (3), 437–440. doi: 10.1016 / j.ejrad.2009.03.049
- 4- Di Stadio A. Arachnoid cyst of internal auditory canal: how the temporal bone findings explain ear symptoms and suggest the best treatment to do. *Otolaryngol Open J.* 2016; 2: 125 --- 31.
- 5- Ungar OJ, Franck M, Nadol JB, Santos F. Arachnoid cysts of the internal auditory channel: An underappreciated entity ?. *Laryngoscope.* 2019; 129 (7): 1667-1674. doi: 10.1002 / lary.27601
- 6- Li L, Begbie F, Grimmond N, Kontorinis G. Arachnoid cysts on magnetic resonance imaging: just an incidental finding ?. *J Laryngol Otol.* 2020; 134 (5): 424-430. doi: 10.1017 / S0022215120000808
- 7- Zada G, Krieger MD, McNatt SA, Bowen I, McComb JG. Pathogenesis 2. and treatment of intracranial arachnoid cysts in pediatric patients younger than 2 years of age. *Neurosurg Focus* 2007; 22: E1.
- 8- Apin I, Gravel J (2003) B Auditory neuropathy: physiologic and pathologic evidence calls for more diagnostic specificity. *Int J Pediatr Otorhinolaryngol* 67 (7): 707–728
- 9- Gangemi, M., Maiuri, F., Colella, G., & Sardo, L. (2001). Endoscopic Surgery for Large Posterior Fossa Arachnoid Cysts. *Min - Minimally Invasive Neurosurgery*, 44 (1), 21–24. doi: 10.1055 / s-2001-13588
- 10- Gurkas E, Altan BY, Gücüyener K, Kolsal E. Cerebellopontine angle arachnoid cyst associated with mirror movements. *Journal of Pediatric Neurosciences.* 2015 Oct;10(4):371.

11. Yerli H, Kansu L, Cabbarpur C, Aydin E. Arachnoid Cyst of the Cerebellopontine Angle: A Case Report. Journal of International Advanced Otology. 2009 May 1;5(2).

UNDER PEER REVIEW