

## Case study

Midgut Volvulus with Intestinal Malrotation in an Aadult: Aa- Cease Rreport

### ABSTRACTbstract

BackgroundIntroduction: Intestinal malrotation is ~~an uncommon rare~~ congenital disorder characterized ~~by the lack of non-rotation or~~ partial rotation of the small bowel around the superior mesenteric arteries during the embryonic stage, ~~with resulting in~~ mid-gut volvulus ~~occurring as a consequence~~. Approximately 64-90% of patients' symptoms manifest as acute intestinal obstruction due to midgut volvulus before the age of one year, but the presentation in adulthood is extremely rare. 0.2-0.5%.

Case report: A 26-year-old woman ~~approached~~came to us ~~with complaints~~complaining of intermittent colicky discomfort, vomiting, and constipation for the previous three months.

All of the patient's vital ~~signs~~ and blood parameters were normal. ~~The~~Abdominal CECT ~~abdomen~~ revealed a reversal of the relationship between ~~the~~ superior mesenteric vessels, a ~~whirlingswirl~~ appearance of the mesentery, and ~~a~~ twisting of the mesentery vessels (~~w~~Whirlpool sign), indicating mid-gut volvulus and intestinal malrotation. Emergency surgical intervention~~The patient~~ was scheduled for ~~emergency surgery~~ the patient.

Conclusion: Although malrotation is frequent in childhood, symptomatic midgut malrotation can ~~appear~~occur in adults with non-specific symptoms. ~~When~~Diagnosis imaging and a high suspicion level are critical in diagnosing ~~trying to figure out the diagnosis, imaging and a high level of suspicion is very important.~~

Keywords: ~~mid-gut~~Adult intestinal malrotation, bowel, midgut volvulus, ~~adult intestinal malrotation, malrotation,~~ whirlpool sign.

### Background

Intestinal malrotation is a rare congenital condition defined by a partial or complete failure of the small bowel's 270-degree counterclockwise rotation around the superior mesenteric arteries during embryonic development, resulting in midgut volvulus. The symptoms of 64-

**Comment [1]:** 1. Correct language-related aspects

**Formatted:** Font: Bold, English (United States)

**Formatted:** English (United States)

**Formatted:** English (United States)

**Comment [2]:** In the English language, the correct way to enter intervals of numerical values is to use an en-dash and not a hyphen.

**Comment [3]:** In the English language, the correct way to enter intervals of numerical values is to use an en-dash and not a hyphen.

**Comment [4]:** Abbreviations should not be used unless they are standardized.

**Formatted:** Font: Bold, Italic, English (United States)

**Comment [5]:** There is a lot of information available on this subject, and I believe that the background information provided in this manuscript is too brief, and I would ask the authors to reconsider further elaborating and providing more background information.

90% of patients begin before the age of one year as acute intestinal obstruction due to midgut volvulus, although they are only present in 0.2–0.5% of adults.<sup>[1–3]</sup> Malrotation causes clinical symptoms in 1 in 5000 to 6000 live births, with 90% of cases manifesting during childhood. According to recent studies, approximately 70% of children emerge by the age of one; other studies show that 75% of patients appear by the age of five.<sup>[4,5]</sup> Adults may experience a delayed diagnosis as a result of a lower degree of suspicion, which may increase morbidity and mortality. Adults require a high level of suspicion to be diagnosed with the condition. We present the case of a 26-year-old lady who underwent a laparoscopic Ladd's surgery for malrotation manifested as midgut volvulus.

### Case Presentation

For the past three months, a 26-year-old lady had complained of sporadic colicky discomfort, vomiting, and constipation. The patient had no surgery or significant medical history. The patient's vitals were stable clinically, with 112/64 mmHg blood pressure, 72 bpm heart rate, 16 rpm respiration rate, 98.4 °F (36.9 °C) temperature, and 100% O<sub>2</sub> saturation on room air. The abdomen was somewhat enlarged but not sensitive on physical examination, and there was no sign of peritonitis.

The blood results were all within normal levels. The patient was evaluated using a contrast-enhanced CT scan of the abdomen. On the CT scan, the small intestine was located to the right of the abdominal midline, whereas the large intestine was located to the left of the abdominal midline. The relationship between superior mesenteric vessels was reversed, resulting in a swirling appearance of the mesentery as well as twisting of the mesentery vessels (whirlpool sign), indicating midgut volvulus and intestinal malrotation (Figure 1). The patient was hospitalized and then taken to Ladd's for the operation.

**Comment [6]:** In the English language, the correct way to enter intervals of numerical values is to use an en-dash and not a hyphen.

**Comment [7]:** In the English language, the correct way to enter intervals of numerical values is to use an en-dash and not a hyphen.

**Comment [8]:** Quotation numbers should always be placed after the period and after the comma, before the semicolon and colon, and no space should ever be left between them and punctuation marks. On the other hand, when more than two numbers are placed between parentheses for different quotations, if they are not consecutive, they are separated with commas without leaving spaces between the commas and the numbers, for example: [12,15,21,23].

**Comment [9]:** Quotation numbers should always be placed after the period and after the comma, before the semicolon and colon, and no space should ever be left between them and punctuation marks. On the other hand, when more than two numbers are placed between parentheses for different quotations, if they are not consecutive, they are separated with commas without leaving spaces between the commas and the numbers, for example: [12,15,21,23].

**Comment [10]:** 1. Images should be placed after the information is given about them or once they are mentioned.

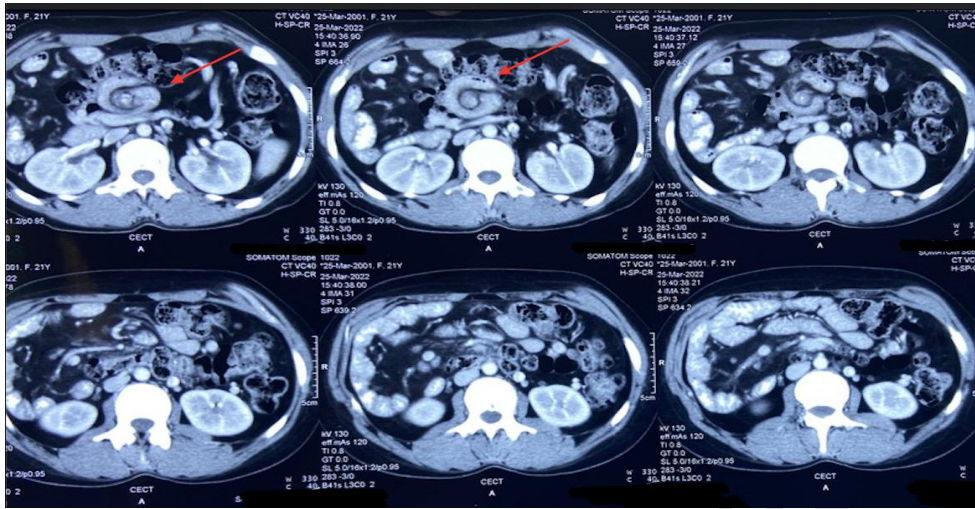
**Formatted:** English (United Kingdom)

**Formatted:** Subscript

**Formatted:** Font: Bold

**Formatted:** Font: Bold, Italic

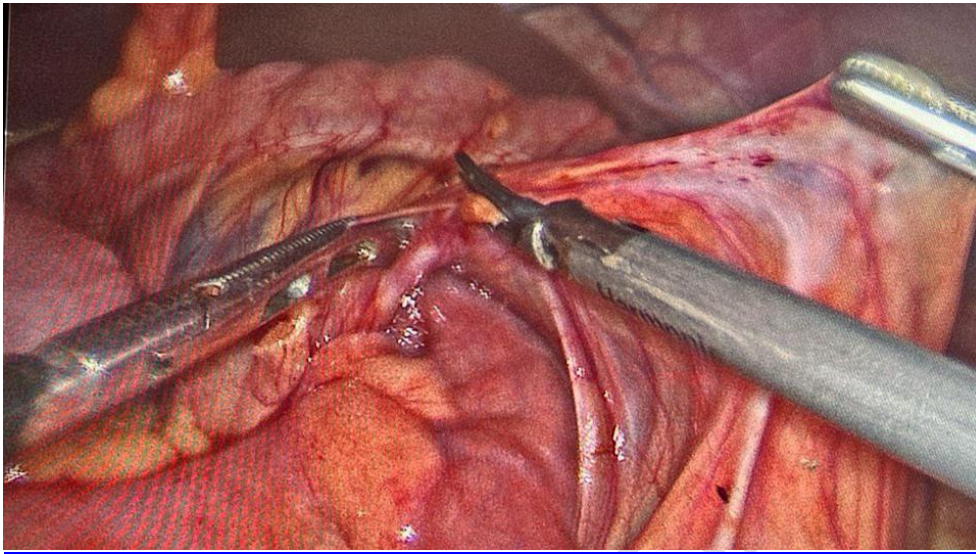
**Formatted:** Font: Bold



**Figure 1:** The swirling look of the mesentery as well as twisting of the mesentery vessels (Whirlpool sign)

Volvulus of the small bowel and intestinal malrotation were found during the laparoscopy. The entirety of the small intestine was located on the right side, and the colon was located on the left. Volvulus detorsion counterclockwise, division of Colo duodenal Ladd's bands (**Figure 2**), straightening of the duodenum's C-loop, mesenteric base widening, and appendectomy were all performed laparoscopically. The postoperative recovery of the patient was uneventful, and she was discharged on the fifth postoperative day. During subsequent visits, the patient appeared to be in good health, with none of the initial symptoms appearing.

**Formatted:** Font: Bold, Italic



**Figure 2:** Division of Ladd's bands

## Discussion

Normal embryological rotation of the intestine starts at six weeks and goes through three stages. The intestines exceed the abdomen during sStage 1. The bowel contents are extruded out of the umbilicus at 8 to 10 weeks of gestation, followed by a 90-degree counter-clockwise rotation along the axis of the superior mesenteric artery and return to the belly. Stage 2 is followed by another 180-degree counter-clockwise rotation of the midgut about the superior mesenteric artery (SMA), for a total of 270 degrees. The final step is to anchor the mesentery. The duodenum becomes retroperitoneally fixed in its third section, and the cecum becomes retroperitoneally attached to the right lateral abdominal wall. The upshot of this rotation pattern is a large base mesentery.-[6]

Intestinal malrotation refers to any deviation from the standard 270-degree counter-clockwise rotation. The entire small bowel is on the right due to non-rotation, whereas the colon is on the left. Aberrant mesenteric bands (Ladd's bands) develop and extend from the caecum to the lateral abdominal wall, crossing the duodenum and causing duodenal blockage as a result of correct rotation and fixation of the ceco-colic limb.-[7]

Adults frequently exhibit symptoms. Non-specific symptoms are more common, such as nausea and persistent stomach pain. Symptoms can occur as a result of a Ladd's band

**Comment [11]:** 1. The first time that abbreviations are used, they should be stated with their meaning, and then the abbreviations should be placed between parentheses, except for those that are universally known. In this manuscript, the abbreviations SMA and SMV are used without first stating their meaning.  
2.

**Comment [12]:** Quotation numbers should always be placed after the period and after the comma, before the semicolon and colon, and no space should ever be left between them and punctuation marks. On the other hand, when more than two numbers are placed between parentheses for different quotations, if they are not consecutive, they are separated with commas without leaving spaces between the commas and the numbers, for example: [12,15,21,23].

**Comment [13]:** Quotation numbers should always be placed after the period and after the comma, before the semicolon and colon, and no space should ever be left between them and punctuation marks. On the other hand, when more than two numbers are placed between parentheses for different quotations, if they are not consecutive, they are separated with commas without leaving spaces between the commas and the numbers, for example: [12,15,21,23].

**Comment [14]:** This text is more conducive to the background than to discussion. The discussion should focus primarily on comparing their clinical case with others that have been studied and published in the authors' country, on their continent, and in the rest of the world, in addition to other aspects of interest.

obstruction and/or a midgut volvulus (acute or chronic). Obstructive jaundice produced by mechanical biliary tract compression, chylous ascites, and superior mesenteric vein thrombosis caused by long-term lymphatic and vein occlusion is all rare examples of chronic volvulus.<sup>[8-11]. [8-11]</sup>

In adults, imaging is often utilized to identify intestinal malrotation. The upper gastrointestinal contrast series is highly accurate in demonstrating that the duodenojejunal junction does not cross the midline. Contrast-enhanced CT can show the entire small bowel to the right and the colon to the left, as well as an aberrant relationship between the superior mesenteric vein (SMV) and the SMA and the existence of midgut volvulus (whirlpool sign), which is described as twisting of the small bowel around the SMA.<sup>[12]</sup>

Our patient's CT scan findings revealed intestinal malrotation and midgut volvulus, with the characteristic "whirlpool sign,"<sup>7</sup> which were linked to intraoperative findings. Ladd's operation was performed laparoscopically on this patient. Dr. William Ladd's Ladd technique, launched in 1936, has long been the standard treatment for malrotation, particularly in children. Adults have successfully had the same treatment as we have. Ladd's procedure consists of counterclockwise volvulus detorsion, division of the Colo duodenal Ladd's bands, straightening of the duodenum's c loop, widening of the mesenteric base, and appendectomy. An appendectomy is performed because a future appendicitis diagnosis may be difficult. In recent years, early discharge and oral intake have made laparoscopic Ladd operations safe.<sup>[13, 14]. [13,14]</sup> The most common complication of the treatment is small intestinal obstruction due to adhesions, with the majority of patients presenting within one year.<sup>[15]. [15]</sup> As a result, monitoring these patients is crucial. During the postoperative phase, our patient appeared to be doing well with the removal of her complaints. There have been a few cases of adult midgut malrotation manifesting as volvulus. <sup>[16, 17, 18]</sup>

## Figures

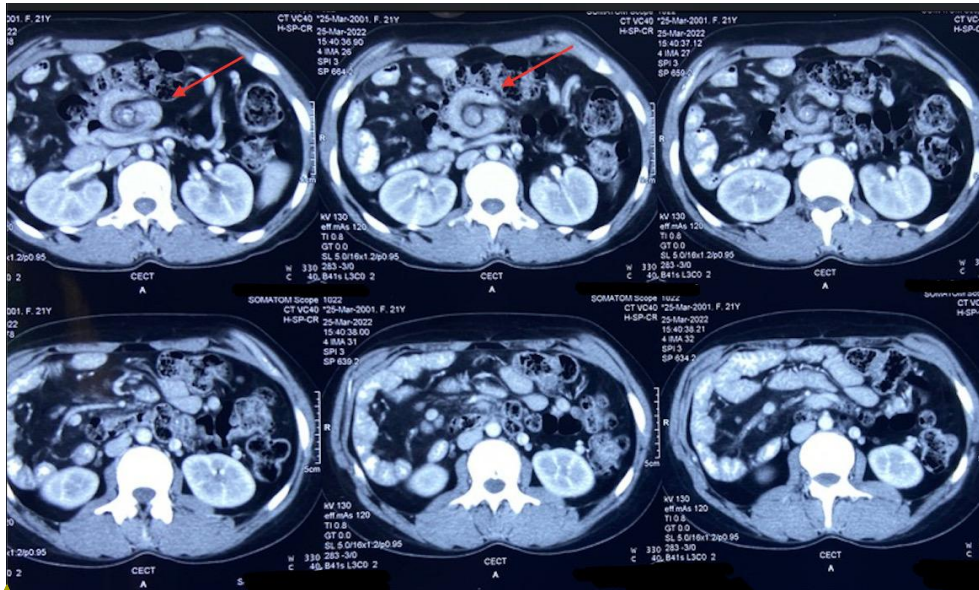
**Comment [15]:** Quotation numbers should always be placed after the period and after the comma, before the semicolon and colon, and no space should ever be left between them and punctuation marks. On the other hand, when more than two numbers are placed between parentheses for different quotations, if they are not consecutive, they are separated with commas without leaving spaces between the commas and the numbers, for example: [12,15,21,23].

**Comment [16]:** Quotation numbers should always be placed after the period and after the comma, before the semicolon and colon, and no space should ever be left between them and punctuation marks. On the other hand, when more than two numbers are placed between parentheses for different quotations, if they are not consecutive, they are separated with commas without leaving spaces between the commas and the numbers, for example: [12,15,21,23].

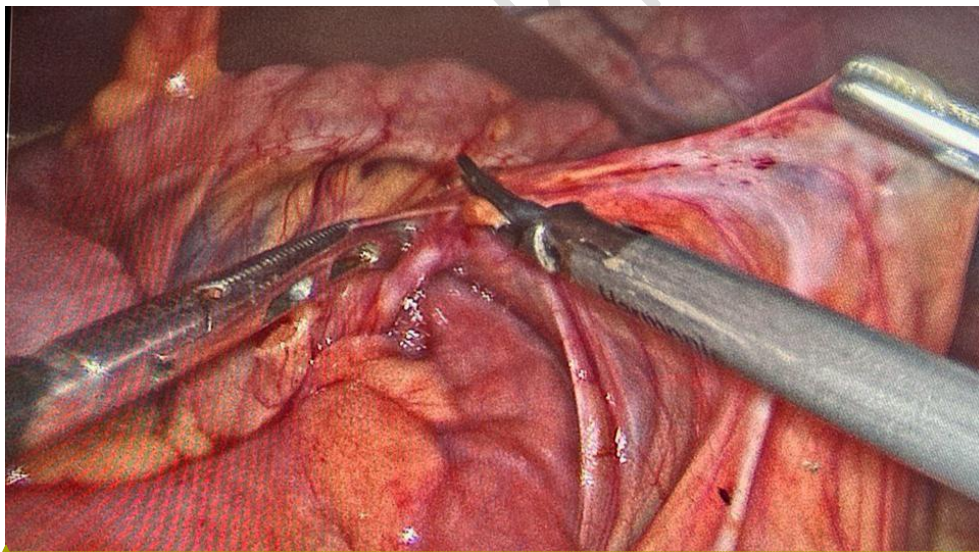
**Comment [17]:** Quotation numbers should always be placed after the period and after the comma, before the semicolon and colon, and no space should ever be left between them and punctuation marks. On the other hand, when more than two numbers are placed between parentheses for different quotations, if they are not consecutive, they are separated with commas without leaving spaces between the commas and the numbers, for example: [12,15,21,23].

**Comment [18]:** Quotation numbers should always be placed after the period and after the comma, before the semicolon and colon, and no space should ever be left between them and punctuation marks. On the other hand, when more than two numbers are placed between parentheses for different quotations, if they are not consecutive, they are separated with commas without leaving spaces between the commas and the numbers, for example: [12,15,21,23].

**Comment [19]:** Quotation numbers should always be placed after the period and after the comma, before the semicolon and colon, and no space should ever be left between them and punctuation marks. On the other hand, when more than two numbers are placed between parentheses for different quotations, if they are not consecutive, they are separated with commas without leaving spaces between the commas and the numbers, for example: [12,15,21,23].



**Figure 1: The swirling look of the mesentery as well as twisting of the mesentery vessels (Whirlpool sign)**



**Figure 2: Division of Ladd's bands**

## Conclusions

Although malrotation is common in children, symptomatic midgut malrotation can manifest in adults as non-specific symptoms. Making a diagnosis requires imaging and a high level of

Formatted: Font: Bold

Formatted: Font: Bold

suspicion. Ladd's procedure is a well-known malrotation operation. These patients must continue to be followed up on.

### Consent

written informed consent was obtained from the patient (or other approved parties) for publication of this case report and accompanying images

### Ethical Approval

All authors hereby declare that approval was taken from the institutional ethical committee.

### References

1. McIntosh R, Donovan EJ: Disturbances of rotation of the intestinal tract. *Am J Dis Child.* 1939, 57:116-66. 10.1001/archpedi.1939.01990010125010
2. Frantzides CT, Cziperle DJ, Soergel K, Stewart E: Laparoscopic Ladd procedure and rectopexy in the treatment of malrotation beyond the neonatal period. *Laparosc Endosc Percutan Tech.* 1996, 6:73-5.
3. Mazziotti MV, Strasberg SM, Langer JC: Intestinal rotation abnormalities without volvulus: the role of laparoscopy. *J Am Coll Surg.* 1997, 185:172-6. 10.1016/S1072-7515(01)00900-0
4. Kotze PG, Martins JF, Rocha JG, et al.: Ladd procedure for adult intestinal malrotation: Case report. *ABCD. Arquivos Brasileiros de Cirurgia Digestiva (São Paulo).* 2011, 24:89-91.
5. Aboagye J, Goldstein SD, Salazar JH, et al.: Age at a presentation of common pediatric surgical conditions: Reexamining dogma. *Journal of Paediatric Surgery.* 2014, 49:995-999. 10.1016/j.jpedsurg.2014.01.039
6. Gohl ML, DeMeester TR: Midgut malrotation in adults. An aggressive approach. *Am J Surg.* 1975, 129:319-23. 10.1016/0002-9610(75)90249-4

**Comment [20]:** 1. McIntosh R, Donovan EJ. Disturbances of rotation of the intestinal tract: Clinical Picture Based on Observations in Twenty Cases. *Am J Dis Child* [Internet]. 1939;57(1): 116–66. doi: 10.1001/archpedi.1939.01990010125010.

2. Frantzides CT, Cziperle DJ, Soergel K, Stewart E. Laparoscopic ladd procedure and cecopexy in the treatment of malrotation beyond the neonatal period. *Surg Laparosc Endosc.* 1996 Feb;6(1):73-5. PMID: 8808567.

7. Filston HC, Kirks DR: Malrotation: The ubiquitous anomaly. *J Pediatr Surg.* 1981, 16:614-20.
8. Wang C, Welch CE: Anomalies of intestinal rotation in adolescents and adults. *Surgery.* 1963, 54:839-55.
9. Brandt ML, Pokorny WJ, McGill CW ve ark: Late presentations of midgut malrotation in children. *Am J Surg.* 1985, 150:767-71. 10.1016/0002-9610(85)90426-X
10. Spitz L, Orr JD, Harries JT: Obstructive jaundice secondary to chronic midgut volvulus. *Arch Dis Child.* 1983, 58:383-5.10.1136/adc.58.5.383
11. Schwartz DL, So HB: Schneider KM ve ark: Recurrent chylous ascites associated with intestinal malrotation and lymphatic volvulus. *J Pediatr Surg.* 1983, 18:177-9. 10.1016/s0022-3468(83)80547-8
12. Nichols DM, Li DK: Superior mesenteric vein rotation: a CT sign of midgut malrotation. *AJR Am J Roentgenol.* 1983, 141:707-8. 10.2214/ajr.141.4.707
13. Ladd WE: Surgical diseases of the alimentary tract in infants: *N Engl J Med .* 1936:705-8. 10.1056/NEJM193610152151604
14. Matzke GM, Dozois EJ, Larson DW, et al.: Surgical management of intestinal malrotation in adults: comparative results for open and laparoscopic Ladd procedures. *Surg Endosc.* 2005, 19:1416-9. 10.1007/s00464-004-8249-7
15. Biko DM, Anupindi SA, Hanhan S.B, et al.: Assessment of recurrent abdominal symptoms after Ladd procedure: clinical and radiographic correlation. *Journal of Pediatric Surgery.* 2011, 46:1720-1725. 10.1016/j.jpedsurg.2011.03.018
16. Bhatia S, Jain S, Singh CB, et al.: Malrotation of the Gut in Adults: An Often Forgotten Entity . 2018, 10:2313. 10.7759/cureus.2313
17. Victor S Alemany MD: Adult Midgut Malrotation: A Case Report. *J Surg Proce Case Rep.* 2020, 1:1-5. 10.1016/S0149-7944(03)00030-8
18. Sahu SK, Raghuvanshi S, Sinha A, et al.: ADULT INTESTINAL MALROTATION PRESENTING AS MIDGUT VOLVULUS; CASE REPORT. *Journal of Surgical Arts.* 2012, 5(1):18-21.