

Case study

Title: **Midgut volvulus with intestinal malrotation in an adult: a case report**

ABSTRACT

Introduction: Intestinal malrotation is an uncommon congenital disorder characterized by the lack or partial rotation of the small bowel around the superior mesenteric arteries during the embryonic stage, with mid-gut volvulus occurring as a consequence. Approximately 64–90% of patients' symptoms manifest as acute intestinal obstruction due to midgut volvulus before the age of one year, but the presentation in adulthood is extremely rare. 0.2-0.5%.

Case report: A 26-year-old woman approached us with complaints of intermittent colicky discomfort, vomiting, and constipation for the previous three months. All of the patient's vital signs and blood parameters were normal. The CECT abdomen revealed a reversal of the relationship between superior mesenteric vessels, a swirl appearance of the mesentery, and twisting of the mesentery vessels (Whirlpool sign), indicating mid-gut volvulus and intestinal malrotation. The patient was scheduled for emergency surgery.

Conclusion: Although malrotation is frequent in childhood, symptomatic midgut malrotation can appear in adults with nonspecific symptoms. When trying to figure out the diagnosis, imaging and a high level of suspicion is very important.

Keywords: mid gut midgut volvulus, adult intestinal malrotation, malrotation, whirlpool sign

Background

Intestinal malrotation is a rare congenital condition defined by a partial or complete failure of the small bowel's 270-degree counterclockwise rotation around the superior mesenteric arteries during embryonic development, resulting in midgut volvulus. The symptoms of 64-90% of patients begin before the age of one year as acute intestinal obstruction due to midgut volvulus, although they are only present in 0.2-0.5% of adults. [1-3]. Malrotation causes clinical symptoms in 1 in 5000 to 6000 live births, with 90% of cases manifesting during childhood. According to recent studies, approximately 70% of children emerge by the age of one; other studies show that 75% of patients appear by the age of five [4,5]. Adults may experience a delayed diagnosis as a result of a lower degree of suspicion, which may increase morbidity and mortality. Adults require a high level of suspicion to be diagnosed with the condition. We present the case of a 26-year-old lady who underwent a laparoscopic Ladd's surgery for malrotation manifested as midgut volvulus.

Case Presentation

For the past three months, a 26-year-old lady had complained of sporadic colicky discomfort, vomiting, and constipation. The patient had no surgery or significant medical

history. The patient's vitals were stable clinically, with 112/64 mmHg blood pressure, 72 bpm heart rate, 16 rpm respiration rate, 98.4° F temperature, and 100% O₂ saturation on room air. The abdomen was somewhat enlarged but not sensitive on physical examination, and there was no sign of peritonitis. The blood results were all within normal levels. The patient was evaluated using a contrast-enhanced CT scan of the abdomen. On the CT scan, the small intestine was located to the right of the abdominal midline, whereas the large intestine was located to the left of the abdominal midline. The relationship between superior mesenteric vessels was reversed, resulting in a swirling appearance of the mesentery as well as twisting of the mesentery vessels (Whirlpool sign), indicating midgut volvulus and intestinal malrotation (Figure 1). The patient was hospitalized and then taken to Ladd's for the operation.

Volvulus of the small bowel and intestinal malrotation were found during the laparoscopy. The entirety of the small intestine was located on the right side, and the colon was located on the left. Volvulus detorsion **counterclockwise**, **counter clockwise** division of Colo duodenal Ladd's bands (Figure 2), straightening of the duodenum's c loop, mesenteric base widening, and appendectomy were all performed laparoscopically. The postoperative recovery of the patient was uneventful, and she was discharged on the fifth postoperative day. During subsequent visits, the patient appeared to be in good health, with none of the initial symptoms apparent.

Discussion

Normal embryological rotation of the intestine starts at six weeks and goes through three stages. The intestines exceed the abdomen during Stage 1. The bowel contents are extruded out **of** the umbilicus at 8 to 10 weeks of gestation, followed by a 90-degree counter-clockwise rotation along the axis of the superior mesenteric artery and return to the belly. Stage 2 is followed by another 180-degree counter-clockwise rotation of the midgut about the SMA, for a total of 270 degrees. The final step is to anchor the mesentery. The duodenum becomes retroperitoneally fixed in its third section, and the cecum becomes retroperitoneally attached to the right lateral abdominal wall. The upshot of this rotation pattern is a large base mesentery. [6]

Intestinal malrotation refers to any deviation from the standard 270-degree counter-clockwise rotation. The entire small bowel is on the right due to non-rotation, whereas the colon is on the left. Aberrant mesenteric bands (Ladd's bands) develop and extend from the caecum to the lateral abdominal wall, crossing the duodenum and causing duodenal blockage as a result of correct rotation and fixation of the ceco-colic limb. [7]

Adults frequently exhibit symptoms. Non-specific symptoms are more common, such as nausea and persistent stomach pain. Symptoms can occur as a result of a Ladd's band obstruction and/or a midgut volvulus (acute or chronic). Obstructive jaundice produced by mechanical biliary tract compression, chylous ascites, and superior mesenteric vein thrombosis caused by long-term lymphatic and vein occlusion is all rare examples of chronic volvulus [8-11].

In adults, imaging is often utilized to identify intestinal malrotation. The upper gastrointestinal contrast series is highly accurate in demonstrating that the duodenojejunal junction does not cross the midline. Contrast-enhanced CT can show the entire small bowel to the right and the colon to the left, as well as an aberrant relationship between the SMV and the SMA and the existence of midgut volvulus (whirlpool sign), which is described as twisting of the small bowel around the SMA. [12]

Our patient's CT scan findings revealed intestinal malrotation and midgut volvulus, with the characteristic "whirlpool sign," which were linked to intraoperative findings. Ladd's operation was performed laparoscopically on this patient. Dr. William Ladd's Ladd technique, launched in 1936, has long been the standard treatment for malrotation, particularly in children. Adults have successfully had the same treatment as we have. Ladd's procedure consists of **counterclockwise** **counter clockwise** volvulus detorsion, division of the Colo duodenal Ladd's bands, straightening of the duodenum's c loop, widening of the mesenteric base, and appendectomy. An appendectomy is performed because a future appendicitis diagnosis may be difficult. In recent years, early discharge and oral intake have made laparoscopic Ladd operations safe (13, 14). The most common complication of the treatment is small intestinal obstruction due to adhesions, with the majority of patients presenting within one year [15]. As a result, monitoring these patients is crucial. During the postoperative phase, our patient appeared to be doing well with the removal of her complaints. There have been a few cases of adult midgut malrotation manifesting as volvulus. [16, 17, 18]

Figures

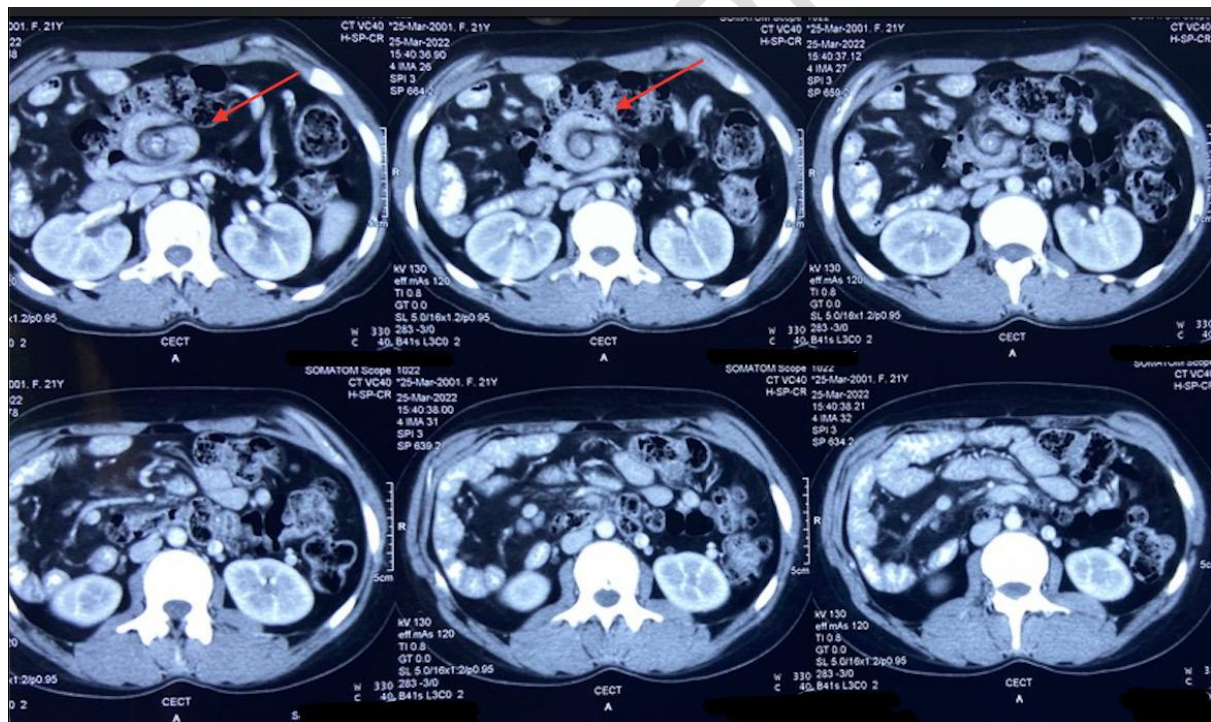


Figure 1: The swirling look of the mesentery as well as twisting of the mesentery vessels (Whirlpool sign)

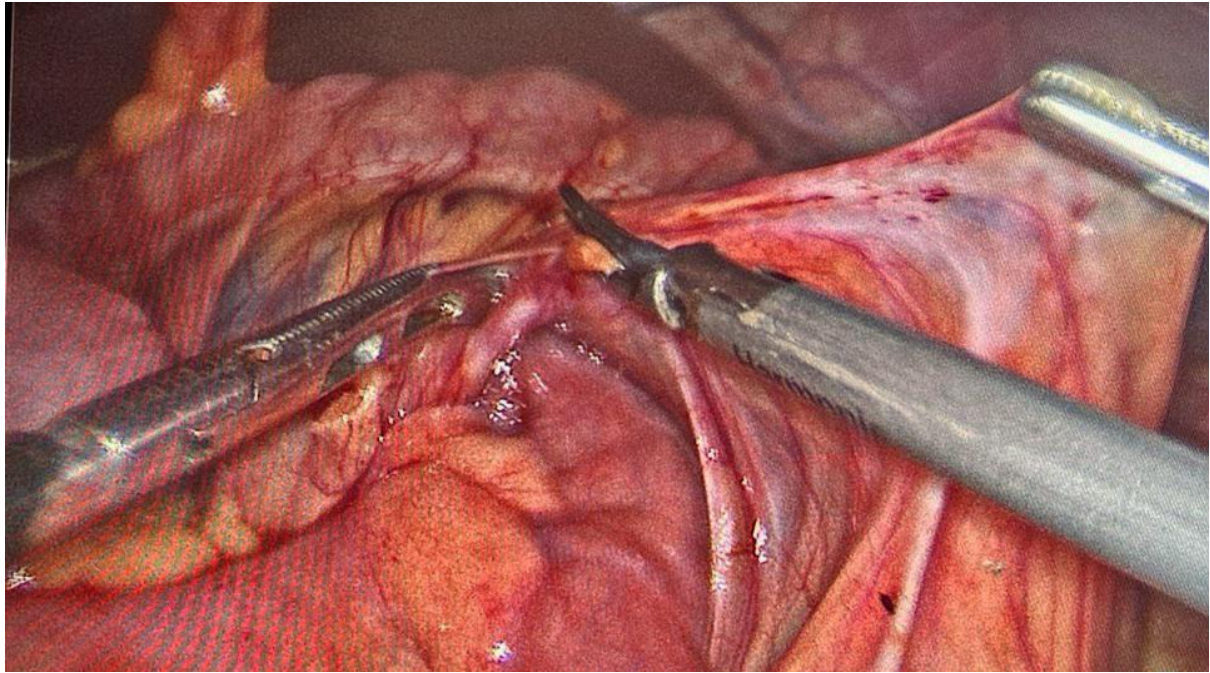


Figure 2: Division of Ladd's bands

Conclusions

Although malrotation is common in children, symptomatic midgut malrotation can manifest in adults as nonspecific symptoms. Making a diagnosis requires imaging and a high level of suspicion. Ladd's procedure is a well-known malrotation operation. These patients must continue to be followed up on.

Consent

written informed consent was obtained from the patient (or other approved parties) for publication of this case report and accompanying images

Ethical Approval

All authors hereby declare that approval was taken from the institutional ethical committee.

References

1. McIntosh R, Donovan EJ: Disturbances of rotation of the intestinal tract. *Am J Dis Child.* 1939, 57:116-66. 10.1001/archpedi.1939.01990010125010
2. Frantzides CT, Cziperle DJ, Soergel K, Stewart E: Laparoscopic Ladd procedure and rectopexy in the treatment of malrotation beyond the neonatal period. *Laparosc Endosc Percutan Tech.* 1996, 6:73-5.
3. Mazziotti MV, Strasberg SM, Langer JC: Intestinal rotation abnormalities without volvulus: the role of laparoscopy. *J Am Coll Surg.* 1997, 185:172-6. 10.1016/S1072-7515(01)00900-0

4. Kotze PG, Martins JF, Rocha JG, et al.: Ladd procedure for adult intestinal malrotation: Case report. ABCD. Arquivos Brasileiros de Cirurgia Digestiva (São Paulo). 2011, 24:89-91.
5. Aboagye J, Goldstein SD, Salazar JH, et al.: Age at a presentation of common pediatric surgical conditions: Reexamining dogma. Journal of Paediatric Surgery. 2014, 49:995-999. 10.1016/j.jpedsurg.2014.01.039
6. Gohl ML, DeMeester TR: Midgut malrotation in adults. An aggressive approach. Am J Surg. 1975, 129:319-23. 10.1016/0002-9610(75)90249-4
7. Filston HC, Kirks DR: Malrotation: The ubiquitous anomaly. J Pediatr Surg. 1981, 16:614-20.
8. Wang C, Welch CE: Anomalies of intestinal rotation in adolescents and adults. Surgery. 1963, 54:839-55.
9. Brandt ML, Pokorny WJ, McGill CW et al.: Late presentations of midgut malrotation in children. Am J Surg. 1985, 150:767-71. 10.1016/0002-9610(85)90426-X
10. Spitz L, Orr JD, Harries JT: Obstructive jaundice secondary to chronic midgut volvulus. Arch Dis Child. 1983, 58:383-5. 10.1136/adc.58.5.383
11. Schwartz DL, So HB, Schneider KM et al.: Recurrent chylous ascites associated with intestinal malrotation and lymphatic volvulus. J Pediatr Surg. 1983, 18:177-9. 10.1016/s0022-3468(83)80547-8
12. Nichols DM, Li DK: Superior mesenteric vein rotation: a CT sign of midgut malrotation. AJR Am J Roentgenol. 1983, 141:707-8. 10.2214/ajr.141.4.707
13. Ladd WE: Surgical diseases of the alimentary tract in infants: N Engl J Med . 1936:705-8. 10.1056/NEJM193610152151604
14. Matzke GM, Dozois EJ, Larson DW, et al.: Surgical management of intestinal malrotation in adults: comparative results for open and laparoscopic Ladd procedures. Surg Endosc. 2005, 19:1416-9. 10.1007/s00464-004-8249-7
15. Biko DM, Anupindi SA, Hanhan S.B, et al.: Assessment of recurrent abdominal symptoms after Ladd procedure: clinical and radiographic correlation. Journal of Pediatric Surgery. 2011, 46:1720-1725. 10.1016/j.jpedsurg.2011.03.018
16. Bhatia S, Jain S, Singh CB, et al.: Malrotation of the Gut in Adults: An Often Forgotten Entity . 2018, 10:2313. 10.7759/cureus.2313
17. Victor S Alemany MD: Adult Midgut Malrotation: A Case Report. J Surg Proc Case Rep. 2020, 1:1-5. 10.1016/S0149-7944(03)00030-8
18. Sahu SK, Raghuvanshi S, Sinha A, et al.: ADULT INTESTINAL MALROTATION PRESENTING AS MIDGUT VOLVULUS; CASE REPORT. Journal of Surgical Arts. 2012, 5(1):18-21.