

### Antitoxic effects of *Solanum betaceum* cav. peel skin extract

#### Abstract

**Background:** In Indonesia, *Solanum betaceum* cav is a traditional herbal medicine which their skin is often wasted because not many people known its content.

**Aims:** To find out the anti-toxic effect of *Solanum betaceum* cav peel skin ethanol extract on rat's renal post-carrageenan induction.

**Study Design:** Laboratory experimental in vivo study

**Place and duration of study:** This research was done at Animal Research Facilities (ARF) Medical Faculty University of Indonesia, at September to December 2021.

**Methodology:** The samples used in this research are male white mice, Wistar strain (*Rattus norvegicus*) with the body weight 180–220 gram which divided into 5 groups, negative control (saline), positive control (sodium diclofenac 7mg/kgBW), and *Solanum betaceum* Cav. peel skin ethanol extract groups (70mg/kgBW, 140mg/kgBW, and 280mg/kgBW). Mice's buccal mucosa was injected with Carrageenan 1%. Macroscopic and microscopic observation was done before, 24 hours, 48 hours and 72 hours post carrageenan injection.

**Results:** Phytochemical test showed that *Solanum betaceum* Cav. peel skin ethanol extract contains phenolic, flavonoid, tannin, and alkaloid. At all doses, anti-toxic effect of *Solanum betaceum* Cav. peel skin ethanol extract have same healing effectiveness within 48 hours. In positive control, the renal were normal at 48 hours. Meanwhile, the negative control's healing effectiveness was seen at 72 hours.

**Conclusion:** The anti-toxic effect of *Solanum betaceum* Cav. peel skin ethanol extract has effective healing process at all doses in 48 hours post-carrageenan induction without affect rats' body weight, however with lower intensity than positive control which using diclofenac as anti-inflammatory drug.

**Keywords:** *Solanum betaceum* Cav. peel skin extract, antitoxic, carrageenan, rat's renal.

#### INTRODUCTION

Indonesia has a variety of natural herbal medicine. There are around 30.000 vegetables with 7.000 among them has potential herbal therapy.<sup>1</sup> One of these is *Solanum betaceum* Cav.<sup>2</sup> Its fruit has high protein, low calory, low lipid, and contain micronutrients such as vitamins, mineral, and bioactive components like as flavonoid, steroid terpenoids, alkaloid, saponin, and tannin. The flavonoid content has antimicrobial effect.<sup>3</sup>

Now, the uses of *Solanum betaceum* Cav limited on its fruits as antioxidant usage. The potency of peel skin has not already been known just as natural wasted material. Actually, there is a lot of phytochemical content within the peel skin.<sup>4</sup> The peel skin of *Solanum betaceum* Cav contains vitamins such as vitamin C, A, E, B6, also terpenoid, steroid, saponin, alkaloid and tannin.<sup>5</sup> Therefore this study was done to find out the anti-toxic effect of the peel skin of *Solanum betaceum* Cav ethanol extract on rat's renal after inflammatory induction on its buccal mucosa with carrageenan as inflammatory agent. The result will give an inflammatory process which release inflammatory mediators cause vasodilatation, exudation and phagocyte migration toward inflammatory area. All of these will examine microscopically in the renal as the first metabolic organ against inflammation.

## Materials and Methods

This study is a laboratory experimental in vivo study to find out the anti toxic effect of *Solanum betaceum* Cav peel skin ethanol extract on kidney rat post carrageenan injection on buccal mucosa as inflammatory induction. The ethical clearance letter was given by The Ethics Committee of the Faculty of Medicine, University of Indonesia – Cipto Mangunkusumo Hospital with regards of the Protection of human rights and welfare in medical research, No: UN2.F1/ETIK/PPM.00.02/2021. The study consisted of 5 groups with two rats for each group. The first group was given saline solution as negative control group. The second was given sodium diclofenac 7 mg/kgBW as positive control group. The treatment group consisted of three groups that were given the peel skin of *Solanum betaceum* Cav ethanol extract with dose of 70 mg/kgBW, 140 mg/kgBW dan 280 mg/kgBW. After 30 minutes the 1% carrageenan injection was done on buccal mucosa of each subject.

The microscopic examination and the thickness measurement on right and left buccal mucosa were done before, 24 hours, 48 hours, and 72 hours post carrageenan injection. Subjects of study were executed by injection of 1.5 ml xylazine and 3 ml ketamines intra peritoneal. Renal organs of subjects were fixated on 10% formalin buffer. The specimen was processed into paraffin and the Hematoxyllin eosin (HE) to find out the microscopic examination. Renal albumin degeneration was scored as criteria: widen of tubular lumen, debris cells accumulation, epithelial tubular hyperplasia, inflammatory cells within glomerular and periglomerular (Table 1)

Score 1: Normal (no inflammatory sign of tubular and glomerular/periglomerular)

Score 2: Mild (one or two inflammatory sign of tubular and glomerular/ periglomerular)

Score 3: Severe (three of four inflammatory sign of tubular and glomerular / periglomerular).

Table 1. Hystopathological score of renal albumin degeneration .

Score	Criteria
1	No sign of albumin degeneration based on tubular lumen wide, debris cells accumulation, tubular epithelial hyperplasia, inflammatory cells of glomerular/periglomerular
2	One to two signs.
3	Three to four signs.

## RESULTS

Phytochemical test result showed on Table 2

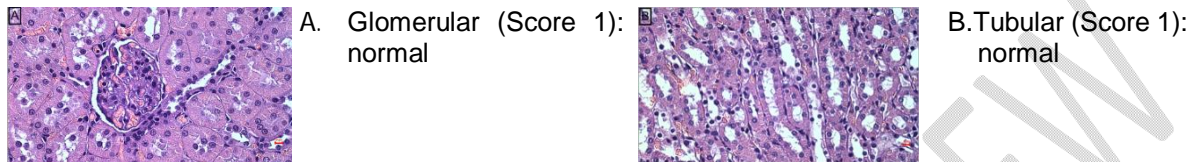
Table 2. Phytochemical content of peel skin of *Solanum betaceum* Cav ethanol extract

No	Secondary metabolit	Method	Result
1.	Phenolic	FeCl <sub>3</sub> 5% solution	+
2.	Flavonoid	a. HCl 38% solution + Mg	+
		b. H <sub>2</sub> SO <sub>4</sub> 2N solution	+
		c. NaOH 10% solution	+
3.	Steroid	Lieberman-Burchard solution	-
4.	Triterpenoid	Lieberman-Burchard solution	-

5.	Saponin	HCl solution + H <sub>2</sub> O	-
6.	Tannin	FeCl <sub>3</sub> 1% solution	+
7.	Alkaloid	a. Heger solution	+
		b. Wagner solution	+
		c. Dragendorff solution	+

Histopathological features of renal subjects showed on Figure 1, 2, and 3.

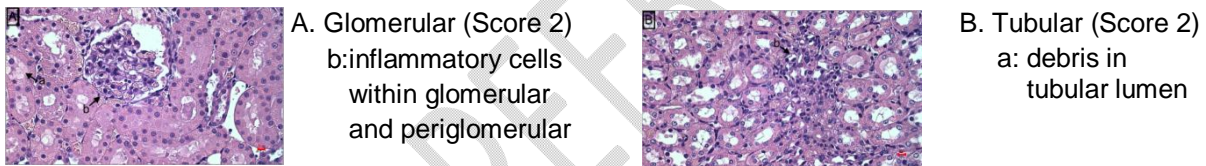
Histopathological score 1 (normal) found on renal of positive control subjects on 48 hours (Figure 1)



Magnification (10x40); Hematoxyllin Eosin

Figure 1. Score 1. Positive control subject on 48 hours.

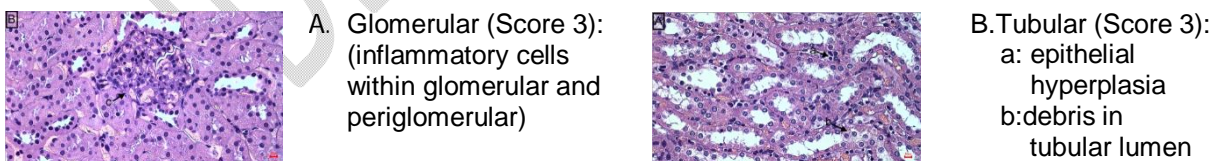
Histopathological score 2 (mild) found on renal of peel skin *Solanum betaceum* Cav ethanol extract 280mg/kgBW subjects on 72 hours (Figure 2).



Magnification (10x40); Hematoxyllin Eosin

Figure 2. Score 2. Peel skin *Solanum betaceum* Cav ethanol extract 280mg/kgBW subject on 72 hours.

Histopathological score 3 (severe) found on renal of negative control subjects on 48 hours (Figure 3).



Magnification (10x40); Hematoxyllin Eosin

Figure 3. Score 3. Negative control subject on 48 hours.

Microscopic examination renal subjects on each group on 24, 48, 72 hours post carrageenan induction showed in Figure 4.

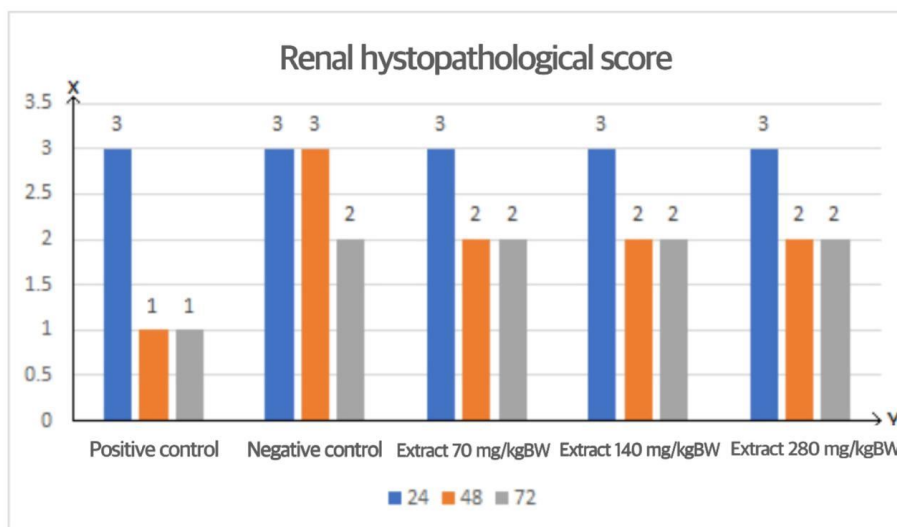


Figure 4. Renal histopathological score

This study resulted in categorical data (ordinal score) therefore the non parametric statistical analysis used Kruskal Wallis test with the result there was significant differences ( $p < 0.05$ ) among groups that meant there were significant differences within the inflammatory and healing process among groups (Table 3).

Table 3. *Kruskal Wallis* test of renal histopathological features

	Carrageenan injection	
	Before	After
Kruskal-Wallis H	29.000	000
Df	14	14
Asymp. Sig.	.010	1.000

Body mass and buccal mucosa thickness of subjects were measured digitally before and 24, 48, 72 hours after carrageenan induction with the result there was increasing within subject groups.

## Discussion

Phytochemical test of peel skin *Solanum betaceum* Cav ethanol extract in this study showed there are phenolic, flavonoid, tannin, and alkaloid content (Table 2). This result proper with the previous study that bioactive component of peel skin *Solanum betaceum* Cav are flavonoid, steroid terpenoid, alkaloid saponin, tannin and micronutrient like vitamins, mineral, high protein, low calories of lipid, and a lot of active biocomponent.<sup>3</sup> Flavonoid phenolic content of peel skin *Solanum betaceum* Cav ethanol extract has anti allergy, anti inflammatory, and anti oxidant potency.<sup>6</sup> Tannin within peel skin *Solanum betaceum* Cav ethanol extract also has anti oxidant and anti toxic function. The bioactive component content of peel skin *Solanum betaceum* Cav ethanol extract role toward toxic effect in this study which induced by carragennan as pro inflammatory agent showed effective in healing process.

The observation in this study used microscopic evaluation of renal subjects with the reason

that renal is a very rich vascular organ as a cleanser or blood supply filtrated to put the organic rest material such as urea, creatinine, uric acid, hormone and hemoglobin rest product out. However this cleanser organ will be destroyed by toxic material exposure.<sup>7</sup> The early renal dysfunction is able to be evaluated through hystopathological feature in form of albumin degeneration i.e. increase or widen of tubular lumen, debris cell accumulation within lumen, tubular epithelial hyperplasia and inflammatory cells within glomerular and periglomerular.<sup>8</sup>

Degeneration is a non specific form of destruction occurred by etiological factors that disturb the cell function and often used as early indicator of necrosis. In several cases, degeneration occurred after swelling of cells with or without cytoplasm vacuolization and fragmentation, and pale stain. Degeneration could be reversible or irreversible.<sup>9</sup> The increase or widen of tubular lumen is caused by the necrosis of epithelial tubular cells. It is occurred by the destruction of glomerular that cause lower of filtration rate capacity and make the tubular function to excrete solved materials become heavier. In this condition, every renal tubular cell becomes osmotic diuretic and loss of obligatory water further the dead of cells. The necrotic of tubular cells give rest of necrotic cells or debris within tubular lumen.<sup>8</sup> Apical tubular hyperplasia (HTA) can occur spontaneously related to chronic progressive nephropathy or caused of certain chemical exposure. This is suspected as putative pre neoplastic lesion as part of neoplasm manifestation.<sup>9</sup> The widen of Bowman capsule caused by a lot of glomerular cells destruction as if there is high decrease of glomerular cells make the widen of glomerular and Bowman capsule.<sup>10</sup>

Macroscopic evaluation of subject body mass and the bucal mucosa thickness was done before, 24, 48, and 72 hours after carragenaan injection as pro inflammatory agent. Carragenaan induction cause releasing of inflammatory mediator that cause capillary vasodilatation and phagocyte migration toward inflamed area.<sup>11</sup>

Histopathological evaluated to the renal destruction in form of albumin degeneration based on the increase or widen of tubular lumen, debris cells accumulation, epithelial hyperplasia of tubular and inflammatory cells within glomerular and periglomerular (Table1). The result showed that on 24 hour, there was no healing process of renal subject of peel skin *Solanum betaceum* Cav ethanol extract with dose of 70 mg/kgBW, 140 mg/kgBW and 280 mg/kgBW. There were a lot of inflammatory cells found in microscopic feature. This same condition also found in negative control subjects up to 48 hours (Figure 3). In this phase, the edema of buccal mucosa of subjects was not cured however there was no influence on the subject body weight.

On 48 hours, the anti toxic effect of peel skin *Solanum betaceum* Cav ethanol extract with dose of 70 mg/kgBW, 140 mg/kgBW and 280 mg/kgBW showed the same potency that started renal healing process with the reduction of inflammatory cells on glomerular and periglomerular (Figure 2). This is caused of flavonoid content as anti inflammatory and anti oxidant material.<sup>6</sup> Anti oxidant is needed to prevent oxidative stress that role act as an important etiology of degenerative diseases.<sup>13</sup> Previous study revealed that flavonoid has potency as apoptosis induction to stop the cell cycle and change the way involved in cancer formation such as inflammation and proliferation.<sup>12</sup>

In this study, the effectiveness of all doses of peel skin *Solanum betaceum* Cav ethanol extract is still lower than those of positive control which showed that on 48 hours there was no renal inflammatory cells found that mean the healing process more rapid within positive control subjects (Figure 1). Sodium diclofenac used as positive control due to its anti inflammatory, analgetic, and antipyretic potency therefore often used as a comparative material control within anti inflammatory studies beside its ability to be absorbed rapidly with minimal side effect compared to other anti inflammatory drugs.<sup>14</sup>

At 48 hours, there was still no renal healing effect found on negative control group (score 3). There was healing process effect found on each group of peel skin *Solanum betaceum* Cav ethanol extract and totally healing process effect found on positive control found at 48 hours without influenced the buccal mucous thickness and body mass increase of subjects.

Anti toxic effect of peel skin *Solanum betaceum* Cav ethanol extract with dose of 70 mg/kgBW, 140 mg/kgBW, 280 mg/kgBW on 72 hours same as those on 48 hours. Each concentration has the same effect toward inflammatory healing process therefore the 70 mg/kgBW as the minimal dose is recommended as an anti inflammatory optimum dose. However, the effectivity of peel skin *Solanum betaceum* Cav ethanol extract on 72 hours is still lower than dose of positive control on 48 hours. On the other hand the anti toxic effect of negative control started on 72 hours with the less of inflammatory cells that showed lower decrease than those of peel skin *Solanum betaceum* Cav ethanol extract and positive control subjects (Figure 4).

## Conclusion

Peel skin *Solanum betaceum* Cav ethanol extract has anti toxic effect on inflammatory process especially on 48 hours. The optimum dose recommended is 70 mg/kgBW that showed the same effect with those of the higher dose of 140mg/kgBW and 280 mg/kgBW. However its effect is still lower than those of sodium diclofenac as positive control.

## References

1. Werdhasari, A. The role of antioxidant for health. J. Bio. Med. Ind. 2014. 3(2):59-68.
2. Asih, I.A.R.A.; Sudiarta, I.W.; Wulan Suci, A.A. Antioxidant activity of flavonoid compound within ethanol extract of *Solanum betaceum* Cav. Journal of Chemistry. 2015. Vol. 9. No. 1.
3. Santika, P.C.N.; Sudiono, J. The Effectivity of Tamarillo (*Cyphomandra Betacea* Sendtn.) Decoction Against The Growth Of *Candida albicans*. Jurnal PDGI. 2020.
4. Mandal, P.; Ghosal, M. Antioxidant activities of different parts of tree tomato fruit (*Cyphomandra betasea* (Cav.) sendtn. International Journal of Pharmaceutical Sciences Review and Research. ISSN. 2012. 0976-044 (3-2).
5. Wiwik, S.R.; Oktarini N.W.A.C.; Puspawati N.M.; Swantara I.M.D.; Asih I.A.R.A. "Antioxidant

Activity of Flavonoid Compounds Ethanol Extract of Dutch Eggplant Seeds (*Solanum Betaceum*, Syn) in Inhibiting Fat Peroxidation Reactions in Blood Plasma of Wistar Mice" *Cakra Kimia*. 2014.

6. Arinaldo. Effect of Addition of Acetic Acid Concentration to Ethanol Solvent on the Effectiveness of Dutch Eggplant Anthocyanin Extraction. Faculty of Agricultural Technology, Andalas University, Padang. 2011.

7. Sharp, P.; Villano, J. *The Laboratory Rat Second Edition*. Boca Raton: CRC Press. h.1. 2013.

8. Nirwana, I. Activity of Pomegranate Extract (*Punica granatum L.*) As Pulp Capping Material Against Expression of IL-10, IL-6, TGF- $\beta$ 1, MMP-1 and Type I Collagen in Mechanical Perforated Teeth. Dissertation. Surabaya: Faculty of Medicine, Airlangga University. 2012. p.83.

9. Kurniawan, S.N.; Raisa, N.; Margaret. *Use of Experimental Animals in Research in Neurology*. Malang: Universitas Brawijaya Press. 2018. h. 44.

10. Pasha, K.; Gopal, R.M.; Kumar, R.B.; Ayesha, Q.; Srinivasulu, M.; Suseela, K. Study of oxidative stress and antioxidant status in ascitic patients with ovarian cancer in comparison to liver cirrhosis patients. *MOJ Proteome Bioinform*. 2017. 6(1):00186. doi: 10.15406/ mojpb.2017.06.00186.

11. Anggraini, O.D. Effects of Arumanis Mango Peel Extract on Carrageenin-induced Reduction of Foot Edema in Male White Mice. Faculty of Medicine, University of Jember. Thesis. 2016.

12. Guclu, U.G.O.; Mazza, G. Saponins: Properties, applications and processing. *Crit. Rev. Food Science. Nutrient*. 2007, 47, 231–258.

13. Espin, S.; Gonzalez-Manzano, S.; Tacos, V.; Poveda, C.; Ayuda-Durán, B.; Gonzalez-Paramas, A.M.; Santos-Buelga, C. Phenolic composition and antioxidant capacity of yellow and purple-red Ecuadorian cultivars of tree tomato (*Solanum betaceum Cav.*). *Food Chem*. 2016. 194. 1073–1080.

14. Tjay, T.H.; Grace. *Essential Medicines. Efficacy, Use and Side Effects Edition V*. Publisher PT. Elex Media Komputindo Gramedia Group, Jakarta. 2012.