

Original Research Article

Evaluation of a Protocol for Diagnosis and Treatment of Primary Congenital Glaucoma in Tanta University Eye Hospital

Abstract

Background: Primary congenital glaucoma is the most common type of glaucoma in infancy. It manifests within the first few years of life and is not associated with any other systemic or ocular abnormalities. This study aimed to evaluate a protocol for diagnosis and treatment of primary congenital glaucoma at Tanta University Eye Hospital.

Methods: The study was prospective interventional on 60 eyes of 36 infants and children who presented between December 2018 to March 2021 at Tanta University Eye Hospital in Egypt. All patients were presented with primary congenital glaucoma and were managed according to specific diagnostic, therapeutic and follow up regimen. Pre- and Post-operative clinical data were recorded, and results were studied.

Results: The mean of age \pm SD (range) at first presentation was 11.33 \pm 21.76 (0.5-120) months and of follow-up period was 7.85 \pm 2.71 (4-13) months. The mean of pre-operative IOP, corneal diameter, C/D ratio and AxL was 24.1 \pm 5.9 (12–41.5) mmHg, 12.97 \pm 0.69 (11–14.5) mm, 0.57 \pm 0.18 (0.2–0.9) and 21.87 \pm 1.28 (19.1–26.8) mm respectively, and post-operatively was 14.4 \pm 3.09 (8.5–20.5) mmHg, 12.71 \pm 0.89 (11–14.5) mm, 0.48 \pm 0.22 (0.2–1) and 22.16 \pm 1.53 (19–25.9) mm respectively. Surgical interventions included 1ry surgeries (trabeculotomy in 21 eyes and CTT with MMC in 39 eyes), 2ry surgeries (CTT with MMC in four eyes) and 3ry surgery (Ahmed valve implantation in one eye). Complete success was achieved in 38 eyes (63.3%) and qualified success in 22 eyes (36.7%).

Conclusions: The current protocol applied at Tanta University Eye Hospital for diagnosis and treatment of primary congenital glaucoma proved efficacy and safety. Primary surgical intervention in the form of trabeculotomy (for mild cases) and combined trabeculotomy-trabeculectomy with MMC (for moderate to advanced cases) is a successful regimen for management of these eyes.

Keywords: Primary Congenital Glaucoma, Trabeculotomy, Combined Trabeculotomy-Trabeculectomy, Mitomycin C

UNDER PEER REVIEW

Introduction:

Glaucoma is a disease characterized by a group of ocular disorders caused by multifactorial etiology leading finally to optic neuropathy and progressive visual loss.^[1, 2]

According to The World Health Organization, glaucoma is the leading cause of 2% of visual impairment and 8% of blindness worldwide in 2010, and the prevalence of glaucoma is expected to increase despite of recent advances in diagnosis and treatment.^[3-5]

Childhood glaucoma can be either primary, if there is an isolated idiopathic abnormality in the development of the anterior chamber angle, or secondary, if the aqueous outflow is reduced due to congenital or acquired ocular disease or systemic disorder. Primary childhood glaucoma is further classified into congenital glaucoma (PCG) and juvenile open-angle glaucoma (JOAG).^[6-8]

Primary congenital glaucoma is the most common type of glaucoma in infancy. It manifests within the first few years of life and is not associated with any other systemic or ocular abnormalities. It results from arrest in the normal development of the anterior chamber angle at the level of the trabecular meshwork (isolated trabeculodysgenesis), which decreases the aqueous humor outflow with subsequent increase of the intraocular pressure (IOP).^[9-11]

Increased IOP in the early childhood can result in multiple structural changes of the eye leading to multifactorial impairment of the visual function such as severe myopia caused by elongation of the eyeball, corneal disorders as edema, opacities, breaks in the descemet's membrane (Haab's stria), astigmatism and optic nerve fiber damage.^[12-15]

Diagnosing a child with glaucoma places a burden on both the family and the child. Being a chronic disease requires lifelong follow-up including multiple hospital visits, examination under general anesthesia, repeated surgeries, anti-glaucoma topical treatment and visual aids as spectacles. Also, the child may have difficulty in dealing with the society and needs special support at school.^[13, 16]

The main treatment of primary congenital glaucoma is surgical, while medical treatment plays only a supportive role to help in IOP control prior to surgery and after partially successful surgeries.^[7]

Surgery should be done as early as possible in order to maintain visual function and prevent structural changes to the eye by decreasing the intraocular pressure.^[17-19]

Surgical interventions include goniotomy, trabeculotomy, combined trabeculotomy-trabeculectomy, aqueous-shunt implantation and in the case of repeated failure of surgery, cyclodestructive techniques with diode laser can be done.^[9, 11]

Prognosis of pediatric glaucoma depends on many factors including the age at presentation, early establishment of the diagnosis, the time of surgical intervention and continuous follow up.^[20]

When early diagnosed and properly treated, prognosis of PCG is better than other types of childhood glaucoma, but most of untreated cases of PCG end in blindness.^[21, 22]

This study aimed to evaluate a protocol for diagnosis and treatment of primary congenital glaucoma at Tanta University Eye Hospital.

Materials and Methods:

This prospective interventional study was carried on 60 eyes of 34 children with PCG who underwent glaucoma surgery. All surgeries were performed under general anesthesia. All patients received postoperative medications including topical antibiotic, steroid, and cycloplegic eye drops (after CTT) and tapered over 4 weeks. All cases were basically examined at the office on 1st and 3rd days post-operative, then weekly for 1 month, then once a month for 3 months then once every 3 months.

Exclusion criteria were children presented with glaucoma due to any other cause, children with follow up period less than 3 months and children with past history of glaucoma surgical intervention.

Clinical examination data was recorded and included intraocular pressure (IOP) measured by Perkin's tonometer, horizontal corneal diameter measured by calipers, corneal clarity examined under operating microscope or slit lamp, cup/disc ratio examined by indirect ophthalmoscopy with 20 Diopter lens and axial length measured by A-scan ultrasound.

Diagnosis was confirmed by presence of 2 or more of the following criteria: [IOP > 21 mmHg, optic nerve cupping (increased C/D ratio > 0.3, asymmetry \geq 0.2 and focal thinning), corneal Haab's stria, corneal diameter \geq 11 mm before one month or \geq 12 mm in the first year and corneal clarity/ haze graded as follow ^[23]: (grade 0: no corneal haze, grade 1: iris details are visible, grade 2: pupillary margin is visible, iris details are not visible, grade 3: pupillary margin is not visible and grade 4: cornea is totally opaque).

Trabeculotomy

A corneal traction suture was placed at 12 o'clock using 8-0 vicryl, a fornix-based 6 mm peritomy was created in the superior quadrant, a triangular limbus-based scleral flap of 3 x 3 x 4 mm was created and dissected 1 mm anterior to the limbus into clear cornea, anterior chamber paracentesis was performed, and AC filled by viscoelastic material, identifying Schlemm's canal; under high magnification, a vertical slit incision is made astriding the corneoscleral junction and deepened carefully until the outer wall of the canal is opened, the Harms trabeculotome was passed into each end of the canal of Schlemm up to the joint and smoothly rotated into the anterior chamber dissecting the inner wall of Schlemm's canal and the trabecular meshwork, the scleral flap was sutured with 10-0 nylon, viscoelastic material wash was done and the conjunctival flap was closed with 8-0 vicryl interrupt sutures.

Combined trabeculotomy-trabeculectomy with MMC

A corneal traction suture was made at 12 o'clock using 8-0 vicryl, A fornix-based 6 mm peritomy was created in the superior quadrant with partial tenonectomy when necessary, Mitomycin-C (0.3mg/ml) immersion of the large area was soaked into cut pieces of cellulose sponges and applied between the conjunctiva–Tenon's capsule and sclera for 2 min, after that the site of application of MMC was washed with 30 ml of balanced salt solution (BSS), a limbus-based rectangular scleral flap of 3 x 4 mm was created and dissected 1 mm anterior to the limbus into clear cornea, anterior chamber paracentesis was performed and AC filled by viscoelastic material, a 2mm incision was cut along the bottom of the scleral flap and slowly deepened until the outer wall of Schlemm's canal opened up, and percolation of aqueous humor was seen, Harms trabeculotome was smoothly rotated into the anterior chamber dissecting the inner wall of Schlemm's canal and the trabecular meshwork, a deep corneo-scleral block was excised using a kelly punch and a peripheral iridectomy was done using vannus scissors, the scleral flap was sutured with 10-0 nylon, viscoelastic material wash was done then the conjunctival flap was closed with 8-0 vicryl interrupt sutures and subconjunctival injection of dexa and atropin was performed.

Glaucoma drainage implant

A corneal traction suture is applied using 8-0 vicryl, a fornix-based peritomy was performed in the supero-temporal quadrant, the drainage tube is trimmed to permit a 2 mm insertion in the AC and is bevel cut to an angle of 30°, to facilitate AC entering, the valve was primed using 1 ml of BSS, then, it was secured to the sclera, with its anterior edge 10 mm posterior to the limbus using two 8-0 silk sutures, then, a 23-gauge needle was used to enter the anterior chamber at the surgical limbus, pointing towards the center of the pupil, viscoelastic material was injected to maintain the anterior chamber then the tube was inserted with bevel facing anteriorly, a Scleral graft was used to cover the scleral entry site and the anterior 8 mm

of the tube by securing it to the episcleral surface with interrupted 10-0 Nylon sutures and the conjunctiva and Tenon's capsule were reapproximated to the limbus with 8-0 vicryl sutures.

Statistical analysis

Statistical analysis was done by SPSS v25 (IBM Inc., Chicago, IL, USA). Quantitative variables were presented as mean and standard deviation (SD), compared by paired Student's t- test for the same group, detected for correlation by Spearman's correlation coefficient and analysed by repeated measures ANOVA test. Qualitative variables were presented as frequency and percentage (%) and were compared by Chi-square test. Kaplan-Meier survival analysis was conducted to evaluate the cumulative success rate. Log-rank test was used for comparing curves. A two tailed P value ≤ 0.05 was considered significant.

Results:

Table 1: Demographic data, main complaints, baseline clinical examination and surgical interventions of the studied patients

Age groups	< 1st month	3 (8.8 %)
	1 - 12 months	27 (79.4 %)
	>12 – 24 months	2 (5.9 %)
	>24 months	2 (5.9 %)
Gender	Male	20 (58.8%)
	Female	14 (41.2%)
Complaint	Big eye	48 (80%)
	Photophobia	39 (65%)
	Lacrimation	27(45%)
	Change in eye color	25 (41.7%)
	Others	11 (18.3%)
Baseline clinical examination	Intraocular pressure	24.1 \pm 5.9
	Corneal diameter	12.97 \pm 0.69
	Cup/disc ratio	0.57 \pm 0.18
	Axial length	21.87 \pm 1.28
Primary interventions	Trabeculotomy	21 (35%)
	Combined trabeculotomy-Trabeculectomy with MMC	39 (65%)
Secondary interventions	Combined trabeculotomy-trabeculectomy with MMC	4 (6.7%)
Tertiary interventions	Ahmed Glaucoma valve implantation	1 (1.7%)

Data are presented as mean \pm SD or frequency (%), MMC: mitomycin C

Postoperative at the last follow-up was significantly higher at one medication compared to two medication (P value= 0.017) while preoperative was insignificant different between one and two medications. Corneal diameter and cup/disc ratio were significantly higher in preoperative compared to postoperative (P value 0.006, <0.001 respectively) while axial length was significantly lower in preoperative compared to postoperative (P value 0.03).

Table 2: Preoperative and postoperative anti-glaucoma medical treatment at the last follow-up visit and means of clinical parameters

	One medication	Two medications	P Value
Preoperative	25 (41.7%)	19 (31.7%)	0.451
Postoperative at the last follow-up	17 (28.3%)	5 (8.3%)	0.017*
	Preoperative	Postoperative	
Corneal diameter	12.97 ± 0.69	12.71 ± 0.89	0.006*
Cup/disc ratio	0.57 ± 0.18	0.48 ± 0.22	<0.001*
Axial length	21.87 ± 1.28	22.16 ± 1.53	0.03*

Data are presented as mean ± SD or frequency (%)

HypHEMA was significantly different among trabeculotomy, CTT with MMC and AGV (P value= 0.002). Early shallowing of AC, cataract and wound gaping were insignificantly different among trabeculotomy, CTT with MMC and AGV.

Table 3: Postoperative surgical complications

	Trabeculotomy (n=21)	CTT with MMC (n=43)	AGV (n=1)	P value
HypHEMA	1 (1.54%)	3 (4.62%)	1 (1.54%)	0.002*
Early shallowing of AC	1 (1.54%)	1 (1.54%)	0 (0%)	0.855
Cataract	0 (0%)	2 (3.07%)	0 (0%)	0.590
Wound gaping	0 (0%)	1 (1.54%)	0 (0%)	0.771

Data are presented as mean ± SD or frequency (%), AC: anterior chamber, CTT: combined trabeculotomy-trabeculectomy, MMC: mitomycin C, AGV: Ahmed glaucoma valve

Cumulative success and failure rates (primary, secondary and tertiary surgical interventions) and relationship between the results of the primary surgical interventions and the type of primary surgery (trabeculotomy and combined trabeculotomy trabeculectomy) were significantly different among success, qualified success and failure (P value <0.05).

Table 4: Results and cumulative success and failure rates after primary, secondary and tertiary surgical interventions, and relationship between the results of the primary surgical interventions and the type of primary surgery

		Success	Qualified success	Failure	P value
Results of surgical interventions	Primary (n=60)	35 (58.3%)	21 (35%)	4 (6.7%)	---
	Secondary (n=4)	2 (50%)	1 (25%)	1 (25%)	
	Tertiary (n=1)	1 (100%)	0 (0%)	0 (0%)	
Cumulative success and failure rates	Primary (n=60)	35 (58.3%)	21 (35%)	4 (6.7%)	< 0.001*
	Secondary(n=4)	37 (61.7%)	22 (36.7%)	1 (1.7%)	< 0.001*
	Tertiary (n=1)	38 (63.3%)	22 (36.7%)	0 (0%)	0.039*
Relationship between primary surgical interventions' results and its type of surgery	Trabeculotomy	8 (13.3%)	12 (20%)	1 (1.7%)	0.012*
	Combined trabeculotomy trabeculectomy	27 (45%)	9 (15%)	3 (5%)	< 0.001*

Data are presented as mean \pm SD or frequency (%).

Regarding clinical parameters of the completely successful trabeculotomy eyes and of the completely successful primary CTT with MMC eyes, IOP, corneal diameter and cup/disc ratio were significantly higher in preoperative compared to post operative (P value <0.05) while axial length were insignificantly different.

Table 5: Preoperative and postoperative clinical parameters of the completely successful trabeculotomy eyes and the completely successful primary CTT with MMC eyes

		Preoperative	Postoperative	P value
Clinical parameters of the completely successful trabeculotomy eyes	IOP (mmHg)	21.36 \pm 4.1	14.45 \pm 3.64	0.001*
	Corneal diameter	12.19 \pm 0.53	11.81 \pm 0.37	0.048*
	Cup/disc ratio	0.32 \pm 0.89	0.25 \pm 0.75	0.048*
	Axial length	20.44 \pm 0.68	20.29 \pm 0.62	0.236
Clinical parameters of the completely successful primary CTT with MMC eyes	IOP (mmHg)	26.57 \pm 2.77	14.25 \pm 3.02	<0.001*
	Corneal diameter	13.39 \pm 0.45	12.81 \pm 0.65	<0.001*
	Cup/disc ratio	0.57 \pm 0.14	0.38 \pm 0.10	<0.001*
	Axial length	22.01 \pm 0.69	21.86 \pm 0.70	0.071

Data are presented as mean \pm SD or frequency (%), CTT: combined trabeculotomy-trabeculectomy, IOP: intraocular pressure

There was moderate positive correlation between preoperative IOP and the percentage of IOP reduction ($r=0.65$, $p<0.001$). In the trabeculotomy eyes and the CTT with MMC eyes, IOP reduced significantly at the last follow-up visit ($p< 0.001$).

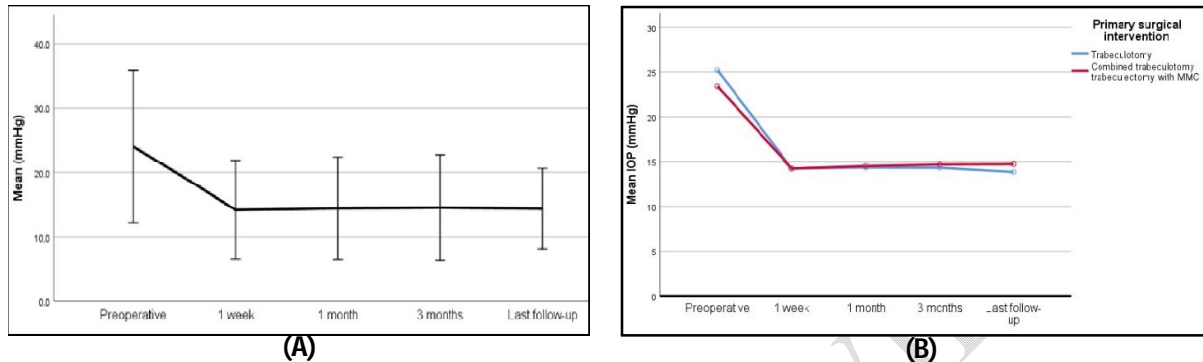


Figure 1: The mean preoperative and postoperative IOP of (A) the total eyes in the study and (B) of the primary trabeculotomy and combined trabeculotomy-trabeculectomy eyes

There's no significant difference between the two procedures proved by log rank test.

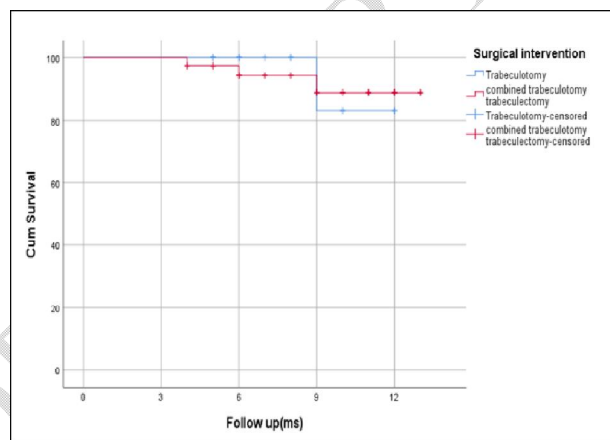


Figure 2: Kaplan-Meier survival analysis curve of the primary surgeries

Discussion

The most common complaint by the parents was big eye (buphthalmos) in 80% of cases which may be due to that the most of cases are presented in the first year of life so the globe had the ability to stretch under the effect of elevated IOP.^[24] This is in agreement with some studies,^[25, 26] while other studies reported corneal haze as the most presenting symptom.^{[7, 27-}

The mean baseline intraocular pressure (IOP) was 24.1 ± 5.9 mmHg which is in the same range of some studies^[30, 31] and lower than reported in other studies.^[32] The mean postoperative IOP at the end of the follow-up period was 14.4 ± 3.09 with significant reduction of 9.7 mmHg (40.2%) ($p < 0.001$). This reduction was comparable with previous studies; Yalvac et al.^[33] in a study of the success of trabeculotomy in primary congenital glaucoma demonstrated reduction of 36.4 % of the IOP with mean postoperative IOP of 21.41 ± 7.34 mmHg ($p < 0.001$). Zhang X et al.^[34] reported decline 39.3 % with mean postoperative IOP of 19.22 ± 8.67 mmHg ($p < 0.001$).

Corneal clarity showed significant improvement at the last follow-up period. Before surgery, corneal haze was found in 96.7% of cases from grade 1 to grade 4. At the end of follow-up period, only 11.7% showed corneal haze between grade 1 and 2 with old Haab's stria and 2 cases of central corneal opacity ($p < 0.001$). These results were better than achieved by Mandal et al.^[35] Haab's stria was found at first presentation in this study, in 40% of the cases. This is less than found by Gue et al 51.8% and Esfandiari et al 72.6% in their studies.^[36, 37]

The mean baseline cup/disc in our study was 0.57 ± 0.18 and final C/D was 0.48 ± 0.22 with mean postoperative reduction 0.09 ($p < 0.001$). One eye progressed to full cupping after failed primary combined trabeculotomy – trabeculectomy with MMC and remained unchanged until the end of the follow-up period inspite of improvement of the other clinical parameters after secondary interventions. Cup/disc ratio reduced in 53.3% , higher than the rate achieved by Quigley^[38] (40%). Wu et al.^[39] found a correlation between the young age at the time of surgery and the reversal of the cupping after successful reduction of the IOP.

We achieved reduction in the mean horizontal corneal diameter from 12.97 ± 0.69 mm preoperatively to 12.71 ± 0.89 mm at the end of the follow-up period with significant mean reduction of 0.27 mm ($p=0.006$). Some studies recorded significant reduction of corneal

diameter after primary congenital glaucoma surgeries^[40, 41], while in the study made by Yalvac et al^[33] there was postoperative increase in the mean corneal diameter.

In the completely successful primary trabeculotomy (8 eyes) and primary combined trabeculotomy- trabeculectomy with MMC (27 eyes), reduction of the mean axial length was of no statistical significance ($p = 0.236$ and 0.071 , respectively), while other parameters (corneal diameter, cup/disc ratio and IOP) showed statistically significant reduction postoperatively.

In agreement of our results, Alsheikheh et al.^[42] demonstrated significant increase in the mean axial length from 22.6 ± 1.8 mm to 24.4 ± 2.0 mm at the last examination ($p < 0.001$).

In the present study the usage of medical treatment before surgery was limited for cases of very high IOP and in whom medical condition didn't allow rapid surgical intervention, so it was used only in 44 eyes (73.3%) (one medication was given to 25 eyes and two medications were given to 19 eyes) ($p = 0.451$). Postoperatively, at the end of the follow-up period, the need for medical treatment declined to 36.7% (22 eyes) to maintain IOP less than 21 mmHg (17 eyes were on one medication and 5 eyes on two medications) ($p = 0.017$). This percentage was comparable with that presented by Papadopoulos M. et al (38%) in the British Infantile and Childhood Glaucoma (BIG) Eye Study^[7] and lower than demonstrated by Sanaa et al.^[43] (58%).

Among 21 eyes operated with trabeculotomy, total success rate was 95.2% after one trabeculotomy (success was achieved in eight eyes, qualified success in 12 eyes and failure only in one eye). In 39 eyes (with moderate to severe PCG) underwent CTT with MMC, the total success rate was 92.3% (success achieved in 27 eyes and qualified success in nine eyes). The total success rate after primary surgical interventions was 93.3% ($p < 0.001$).

Between four eyes which underwent CTT with MMC as a secondary surgical intervention after failure of the primary one, success was achieved in two eyes, qualified success in one

eye and one eye needed third surgical intervention in the form of Ahmed glaucoma valve implantation. After secondary surgical interventions total success rate increased to 98.3% (complete success in 37 eyes (61.7%) and qualified success in 22 eyes (36.7%) ($p < 0.001$).

Kaplan-Meier survival analysis revealed high cumulative probability of success for both trabeculotomy (100% and 83.3%) and CTT with MMC (94.1% and 89%) at 6 and 12 months with no significant difference between the two procedures proved by log rank test ($p = 0.884$) which mean that each procedure was suitable for the cases it was chosen for.

Cai et al.^[40] in a retrospective study presented success rates of trabeculotomy 97.0%, 93.2%, and 74.5% after one, three and five years of follow-up.

In the present study, no intraoperative complications were recorded for any case. Postoperative complications occurred mostly after combined trabeculotomy-trabeculectomy with MMC (10.77%) ($p = 0.048$). Hyphema developed in a total of five eyes due to cleavage of angle vessels and were conventionally managed. Early shallowing of the anterior chamber occurred in two eyes and resolved spontaneously. Peripheral cataract which didn't interfere with vision, developed in two cases four and eight months after CTT with MMC.

These complications were comparable with other studies^[30, 31, 34, 36] and none of the eyes developed serious devastating complications (such as endophthalmitis, suprachoroidal hemorrhage or phthisis bulbi) or lost light perception.

Limitations: Small sample size, short follow up period, non-commitment of some parents to attend the scheduled follow-up dates and medical condition of some patients did not allow examination under general anesthesia on its scheduled date.

Conclusions:

Primary surgical intervention in the form of trabeculotomy (for mild cases) and combined trabeculotomy-trabeculectomy with MMC (for moderate to advanced cases) is a successful regimen for management of these eyes.

Ethical Approval and consent:

An informed written consent was obtained from parents of the patients. The study was done after approval from the Ethical Committee Tanta University Hospitals.

References:

1. Casson RJ, Chidlow G, Wood JP, Crowston JG, Goldberg I. Definition of glaucoma: clinical and experimental concepts. *Clin Experiment Ophthalmol*. 2012;40:341-9.
2. Agarwal P, Daher AM, Agarwal R. Aqueous humor TGF- β 2 levels in patients with open-angle glaucoma: A meta-analysis. *Mol Vis*. 2015;21:612.
3. Harasymowycz P, Birt C, Gooi P, Heckler L, Hutnik C, Jinapriya D, et al. Medical Management of Glaucoma in the 21st Century from a Canadian Perspective. *J Ophthalmol*. 2016;2016:6509809.
4. Kolko M, Horwitz A, Thygesen J, Jeppesen J, Torp-Pedersen C. The Prevalence and Incidence of Glaucoma in Denmark in a Fifteen Year Period: A Nationwide Study. *PLOS ONE*. 2015;10:0132048.
5. Baudouin C, Kolko M, Melik-Parsadaniantz S, Messmer EM. Inflammation in Glaucoma: From the back to the front of the eye, and beyond. *Prog Retin Eye Res*. 2021;83:100916.
6. Aponte EP, Diehl N, Mohny BG. Incidence and Clinical Characteristics of Childhood Glaucoma: A Population-Based Study. *Arch Ophthalmol*. 2010;128:478-82.
7. Papadopoulos M, Cable N, Rahi J, Khaw PT, Investigators tBES. The British Infantile and Childhood Glaucoma (BIG) Eye Study. *Investig Ophthalmol Vis Sci*. 2007;48:4100-6.
8. Kipp MA. Childhood glaucoma. *Pediatr Clin North Am*. 2003;50:89-104.
9. Wormald R, Dickersin K. Evidence-based ophthalmology. *Ophthalmology*. 2013;120:2361-3.

10. Sarfarazi M, Akarsu AN, Hossain A, Turacli ME, Aktan SG, Barsoum-Homsy M, et al. Assignment of a locus (GLC3A) for primary congenital glaucoma (Buphthalmos) to 2p21 and evidence for genetic heterogeneity. *Genomics*. 1995;30:171-7.
11. Stamper R. Developmental and childhood glaucoma. *Becker-Shaffer's Diagnosis and Therapy of Glaucomas*. 2009:294-311.
12. Esfandiari H, Prager A, Hassanpour K, Kurup SP, Mets-Halgrimson R, Yoon H, et al. The Long-term Visual Outcomes of Primary Congenital Glaucoma. *J Ophthalmic Vis Res*. 2020;15:326-30.
13. Haddad MA, Sampaio MW, Oltrogge EW, Kara-José N, Betinjane AJ. Visual impairment secondary to congenital glaucoma in children: visual responses, optical correction and use of low vision AIDS. *Clinics (Sao Paulo)*. 2009;64:725-30.
14. Ko F, Papadopoulos M, Khaw PT. Primary congenital glaucoma. *Prog Brain Res*. 2015;221:177-89.
15. Badawi AH, Al-Muhaylib AA, Al Owaifeer AM, Al-Essa RS, Al-Shahwan SA. Primary congenital glaucoma: An updated review. *Saudi J Ophthalmol*. 2019;33:382-8.
16. Moreno MN, Morales Fernández L, Ruiz Medrano M, Martínez de la Casa JM, Madrigal Sánchez R, Hernández García E, et al. Quality of life and visual function in children with glaucoma in Spain. *Arch Soc Esp Oftalmol (Engl Ed)*. 2019;94:119-24.
17. Ben-Zion I, Tomkins O, Moore DB, Helveston EM. Surgical results in the management of advanced primary congenital glaucoma in a rural pediatric population. *Ophthalmology*. 2011;118:231-5.
18. Helmy H. Combined trabeculotomy-trabeculectomy versus Ahmed valve implantation for refractory primary congenital glaucoma in Egyptian patients: a long-term follow-up. *Electron Physician*. 2016;8:1884-91.

19. deLuise VP, Anderson DR. Primary infantile glaucoma (congenital glaucoma). *Surv Ophthalmol.* 1983;28:1-19.
20. Mokbel TH, El Hefney EM, Hagraas SM, ALNagdy AA, Badawi AE, Kasem MA, et al. Childhood glaucoma profile in Dakahelia, Egypt: a retrospective study. *Int J Ophthalmol.* 2018;11:674.
21. Shields MB, Allingham RR, Damji KF. Shields' textbook of glaucoma: Lippincott Williams & Wilkins; 2005.
22. Kargi SH, Koc F, Biglan AW, Davis JS. Visual acuity in children with glaucoma. *Ophthalmology.* 2006;113:229-38.
23. Gupta N, Kalaivani M, Tandon R. Comparison of prognostic value of Roper Hall and Dua classification systems in acute ocular burns. *Br J Ophthalmol.* 2011;95:194-8.
24. Sampaolesi R, Zarate J, Sampaolesi JR. The Glaucomas: Volume I - Pediatric Glaucomas: Springer Berlin Heidelberg; 2016.
25. Aziz A, Fakhoury O, Matonti F, Pieri E, Denis D. Epidemiology and clinical characteristics of primary congenital glaucoma. *J Fr Ophtalmol.* 2015;38:960-6.
26. Omoti AE, Uhumwangho OM. Problems of management of primary congenital glaucoma in Benin City, Nigeria. *Niger Postgrad Med J.* 2007;14:310-3.
27. Tamçelik N, Atalay E, Bolukbasi S, Çapar O, Ozkok A. Demographic features of subjects with congenital glaucoma. *Indian J Ophthalmol.* 2014;62:565-9.
28. Farid MF, Anany M, Awwad MA. Surgical Outcomes of Primary Congenital Glaucoma in Children Under One Year from the Nile Delta. *Clin Ophthalmol.* 2021;15:1145-51.
29. Bayoumi NH. Surgical management of primary congenital glaucoma in Egypt. *J Egypt Ophthalmol Soc.* 2016;109:85.

30. Khalil DH, Abdelhakim MA. Primary trabeculotomy compared to combined trabeculectomy–trabeculotomy in congenital glaucoma: 3-year study. *Acta ophthalmologica*. 2016;94:550-4.
31. Mandal AK, Bhatia PG, Bhaskar A, Nutheti R. Long-term surgical and visual outcomes in Indian children with developmental glaucoma operated on within 6 months of birth. *Ophthalmology*. 2004;111:283-90.
32. Alanazi FF, Song JC, Mousa A, Morales J, Al Shahwan S, Alodhayb S, et al. Primary and secondary congenital glaucoma: baseline features from a registry at King Khaled Eye Specialist Hospital, Riyadh, Saudi Arabia. *Am J Ophthalmol*. 2013;155:882-9.
33. Yalvac I, Satana B, Suveren A, Eksioglu U, Duman S. Success of trabeculotomy in patients with congenital glaucoma operated on within 3 months of birth. *Eye*. 2007;21:459-64.
34. Zhang X, Du S, Fan Q, Peng S, Yu M, Ge J. Long-term surgical outcomes of primary congenital glaucoma in China. *Clinics*. 2009:543-51.
35. Mandal AK, Bhatia PG, Bhaskar A, Nutheti R. Long-term surgical and visual outcomes in Indian children with developmental glaucoma operated on within 6 months of birth. *Ophthalmology*. 2004;111:283-90.
36. Esfandiari H, Basith SST, Kurup SP, Mets-Halgrimson R, Hassanpour K, Yoon H, et al. Long-term surgical outcomes of ab externo trabeculotomy in the management of primary congenital glaucoma. *J Pediatr Ophthalmol Strabismus*. 2019;23:222.
37. Guo C, Wu Y, Xu L, Li M, Wang Z, Ni N, et al. Evaluation of preoperative speed of progression and its association with surgical outcomes in primary congenital glaucoma patients: a retrospective study. *BMC ophthalmology*. 2017;17:1-6.
38. Quigley HA. Results, with Trabeculotomy and Study of Reversible Cupping. *Ophthalmology*. 1982;89:219-26.

39. Wu S-C, Huang SCM, Kuo C-L, Lin K-K, Lin S-M. Reversal of optic disc cupping after trabeculotomy in primary congenital glaucoma. *Can J Ophthalmol*. 2002;37:337-41.
40. Cai Y, Li M-Y, Shen Y-Y, Liu L-N. [Long-term effect of trabeculotomy on primary congenital glaucoma]. *Chin J Ophthalmol*. 2004;40:733-6.
41. Nouredin BN, El-Haibi CP, Cheikha A, Bashshur ZF. Visco canalostomy versus trabeculotomy ab externo in primary congenital glaucoma: 1-year follow-up of a prospective controlled pilot study. *Br J Ophthalmol*. 2006;90:1281.
42. Alsheikheh A, Klink J, Klink T, Steffen H, Grehn F. Long-term results of surgery in childhood glaucoma. *Graefes Arch Clin Exp Ophthalmol*. 2007;245:195-203.
43. Yassin SA. Long-Term Visual Outcomes in Children with Primary Congenital Glaucoma. *Eur J Ophthalmol*. 2017;27:705-10.