

A comparison of the effect on postoperative pain between lateral femoral cutaneous nerve block and local infiltration anesthesia after total hip arthroplasty: a randomized trial

ABSTRACT

Aims: No gold standard for pain management after total hip arthroplasty (THA) exists. This prospective, randomized, open-label study aimed to determine whether lateral femoral cutaneous nerve block and local infiltration analgesia (LIA) were effective analgesic adjuvants to femoral nerve block (FNB) after THA.

Study design: Prospective, randomized, open-label trial

Place and Duration of Study: Department of Anesthesia, Nagasaki Rosai Hospital, Sasebo, Japan between April 2019 and May 2020.

Methodology:

This study included 50 patients who underwent THA under total intravenous anesthesia using propofol. All patients received ultrasound-guided FNB using 0.25% levobupivacaine 20 mL before the operation. Patients were randomly allocated to one of the following two groups: Group B (n=25), which received ultrasound-guided lateral femoral cutaneous nerve block with 0.25% levobupivacaine 20 mL after FNB; and Group I (n= 25), which received 0.25% levobupivacaine 20 mL over the incision line into the muscle, and the subcutaneous, and cutaneous tissue along the wound edge after the fascia closure. All patients received 1000 mg intravenous acetaminophen before the end of the operation, and at 6, 12, 18, and 24 h after the operation. The patients received 50 mg of diclofenac sodium, as rescue analgesics, if needed. Nursing staff evaluated the postoperative pain using a numerical rating scale (NRS) at 0, 1, 3, 6, 12, 18, and 24 h postoperatively.

Results: No significant difference was observed in patient characteristics, except the operative time, between the groups. Additionally, no significant difference was found in NRS and in the frequency of rescue analgesics during the study period between the groups.

Conclusion: We concluded that both lateral femoral cutaneous nerve block and LIA with FNB would have the equivalent adjunctive analgesic effect after THA.

Key words: total hip arthroplasty, femoral nerve block, lateral femoral nerve block, local infiltration anesthesia, postoperative pain.

1. INTRODUCTION

“Total hip arthroplasty (THA) is often associated with moderate to severe postoperative pain and peripheral nerve blocks have been used as part of a multimodal analgesic strategy. Pain after THA consists of pain at the site of the incision, the hip joint, and pain caused by reflexogenic contracture of the quadriceps musculature”¹. “Owing to the complex sensory innervation of the hip joint, no single nerve block allows sufficient analgesia. The combination of multiple nerve blocks plays an essential role in general anesthesia”². “Peripheral nerve blocks used for postoperative pain management after THA include femoral nerve block (FNB), fascia iliaca block, and lumbar plexus block”³. “Numerous analgesics and analgesic techniques have been applied for pain management after THA”⁴. “However, no gold standard exists for pain management after THA. Inadequate pain control not only affects patient satisfaction, but also negatively impacts surgical outcomes”⁵.

“Wound pain may play a role in pain after THA. Local wound infiltration (LIA) has been used as part of an analgesic regimen for THA. LIA has additional analgesic efficacy in THA when combined with a multimodal analgesic regimen”³. Supplemental single-shot femoral nerve block shows beneficial effects on postoperative management and recovery after THA⁶. “The analgesic effect of nerve blocks after THA surgery is well established; however, the lateral femoral cutaneous nerve block in this setting is uncertain”⁷. “The lateral femoral cutaneous nerve is a sensory branch from the lumbar plexus and supplies parts of the lateral and anterior upper thigh. Lateral femoral cutaneous nerve block seeks to remove wound pain after THA. Reports on whether lateral femoral cutaneous nerve block combined with opioids and NSAIDs is effective for postoperative pain after THA have controversial results”^{1,3}. However, few studies have compared

the postoperative additional analgesic effects of lateral femoral cutaneous nerve block with LIA, combined with FNB after THA.

This prospective, randomized, open-label study aimed to determine whether lateral femoral cutaneous nerve block and LIA were effective analgesic adjuvants to FNB after THA.

2. MATERIALS AND METHODS

2.1 Patients

After registration with the University Hospital Medical Information Network (ID: UMIN000035841 on April 1, 2019), this prospective, randomized, open-label study was conducted at Nagasaki Rosai Hospital between April 2019 and May 2020.

2.2 Study protocol

This clinical trial included 50 American Society of Anesthesiologists physical status 1 or 2 patients weighing 50–70 kg who underwent THA by the posterior approach under general anesthesia. The patients received a continuous infusion of remifentanyl 0.5 µg/kg/min and propofol 5 µg/mL for 2 min followed by 3 µg/mL to achieve the desired effect-site concentration using a target-controlled infusion (TCI) system (TCI pump, TE-371, Terumo, Tokyo, Japan). Rocuronium (0.8 mg/kg) was administered to facilitate tracheal intubation after the loss of consciousness. The effect-site concentrations of propofol and remifentanyl were titrated to maintain a bispectral index score between 40 and 60 after tracheal intubation. All patients received ultrasound-guided FNB using 0.25% levobupivacaine 20 mL before the operation. Patients were randomly allocated to one of the following two groups: Group B (n=25), which received ultrasound-guided lateral femoral cutaneous nerve block with 0.25% levobupivacaine 20 mL after FNB; and Group I (n= 25), which received 0.25% levobupivacaine 20 mL over the incision line into the muscle, and the subcutaneous, and cutaneous tissue along the wound edge after the fascia closure. The ultrasound-guided lateral femoral cutaneous nerve was performed from the anterior superior iliac spine along the inguinal ligament by scanning laterally to medially. We identified lateral femoral cutaneous nerve between the fascia lata and iliaca. All patients received bolus administration of 250 µg fentanyl before skin closure⁸⁾ and 1000 mg intravenous

acetaminophen administration before the end of the operation, and at 6, 12, 18, and 24 h after the operation. The patients were administered a 50 mg diclofenac sodium suppository, as rescue analgesic after surgery when the patient requested analgesia. The nursing staff evaluated postoperative pain using a numerical rating scale (NRS; 10 points from 0 to 10) at 0, 1, 3, 6, 12, 18, and 24 h postoperatively. The NRS scores were evaluated immediately before analgesic drug injection at 6, 12, and 18 h.

2.3 Measurement

The primary outcome was the postoperative pain evaluated by the nursing staff using the NRS at 0, 1, 3, 6, 12, 18, and 24 h postoperatively. The secondary outcomes were the frequency of rescue analgesic use over 12 and 24 h, and the incidence of **postoperative nausea and vomiting (PONV)** during the 24 h after surgery.

2.4 Statistical Analysis

Values were expressed as medians (interquartile range). Intergroup comparisons were performed using Mann–Whitney U and chi-square tests. A factorial analysis of variance (ANOVA) with repeated measures was used to analyze the differences in NRS data among the time points and groups. Post hoc comparisons were performed using the Bonferroni/Dunn procedure, if appropriate. Statistical significance was defined as a p-value of <0.05.

The sample size was determined based on a previous study (standard deviation, 2.44)¹⁾, which indicated that a power of 80% would be required to detect a difference of 2 in NRS scores between the two groups at a 5% significance level if each group contained 24 patients.

3. RESULTS

Table 1 shows the patient characteristics for each group. The two groups showed no significant difference in patient characteristics, except for the operative time.

Table 1 Patients characteristics

	LFCNB group	LIA group	p
Patients (n)	25	25	
Age (years)	71 (63, 74)	70 (67, 88)	0.83
Height (cm)	151 (148, 160)	152 (147, 155)	0.66
Weight (kg)	60 (56, 64)	58 (54, 64)	0.35
BMI (kg/m ²)	25.6 (24.0, 27.2)	25.0 (23.1, 27.4)	0.48
Male gender	6	3	0.46
Anesthetic time (min)	192 (177, 201)	198 (192, 215)	0.17
Operative time (min)	108 (98, 120)	121 (111, 135)	0.04
Operative blood loss (g)	280 (255, 353)	280 (208, 458)	1.00

Values are median (interquartile range) or number. LFCNB, lateral femoral cutaneous nerve block; LIA, local infiltration anesthesia; BMI, body mass index; n, number;

The repeated-measures ANOVA revealed no significant differences in NRS scores between the two groups during the study period (Fig. 1). The NRS scores at 12, 18, and 24 h postoperatively were lower than that at 0 h in Group B. The NRS scores at 1 h postoperatively were higher than those at 0 h in Group I.

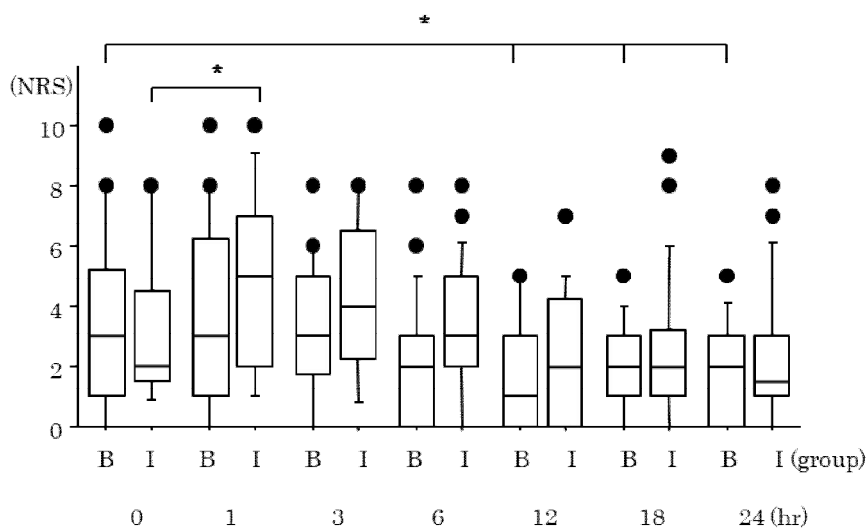


Fig.1. Numerical rating scale in group lateral femoral cutaneous nerve block (B) and LIA

(I) at each time point. Values are expressed as median (line inside the boxes), interquartile range (boxes), and 10-90percentiles (whiskers). B, lateral femoral cutaneous nerve block; I, LIA: local infiltration analgesia; NRS, numerical rating scale; *p < 0.05 vs. 0hr values.

No significant difference was noted in the frequency of rescue analgesics during the study period between the groups (Table 2). Moreover, no significant difference was found in the incidence of PONV between the groups (Table 2).

Table 2. Postoperative valuables

	LFCNB group	LIA group	p
PONV (n)	9	10	0.77
Rescue analgesics for 12 hr (n)	0 (0, 1)	0 (0, 1)	0.34
Rescue analgesics for 24 hr (n)	0 (0, 1)	0 (0, 1)	0.30

Values are median (interquartile range) or number. LFCNB, lateral femoral cutaneous nerve block; LIA, local infiltration anesthesia; n, number; PONV, postoperative nausea and vomiting;

4. DISCUSSION

No significant difference was observed in NRS scores and frequencies of rescue analgesia between the two groups. The results showed that lateral femoral cutaneous nerve block with FNB and LIA with FNB would have the equivalent adjunctive analgesic effect after THA.

“Superficially, femoral nerve and lateral femoral cutaneous nerve innervate the anterior and lateral thigh, which meets the need for hip surgery incision in most cases. In a deep layer, the hip joint is innervated by the articular branches of obturator, femoral, sciatic, and gluteal nerves,

so the FNB provided some analgesia for the hip”²⁾. Supplemental single shot FNB shows beneficial effects on postoperative management and recovery after THA⁶⁾. However, FNB is known not to cover the complete anatomic area for surgical exposure for THA.

“Although the analgesic effect of nerve blocks including FNB after THA is well established, the role of the lateral femoral cutaneous nerve block after THA is uncertain. The lateral femoral cutaneous nerve arises from the lumbar plexus”⁴⁾. “It has a highly variable course with innervation of the skin on the upper lateral or anterior part of the thigh. It has been suggested that lateral femoral cutaneous nerve block may not cover the full area of incision from THA in a large proportion of patients”⁹⁾. A study⁴⁾ showed that “lateral femoral cutaneous nerve block reduced movement-related pain in patients with pain after THA. However, the substantial non-responder rate limits the recommendation of this block as a standard analgesic treatment regimen”. “Moreover, the optimal volume for this block is yet to be determined. A lateral femoral cutaneous nerve block with an increased volume of ropivacaine from 8 to 16 mL did not result in greater coverage of posterior incision lines for THA; however, in a larger blocked sensory area”⁷⁾. It is theoretically possible that minimally invasive THA procedures utilizing smaller incisions could benefit more; however, this has yet to be investigated. We selected 20 mL of levobupivacaine for lateral femoral cutaneous nerve block after a minimally invasive THA procedure.

“Chronic pain developing after THA is a serious issue that can lead to life-altering morbidity. Risk factors for developing postoperative chronic pain include preoperative pain, poorly controlled acute postoperative pain, and intraoperative nerve damage”⁵⁾. “Because severe preoperative pain refractory to medical management is the indication for THA, it is important to focus on reducing the amount of acute postoperative pain. Traditionally, pain after THA has been managed with systemic opioids, nonsteroidal anti-inflammatories, and acetaminophen. Because some of these medications have significant adverse effects, peripheral nerve block and LIA for postoperative pain after THA is attracting attention. These regional analgesia techniques reduced postoperative pain, morphine consumption, and nausea and vomiting”¹⁾.

“In contrast to LIA for total knee arthroplasty, the efficacy of LIA for analgesia after THA is not widely accepted”¹⁰⁾. However, some studies provided supportive evidence for the analgesic effectiveness of LIA after THA¹⁰⁾. “In a recent meta-analysis, no difference was observed between

LIA and peripheral nerve blocks in terms of opioid consumption and pain intensity”¹¹⁾. Therefore, LIA may have a good probability of efficacy for patient outcomes. Single injection LIA had an analgesic effect with no side-effects¹²⁾. Therefore, PROSPECT guideline¹²⁾ recommended LIA, especially if there were contra-indications to basic analgesics and/or in patients with high expected postoperative pain. Moreover, the optimal volume for LIA is yet to be determined. The dose of levobupivacaine was lesser than those of other studies^{13,14)}. We selected 20 mL of levobupivacaine for LIA for comparison to lateral femoral cutaneous nerve block after a minimally invasive THA procedure.

A limitation of this study is that because the study was not blinded, bias by the nurses was possible. However, since more than 24 nurses were randomly involved in the care of each patient in the ward during the study period, the likelihood of bias was extremely low¹⁵⁾. Second limitation is that because the study did not have control patients without any nerve blocks including femoral nerve block. However, the patients without any nerve block would feel severe pain because FNB have some analgesia after THA²⁾.

5. CONCLUSION

The lateral femoral cutaneous nerve is a sensory branch from the lumbar plexus and supplies parts of the lateral and anterior upper thigh. Lateral femoral cutaneous nerve block seeks to remove wound pain after THA. Based on the findings of this study, It is concluded that both lateral femoral cutaneous nerve block and LIA with FNB would have the equivalent adjunctive analgesic effect after THA.

Acknowledgement

This research was supported by research funds to promote the hospital functions of the Japan Organization of Occupational Health and Safety.

Competing interests

The authors declare that they have no competing interests.

Authors' contributions

Ayako Shimasaki and Yoshiaki Terao carried out all parts of this study. Yuya Komatsu, Yusuke Kasai, Natsuko Oji and Makito Oji, Hiroshi Aoki collected the clinical data. Testuya Hara revised the presentation and the manuscript. All authors read and approved the final manuscript.

Ethical Approval and Consent

The study was approved by the Institutional Research and Ethics Committee of Nagasaki Rosai Hospital on January 16, 2019 (No. 30014). Written informed consent was obtained from all participants.

Abbreviations

THA: total hip arthroplasty; LIA: local infiltration analgesia; FNB: femoral nerve block; NRS: numerical rating scale; PONV: postoperative nausea and vomiting; TCI: target-controlled infusion; ANOVA: A factorial analysis of variance; ASA: American Society of Anesthesiologists;

References

- 1) Vandebroek A, Vertommen M, Huyghe M, Van House P. Ultrasound guided femoral nerve block and lateral femoral cutaneous nerve block for postoperative pain control after primary hip arthroplasty: a retrospective study. *Acta Anaesth belg.* 2014; 65 (1): 39-44. [PMID: 24988826]
- 2) Zhang Q, Ling M, Wang X, Cui D. A comparison of two peripheral nerve blocks combined with general anesthesia in elderly patients undergoing arthroplasty for hip fractures: a pilot randomized controlled trial. *Front Surg.* 2022; 9: 715422. [DOI: 10.3389/fsurg2022]
- 3) Thybo KH, Schmidt H, Hage-Pedersen D. Effect of lateral femoral cutaneous nerve-block on pain after total hip arthroplasty: a randomised, blinded, placebo-controlled trial. *BMC*

- Anesthesiology. 2016; 16: 21. [PMID: 27006014 DOI: 10.1186/s12871-016-0183-4]
- 4) Thybo KH, Mathiesen O, Dahl JB, Schmidt H, Hagi-Pedersen. Lateral femoral cutaneous nerve block after total hip arthroplasty: a randomized trial. *Acta Anaesth Scand*. 2016; 60 (9); 1297-305. [PMID: 27426231 DOI: 10.1111/aas.12764]
 - 5) Li J, Dai F, Ona Ayala KE, Zhou B, Schonberger RB, Sharma A. Transmuscular quadratus lumborum and lateral femoral cutaneous nerve block in total hip arthroplasty. *Clin J Pain*. 2021; 37 (5): 366-371. [PMID: 27006014 DOI: 10.1097/AJP.0000000000000923]
 - 6) Wiesmann, Steinfeldt T, Wagner G, Wulf H, Schmitt J, Zoremba. Supplemental single shot femoral nerve block for total hip arthroplasty: impact on early postoperative care, psin management and lung function. *Minerva Anestesiol* 2014; 80 (1): 48-57. [PMID: 23877305]
 - 7) Vilhelmsen F, Nersesjan M, Andersen JH, Danker JK, Broeng L, Hage-Pedersen D, et al. Lateral femoral cutaneous nerve block with different volumes of ropivacaine: a randomized trial in healthy volunteers. *BMC Anesthesiology*. 2019; 19: 165. [PMID: 31455249 DOI: 10.1186/s12871-019-0133-4]
 - 8) Kasai Y, Terao Y, Shimazaki A, Ono M, Oji N, Oji M, et al. Comparison of the effect of intravenous acetaminophen and flurbiprofen on postoperative pain after total knee arthroplasty: A randomized controlled trial. *J Anest Intens Care*. 2020; 1: 1-5.
 - 9) Davies A, Crossley AP, Harper MW, O' loughlin EJ. Lateral cutaneous femoral nerve blockade-limited skin incision coverage in hip arthroplasty. *Anaesth Intensive Care*. 2014; 42: 625-30. [PMID: 25233177].
 - 10) Bugada D, Bellini V, LoriniLF, Mariano ER. Update on selective regional analgesia for hip surgery patients. *Anesthesiology Clin*. 2018; 36: 403-15. [PMID: 30092937 DOI: 10.1016/j.anclin.2018.04.001]
 - 11) Jimenes-Almonte JH, Wyles CC, Wyles SP, Norambuena-Morales GA, Baez PJ, Murad MH, et al. Is local infiltration analgesia superior to peripheral nerve blockade for pain management after THA: a network meta-analysis. *Clin Orthop Relat Res*. 2016: 474; 495-516. [PMID: 26573322 DOI: 10.1007/s11999-015-4619-9]
 - 12) Anger M, Valovska T, Beloeil H, Lirk P, Joshi GP, Van de velde M, et al. PROSPECT guideline

for total hip arthroplasty: a systematic review and procedure-specific postoperative pain management recommendations. *Anaesthesia*. 2021; 76; 1082-97. [PMID:34015859 DOI: 10.1111/anae.15489]

- 13) Kuchalik J, Magnuson A, Lundin A, Gupta A. Local infiltration analgesia or femoral nerve block for postoperative pain management in patients undergoing total hip arthroplasty. A randomized, double-blind study. *Scand J Pain*. 2017; 16; 223-30. [PMID: 28850408 DOI: 10.1016/j.sjpain.2017.05.002]
- 14) Sandri M, Blasi A, De Blasi RA. PENG block and LIA as a possible anesthesia technique for total hip arthroplasty. *J Anesth*. 2020; 34; 472-5. [PMID: 3223266 DOI: 10.1007/s00540-020-02768-w]
- 15) Saito M, Terao Y, Fukusaki M, Makita T, Shibata O, Sumikawa K. Sequential use of midazolam and propofol for long-term sedation in postoperative mechanically ventilated patients. *Anesth Analg* 2003; 96 (3): 834-8. [PMID: 12598270]