

Updates in the Role of MRI in Diagnosis of Lumbar Disc Herniation: A Systematic review article

Abstract

Background: Magnetic resonance imaging (MRI) is the technique of choice for diagnosing lumbar disc herniation (LDH). This systematic review aims to investigate the recently published literature regarding the updates of MRI for LDH diagnosis. **Methodology:** PubMed, Web of Science, Science Direct, EBSCO, and Cochrane library were searched. Study articles were screened by title and abstract using Rayyan QCRI then a full-text assessment was implemented. **Results:** Nine studies were included, with 1064 patients with LDH. All the included studies reported that MRI is valuable in diagnosing and detecting the acuity of LDH. Other diagnostic modalities were used along with MRI to increase the results' accuracy, including the clinical findings, MRM, and QST. **Conclusion:** MRI is considered suitable for predicting symptom severity in patients with LDH and, when used in combination with clinical findings, improves diagnostic accuracy. This review showed that deep learning can be used on small data sets containing only a few medical images. Impressive results were obtained in terms of detection of findings and improved accuracy of LDH diagnosis. Electrophysiological studies, QST, weight bearing, and MRM have been used as diagnostic methods for his LDH along with MRI, with good and accurate results reported.

Keywords: Diagnosis, Lumbar disc herniation, Magnetic resonance imaging, Role of MRI, Systematic review.

Introduction

Lumbar disc herniation (LDH) is a frequent degenerative finding in patients with low back pain (LBP), defined by the displacement of disc material outside the disc space's normal borders [1]. LDH is a common condition treated in clinics that results from a sedentary lifestyle and lumbar intervertebral disc degeneration with aging, both of which increase the risk of

intervertebral disc annulus fibrosis injury from compression, which causes the nucleus pulposus to protrude into the spinal canal. The patient's quality of life will be significantly impacted if the bulging nucleus pulposus compresses the dural sac or nerve roots and causes pain in the back and legs [2, 3].

According to some statistics, 70–80% of adults have lower back [4]. As if this high prevalence was not enough, there may be even more pathological findings. A study revealed that MRI was used to assess 98 asymptomatic people. Many of these asymptomatic participants had abnormal discs in their Magnetic resonance imaging (MRI), 52% had bulging discs, and 38% had multiple defective intervertebral discs [5]. According to another study, 90% of asymptomatic individuals with lumbar disc herniation at the Lumbar 4 (L4)-Lumbar 5 (L5) and L5-Sacral 1 (S1) vertebrae show aberrant MRI scan results [6].

Clinically, there are still significant discrepancies in how LDH disease is categorized and how it is treated, and there is no set global standard. The results of the assessment are significantly influenced by the doctor's subjective assessment because, in the majority of situations, the severity of LDH disease is still assessed largely on the individual experiences of doctors. The LDH can now be examined using either MRI or Computerized Tomography (CT) equipment; however, MRI is preferable to CT for determining whether the spinal cord, dural sac, or nerve roots are compressed [7]. According to studies, using an MRI to test for LDH has a sensitivity of more than 94%, a specificity of more than 60%, and an accuracy of more than 90% [8].

The imaging evaluation should include radiography because it is common and affordable, and MRI should be used as the primary examination technique. According to their shape, hernias are categorized on MRI, as illustrated in the following condensed morphological description. Protrusion, extrusion, or sequestration are three possible shapes for the disc material, which primarily originates from the pulposus nucleus and is displaced beyond the intervertebral limits [9].

Study objectives:

This systematic review investigates the recently published literature regarding the updates of MRI for LDH diagnosis.

Methodology

The established guidelines were followed in conducting this systematic review (Preferred Reporting Items for Systematic Reviews and Meta-Analyses, PRISMA).

Study Design

This was a systematic Review.

Study condition

This review investigates recently published literature regarding the updates of MRI for LDH diagnosis.

Search strategy

A thorough literature search was conducted in five major databases, including PubMed, Web of Science, Science Direct, EBSCO, and Cochrane Library, to discover the pertinent material. Our search was limited to English and each database's specific requirements were taken into account. The right studies were located using the following keywords, which were transformed into Mesh terms in PubMed; "Lumbar disc herniation," "LDH," "Herniated lumbar disc," "diagnosis," "detection," "magnetic resonance imaging," and "MRI." The "OR" and "AND" Boolean operators were combined with the relevant keywords. English, full-text publications, freely accessible articles, and human trials were all included in the search results.

Selection criteria

Inclusion criteria

The subjects were chosen for addition founded on their applicability to the research, which has the following criteria; patients with LDH who underwent MRI diagnosis. The authors restricted their search to the literature published in the last 5 years.

Exclusion criteria

All further papers, ongoing studies, and reviews of existing studies that did not have one of these themes as their main objective were excluded.

Data extraction

We used Rayyan (QCRI) [10] to detect the duplicates of the search strategy outcomes. By limiting the combined search results based on a set of inclusion/exclusion criteria, the researchers assessed the relevance of the titles and abstracts. The entire texts of the papers that met the criteria for inclusion were evaluated by the reviewers. The authors addressed how to resolve any disagreements. The qualified study was included using a data extraction form that was created. The authors extracted data about the study titles, authors, study year, study design, participant number, gender, diagnostic method, and main findings.

Risk of bias assessment

The qualitative data synthesis used the non-randomized studies ROBINS-I technique [11] to assess the quality of the included research. The reviewers investigated and fixed any irregularities in the quality assessment.

Strategy for data synthesis

To provide a qualitative overview of the included study components and results, summary tables containing the data gathered from the eligible studies were created. After the systematic review's data extraction process was finished, decisions were made about how to best utilize the data from the included study articles. Studies that met the full-text inclusion criteria but did not provide any diagnostic information on patients with LDH were excluded.

Results

Search results

A total of 450 study articles resulted from the systematic search, and then 57 duplicates were removed. Title and abstract screening were conducted on 393 studies, and 301 studies were excluded. 92 reports were sought for retrieval, and only 10 articles were not retrieved. Finally, 82 studies were screened for full-text assessment; 52 were excluded for wrong study outcomes, 10 for unavailable data on LDH, and 11 for the wrong population type. Nine articles were included in this systematic review. A summary of the process of study selection is presented in **Figure 1**.

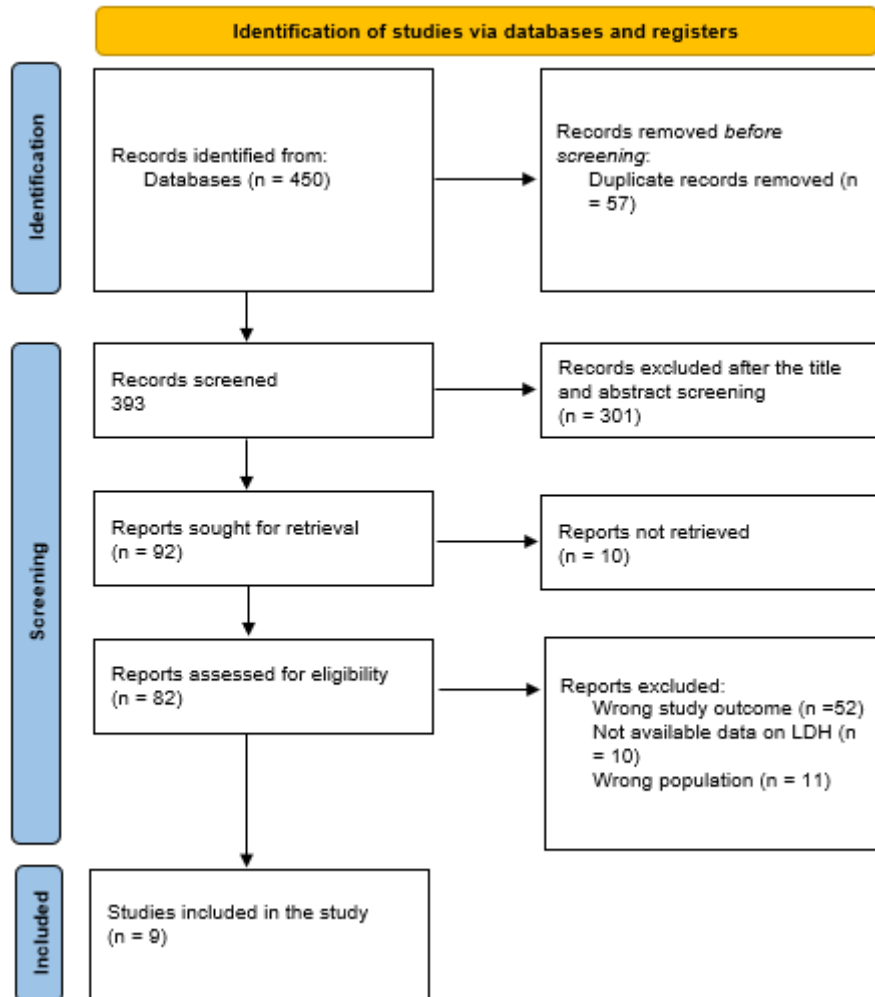


Figure (1): PRISMA flowchart summarizes the study selection process

Characteristics of the included studies

A total of 9 studies were included in this review, with 1064 patients with LDH. Four studies were conducted in China [14, 15, 18, 19], one in India [12], one in Japan [13], one in Turkey [16], one in Denmark [17], and one in the USA [20]. Regarding the studies' designs, three studies were prospective studies [12, 13, 19], three were retrospective studies [14, 15, 20], one was a

cross-sectional study [17], and one was a case-control study [18]. All the included studies reported that MRI is valuable in diagnosing and detecting the acuity of LDH. MRI as the only diagnostic method was used in two studies [12, 20], and another two studies used MRI based on deep learning [15, 19]. Other studies used MRI along with electrophysiological studies [13], MRI after nonrigid fixation system and posterior lumbar interbody fusion [14], MRI and quantitative sensorial tests (QST) [16], weight-bearing MRI [17], and MRI along with Magnetic resonance myelography (MRM) [18].

UNDER PEER REVIEW

Table (1): A summary of characteristics of the included study articles.

Study	Study design	Country	Total Participants	Male (%)	Diagnostic method	Key findings	ROBINS-I
Saini et al., 2022 [12]	Prospective observational study	India	201	97 (48.2)	MRI	MRI is a useful tool for identifying LDH. The clinical and radiological correlation of MRI should be adopted by doctors to increase diagnostic accuracy. Professionals can use reporting to help them decide whether to pursue conservative or surgical management as the best course of action.	Moderate
Zhong et al., 2017 [13]	Prospective observational study	Japan	265	138 (52.1)	MRI, along with electrophysiological studies	For the diagnosis of lumbar disc herniation, as well as for the surgical plan and assessment of the clinical outcome of the surgery, MRI and electrophysiological studies are valuable	High
Yang et al., 2018 [14]	Retrospective study	China	112	30 (26.8)	MRI after nonrigid fixation system and posterior lumbar interbody fusion	A novel, quantitative way of analysis that significantly aids in the identification of severe intervertebral disc degeneration is the MRI examination of the lumbar nucleus pulposus volume.	Moderate
Tsai et al., 2021 [15]	Retrospective study	China	168	168 (100)	MRI based on deep learning	Deep learning can be used with a short dataset that contains few medical images. Using data augmentation, they increased the LDH pictures deep learning feature using the image processing technique. Impressive LDH area detection findings were obtained using YOLOv3.	High
Erbüyük et al., 2018 [16]		Turkey	56	29 (51.7)	MRI and QST	In patients with lumbar discs, QST procedures offer an additional effect for nerve root compression evaluation to MRI, which may enable more accurate diagnostic and treatment protocols. The diagnostic capability of QST can also be an additional tool for assessing nerve root compression in patients whose imaging and clinical symptoms do not match.	Moderate
Nordberg et al., 2021 [17]	Cross-sectional	Denmark	52	34 (56.4)	Weight-bearing MRI	The diagnostic sensitivity of disc herniations, including LDH in individuals suspected of nerve root compression, may be improved by weight-bearing MRI.	Moderate
Jiang et al., 2022 [18]	Case-control study	China	96	55 (57.3)	MRI and MRM	The MRI + MRM group showed nerve root morphology, sheath sleeve deformation, and dural indentation better than the MRI group, which implies better diagnostic and prognostic value.	High
Chen et al., 2021 [19]	Prospective observational study	China	25	11 (44)	MRI based on deep learning	It was suggested that increasing the accuracy of the diagnosis of LDH might be accomplished by incorporating the CDCGAN model into the assisted diagnosis system for LDH based on MRI quantitative markers.	Moderate
Divi et al., 2021 [20]	Retrospective study	USA	89	48 (53.9)	MRI	MRI signal characteristics are a good predictor of the acuity of symptoms in patients with LDH	Moderate

Discussion

Many previous published evidence-based literature demonstrated the benefits of radiological investigation in LDH diagnosis, especially MRI. This systematic review focused on the recently published literature to detect the updated uses of MRI in LDH diagnosis.

Two of the studies we included used MRI only for diagnosis. They reported that MRI, along with the clinical findings, increases diagnostic accuracy and was defined as a good predictor of the acuity of symptoms in patients with LDH [12, 20]. Many studies have reported that MRI is the preferred technique for examination. Axial computed tomography is still widely used in Brazil, but even though it can detect disc herniation, it falls short of MRI in terms of both quality and sensitivity. MRI is a crucial test for accurately assessing patients because of the comprehensive information on bone and soft tissue that it provides. This information may aid in making therapeutic recommendations as well as making the right diagnosis [9].

Our review included two studies that used MRI based on deep learning for LDH diagnosis. They reported impressive results regarding the findings' detection and increasing the accuracy of LDH diagnosis [15, 19]. This demonstrates that deep learning can be used with a small dataset that comprises few medical images. The production of enormous amounts of medical imaging data as a result of the quick advancement of imaging technology has added to doctors' workloads in terms of disease diagnosis. Deep learning has made it possible for this technology to recognize and classify similar features in medical image data, making it easier to diagnose illnesses [21].

Other studies used electrophysiological studies [13], QST [16], weight-bearing [17], and MRM [18] along with MRI as a diagnostic method for LDH and reported good accurate results. The nerves' running course and compression can be seen clearly on MRM images because the spinal cord and its nerve roots are both infiltrated by CSF. After percutaneous transforaminal endoscopic discectomy (PTED), the patient's normal physiological and anatomical structure is somewhat disorganized as a result of the procedure, and MRI scans are interrupted and have thick scanning layers. Consequently, it is challenging to see the entire spinal nerve root deviation on MRI, which influences physicians' assessments of postoperative nerve root decompression. Contrast agents, however, come with a risk of allergy and the potential to cause some trauma to patients when used for observation [22].

The true nature of disc herniation can be revealed through weight-bearing. Studies conducted in clinical settings that reported finding disc herniation during weight-bearing MRI while standing provide support for this. Because of this, weight-bearing MRI may improve the diagnostic specificity of disc herniations in patients suspected of compressing the nerve root or radiculopathy [23, 24].

As a result of the high prevalence of abnormal anatomical findings in asymptomatic patients, authors of several studies have demonstrated that MRI may lack specificity. Therefore, a causal relationship between clinical findings and diagnostic imaging results is required for a correct diagnosis [25, 26].

Conclusion

MRI was regarded to be a good predictor of the severity of symptoms in LDH patients and increases diagnostic accuracy when used in combination with clinical findings. This review demonstrated that deep learning could be used with a small dataset that comprises few medical images. Impressive results were obtained in terms of detecting the findings and improving LDH diagnosis precision. Electrophysiological studies, QST, weight-bearing, and MRM were used along with MRI as a diagnostic method for LDH and reported good accurate results.

Acknowledgments:

Many thanks to for all colleges who helped us in the study preparation and writing, continues support and encouragement to complete this work.

Conflict of Interest: None

Financial Support: None

Ethics Statement:None

References

1. Fardon, D. F., Williams, A. L., Dohring, E. J., Murtagh, F. R., Rothman, S. L. G., & Sze, G. K. (2014). Lumbar disc nomenclature: version 2.0: Recommendations of the combined task forces of the North American Spine Society, the American Society of Spine Radiology and the American Society of Neuroradiology. *The spine journal*, *14*(11), 2525-2545.
2. Alhazmi, R., Farmer, J. P., & Saint-Martin, C. (2017). Magnetic resonance myelography in congenital absence of the cervical pedicle. *Canadian Journal of Neurological Sciences*, *44*(3), 329-331.
3. Hu, X. X., & Liu, L. M. (2015). Progress on the cause and mechanism of a separation of clinical symptoms and signs and imaging features in lumbar disk herniation. *Zhongguogu Shang= China Journal of Orthopaedics and Traumatology*, *28*(10), 970-975.
4. Paolucci, T., Attanasi, C., Cecchini, W., Marazzi, A., Capobianco, S. V., & Santilli, V. (2019). Chronic low back pain and postural rehabilitation exercise: a literature review. *Journal of pain research*, *12*, 95.
5. Jensen, M. C., Brant-Zawadzki, M. N., Obuchowski, N., Modic, M. T., Malkasian, D., & Ross, J. S. (1994). Magnetic resonance imaging of the lumbar spine in people without back pain. *New England Journal of Medicine*, *331*(2), 69-73.
6. Faur, C., Patrascu, J. M., Haragus, H., & Anglitoiu, B. (2019). Correlation between multifidus fatty atrophy and lumbar disc degeneration in low back pain. *BMC musculoskeletal disorders*, *20*(1), 1-6.21111
7. Divi, S., Warner, E. D., Makanji, H., Goyal, D. K., Galetta, M. S., Fang, T., ... & Schroeder, G. D. (2019). 205. Can imaging characteristics on MRI predict the acuity of a lumbar disc herniation?. *The Spine Journal*, *19*(9), S99.
8. Ziegler, D. S., Carreon, L., Andersen, M. O., & Jensen, R. K. (2019). The association between preoperative MRI findings and surgical revision within three years after surgery for lumbar disc herniation. *Spine*, *44*(11), 818-825.
9. Vialle, L. R., Vialle, E. N., Henao, J. E. S., & Giraldo, G. (2010). Lumbar disc herniation. *Revista Brasileira de Ortopedia (English Edition)*, *45*(1), 17-22.
10. Ouzzani M, Hammady H, Fedorowicz Z, Elmagarmid A. Rayyan—a web and mobile app for systematic reviews. *Systematic reviews*. 2016 Dec;*5*(1):1-0.
11. Jüni P, Loke Y, Pigott T, Ramsay C, Regidor D, Rothstein H, Sandhu L, Santaguida PL, Schünemann HJ, Shea B. Risk of bias in non-randomized studies of interventions (ROBINS-I): detailed guidance. *Br Med J*. 2016.
12. Saini, R., Sharma, A., & Dave, M. B. (2022). Clinical Reporting of Magnetic Resonance Imaging, the Way Forward for Patients With Lumbar Disc Herniation: A Prospective Correlational Study. *Cureus*, *14*(7).
13. Zhong, W., Wang, J., Zhang, W., Liu, P., Visocchi, M., & Li, S. T. (2017). Combination of magnetic resonance imaging and electrophysiological studies in lumbar disc herniation. *Trends in Reconstructive Neurosurgery*, *271-275*.

14. Yang, S., Liu, Y., Bao, Z., Zou, J., & Yang, H. (2018). Comparison of adjacent segment degeneration after nonrigid fixation system and posterior lumbar interbody fusion for single-level lumbar disc herniation: A new method of mri analysis of lumbar nucleus pulposus volume. *Journal of Investigative Surgery*, 31(4), 307-312.
15. Tsai, J. Y., Hung, I. Y. J., Guo, Y. L., Jan, Y. K., Lin, C. Y., Shih, T. T. F., ... & Lung, C. W. (2021). Lumbar disc herniation automatic detection in magnetic resonance imaging based on deep learning. *Frontiers in Bioengineering and Biotechnology*, 691.
16. Erbüyün, S. C., Ovalı, G. Y., Özyurt, B., & Yentür, E. A. (2018). Lumbar disc herniation, the association between quantitative sensorial test and magnetic resonance imaging findings. *Pain Medicine*, 19(7), 1373-1381.
17. Nordberg, C. L., Boesen, M., Fournier, G. L., Bliddal, H., Hansen, P., & Hansen, B. B. (2021). Positional changes in lumbar disc herniation during standing or lumbar extension: a cross-sectional weight-bearing MRI study. *European Radiology*, 31(2), 804-812.
18. Jiang, Y., Zuo, R., Yuan, S., Li, J., Liu, C., Zhang, J., ... & Hai, Y. (2022). Prognosis Evaluation of MRI Combined with Magnetic Resonance Myelography on Lumbar Disc Herniation after Transforaminal Endoscopic Discectomy. *Computational and mathematical methods in medicine*, 2022.
19. Chen, G., & Xu, Z. (2021). Usage of intelligent medical aided diagnosis system under the deep convolutional neural network in lumbar disc herniation. *Applied Soft Computing*, 111, 107674.
20. Divi, S. N., Goyal, D. K., Mankanji, H. S., Kepler, C. K., Anderson, D. G., Warner, E. D., ... & Schroeder, G. D. (2021). Can Imaging Characteristics on Magnetic Resonance Imaging Predict the Acuity of a Lumbar Disc Herniation?. *International Journal of Spine Surgery*, 15(3), 458-465.
21. Moen, E., Bannon, D., Kudo, T., Graf, W., Covert, M., & Van Valen, D. (2019). Deep learning for cellular image analysis. *Nature methods*, 16(12), 1233-1246.
22. Yoon, S. J., & Kim, J. G. (2016). Magnetic resonance myelography in a patient with intracranial hypotension. *European Neurology*, 76(3-4), 151-151.
23. Perez, A. F., Isidro, M. G., Ayerbe, E., Castedo, J., & Jinkins, J. R. (2007). Evaluation of intervertebral disc herniation and hypermobile intersegmental instability in symptomatic adult patients undergoing recumbent and upright MRI of the cervical or lumbosacral spines. *European journal of radiology*, 62(3), 444-448.
24. Splendiani, A., Perri, M., Grattacaso, G., Di Tunno, V., Marsecano, C., Panebianco, L., ... & Gallucci, M. (2016). Magnetic resonance imaging (MRI) of the lumbar spine with dedicated G-scan machine in the

upright position: a retrospective study and our experience in 10 years with 4305 patients. *La radiologiamedica*, 121(1), 38-44.

25. Jensen, M. C., Brant-Zawadzki, M. N., Obuchowski, N., Modic, M. T., Malkasian, D., & Ross, J. S. (1994). Magnetic resonance imaging of the lumbar spine in people without back pain. *New England Journal of Medicine*, 331(2), 69-73.
26. Jarvik, J. J., Hollingworth, W., Heagerty, P., Haynor, D. R., & Deyo, R. A. (2001). The longitudinal assessment of imaging and disability of the back (LAIDBack) study: baseline data. *Spine*, 26(10), 1158-1166.

UNDER PEER REVIEW