

Magnetic resonance imaging (MRI) of the knee in post Meniscal repair and Meniscectomy

Abstract

Background: The best imaging technique for post-operative knee assessment is magnetic resonance imaging (MRI). The challenge of using MRI to diagnose problems in the knee is made more challenging by surgical alterations. Therefore, reliable MRI assessment depends on the ability to distinguish between the normal post-operative MRI image of the knee elements and their anomalies. The purpose of this research was to compare the clinical result with the use of MRI to identify predicted morphological changes in the knee menisci during the first two years after arthroscopic operation.

Methods: This cross-sectional study was carried out on 30 patients with previously undergone meniscal repaired or meniscectomy and reported having ongoing or frequent knee discomfort. All patients had extensive clinical examinations and detailed history collection, radiographical imaging and MRI.

Results: MRI examination of the knee post operatively showed that the time needed for beginning of meniscus healing after surgery ranged from 3-6months. 27 patients (90%) had a meniscus tear in the posterior 1/3. Degenerative tears 11 (36.4%) was the most prevalent meniscal tears pattern diagnosed by MRI. No effusion occurred in 25 (83.3%) patients. Thirty cases were treated; seventeen received arthroscopic repair, and thirteen underwent resection. 11 patients (36.6%) had symptoms ranging from joint swelling or pain, restricted motion, instability/giving away, and catching/locking, whereas 19 (63.4%) were asymptomatic.

Conclusions: Within the first two years after arthroscopic operations, MRI plays a useful role in detecting anticipated morphological alterations of the knee menisci.

Keywords: MRI, Meniscal Repair, Meniscectomy, Arthroscopic Intervention, Knee Tear.

UNDER PEER REVIEW

Introduction

A typical radiological method for diagnosing or examining the knee joint is magnetic resonance imaging (MRI), which makes use of numerous sequences in different planes. The most frequently employed sequences in coronal and sagittal planes are T2-weighted and proton density (PD)-weighted. These sequences are very susceptible to myxoid oedema and degeneration, which may take place after meniscal injuries. As a result, MRI is often regarded as a very accurate imaging technique to detect meniscal lesions ^[1].

There are several potential causes of knee joint pain, including degeneration and trauma, which may have an immediate impact on the meniscus. The nitrification of articular cartilage, load transfer, shock absorption, and lubrication are all crucial functions of the meniscus ^[2].

The meniscus's wedge shape performs various and intricate roles by supporting the femoral condyle in its junction with the tibial plateau's flat surface ^[2]. There are a number of pressures, including compression and shear tension, which may result in or contribute to meniscal tears. When shear stresses arise between the interior collagen fibres, the meniscus is liable to deform. In addition, following meniscus deterioration, direct trauma may result in meniscal tears. In patients who are overweight, the knee may degenerate, particularly if the patient does not participate in healthy knee mobility ^[3].

A meniscal tear may happen on its own or in conjunction with other proximal injuries, such those of the collateral ligaments and anterior cruciate ligament (ACL). Discoid meniscus, a rare congenital defect in which the crescent-shaped meniscus is enlarged, increases the chance of developing a tear. Meniscal degeneration may coexist with patella degeneration, a condition called chondromalacia patellae ^[3].

The purpose of this research was to compare the clinical result with the use of MRI to identify predicted morphological changes in the knee menisci during the first two years after arthroscopic operation.

Patients and Methods

This prospective study was carried out on 30 patients who had previously undergone meniscal repaired or meniscectomy and exhibited ongoing or recurring knee discomfort or pain and referred to radio-diagnosis department at Tanta university hospital.

This research was done after being approved from the Research Ethical Committee, Faculty of Medicine, Tanta University. All included participants provided written permission after being fully informed.

Exclusion criteria were the presence of heart pacemaker or extreme claustrophobia, obstinate individuals with excessive mobility, any electrically or magnetically activated implants (cochlear implants), an aneurysm clip in their brain, a metallic foreign body in their eye, bad general conditions, absent operative or post-operative data, poor quality of the MRI due to patient motion or device artifact and patient presented for follow up after longer period post-operative (more than 2 years).

All patients had extensive clinical examinations and detailed history collection, radiographical imaging and MRI.

Conventional MRI Interpretation:

Image acquisition: A 1.5 T MRI scanner (GE SIGNA Explorer) was used to image the knees utilising a special knee coil. The patient is placed in a supine posture, with their feet in front (The head is not in the magnet). About a 15-degree external rotation is present at the extremities. The knee coil houses the afflicted extremity.

Pulse sequences: Fast spin echo (FSE) pictures with sagittal T1 weighting with repetition and echo times (RT and ET) of 600 ms and 15 ms, respectively. T2 weighted axial and sagittal

FSE pictures (with TR 4000 ms and TE 90 ms). PD-weighted sagittal images (with TR over 2000 ms and TE 10-20 ms). The best pictures for spotting meniscal tears are coronal and sagittal PD weighted films with fat suppression [with TR \geq 4000 ms and TE 30 ms]. T2 weighted pictures of the coronal and sagittal planes, with fat suppression (with TR over 3000 ms and TE 80 ms). Images that are weighted by coronal T2 Short Time Inversion Recovery (STIR) (with TR over 4000 ms and TE 120 ms).

Images that are weighted by coronal T2 Short Time Inversion Recovery (STIR) (with TR over 4000 ms and TE 120 ms). Meniscal windows: Using this technique, an area of interest focused on the meniscus is magnified 1.5–2 times. It uses a window level of around 1000 and a window width of 100 to 150. Each sequence used a 4.0 mm thick slice.

Image interpretation:

The following was determined from both the amended pre- and post-operative MR images: Meniscal body size and structure in sagittal and coronal T1-weighted or PD FSE images, with or without fat suppression. Meniscal abnormalities with intra-substance signal on sagittal PD FSE images. T2-weighted images with or without suppression, or images with PD fat suppression, show fluid signal inside the menisci that indicates a re-tear. Axial T2-weighted pictures are useful in situations with meniscal root tears. Coronal T2-weighted STIR images are the best for capturing associated bone marrow oedema. Additional findings included cysts, concurrent ACL reconstruction in various sequences and planes, and the quantity of fluid in the knee joint (rated as normal, minimum, mild, moderate, or severe effusion). Artifacts from the metallic fixation devices. Contrast material entering the cleft on T1-weight fat-suppressed MR arthrography, sagittal and coronal images is the sign validating the suspicion of a meniscus re-tear.

Statistical analysis

The SPSS v25 statistical analysis programme was used (IBM Inc., Chicago, IL, USA). Frequency and percentages (%) were used to display the qualitative variables. Significant results were defined as two tailed P values of less than 0.05.

Results:

Patient’ characteristics and the MRI examination of the knee post operatively showed that the time needed for beginning of meniscus healing after surgery ranged from 3-6 months.as illustrated in **Table 1**.

Table 1: Patient’ characteristics and MRI consequence among the studied patients (n = 30)

		N = 30
Age groups	10 _ 20 years	2 (12%)
	21 _ 30 years	7 (22%)
	31 _ 40 years	13 (42%)
	41 _ 60 years	8 (24%)
Sex	Male n (%)	20(66.6%)
	Female n (%)	10 (33.4%)
Time between operation and MRI	3- 6 months	Partial healing 10 (33.3%)
	6 – 12 months	Complete healing 15 (50%)
	12 -18 months	New meniscus forme d4(13.4%)
	18 months with complain of pain	A new tear1 (3.3%)

Data are presented as frequency and percentage (%).

Among the 30 patients, the tear was found in the posterior 1/3 in 27 (90%) patients, the anterior 1/3 in 2 (6.6%) patients, the middle 1/3 in 1 (3.4%) patient, and the posterior 1/3 in 2 (6.6%) patients. **Table 2** provides an illustration of the previous three pre-operative data.

Table 2: The location of each tear inside the injured meniscus

Site	Medial meniscus(n=27)			Lateral meniscus(n=3)		
	Anterior1/3	Middlle1/3	Posterior1/3	Anterior1/3	Middle1/3	Posterior1/3
Number	1(3.3%)	1(3.3%)	25(83.5%)	1(3.3%)	0	2(6.6%)
Traumatic injury	1(3.3%)	1(3.3%)	16(53.5%)	1(3.3%)	0	2(6.6%)
Non traumatic	0	0	9(30%)	0	0	0

Data are presented as frequency and percentage (%).

Patterns of meniscal tears as diagnosed by MRI and are recorded as illustrated in **Table 3**.

Table 3: Distribution of tear patterns among the patients.

Tear patterns	Number of patients (Percentage)
Bucket-handle tears	3 (10%)
Degenerative tears	11 (36.4%)
Complex tears	3 (10%)
vertical tears	1 (3.4%)
Horizontal tear	9 (30%)
root tears	1 (3.4%)
Torn discoid meniscus	1 (3.4%)
Radial lesion	1 (3.4%)

Data are presented as frequency and percentage (%).

Associated findings either pre-operative, during arthroscopy, osteoarthritic changes and arthroscopic intervention totally. Out of the 30 patients, 17 patients received arthroscopic repair, and 13 patients underwent resection, as shown in **Table 4**.

Table 4: Associated discoveries made before surgery, during arthroscopy, or after surgery, osteoarthritic changes and distribution of the arthroscopic intervention

	N (%)
Synovial effusion	5 (16.6%)
No effusion	25(83.3%)
Synovitis	1(3.3%)
ACL affection	3 (10%)
Osteoarthritic (OA) changes	
No OA changes	18 (60%)
Pre- and post-operative grade I or II OA	7 (23.4%)
OA started post-operative	3 (10%)
OA aggravated post-operative	2 (6.6%)
Arthroscopic intervention	
Transtibial pullout repair	2 (6.6%)
Repair by sutures and/or Fast Fix	19(63.4%)
Total meniscectomy	3 (10%)
Subtotal meniscectomy	2 (6.6%)
Partial meniscectomy	3 (10%)
Combined resection and repair	1(3.3%)

Data are presented as frequency and percentage (%). OA: Osteoarthritic

Post operative Clinical presentation showed that out of 30 patients, 19 were asymptomatic (63.4%) and 11 patients (36.6%) experience symptoms such as: knee joint swelling, discomfort or pain, restriction of motion, instability/giving way, and catching/locking as shown in **Table 5**.

Table 5: Postoperative patient complain in correlation to postoperative MRI

Complaint	Postoperative MRI findings	Number (Percentage)
Knee Pain	Fragmentation, non-healed meniscus	4 (13.4%)

Knee Swelling	Retear of remaining meniscus	1(3.3%)
Movement limitation	New tear in a distant location	1(3.3%)
Instability/giving away	Partial healing	3 (10%)
Catching/locking	Successfully healed meniscus	2 (6.6%)
Post-operative MRI findings (17 patients underwent meniscus repair)		
Healed		11(63.6%)
Partial healed		3 (10%)
Non healed		2 (6.4%)
New tear in a distant location		1 (3%)
Post-operative MRI findings (13 patients underwent meniscectomy)		
Volume decreasing		5 (16%)
Volume loss		2(6%)
Meniscal regeneration		3 (10%)
Residual GIII signal without re-tear		2(6%)
New tear in a distant location		1(3%)
Re-tear		1(3%)

Data are presented as frequency and percentage (%).

Case3

A 28-year-old male patient presented 8 months after arthroscopic total meniscectomy of the PHMM complex tear in the PHMM concurrent with ACL reconstruction. By clinical examination of the menisci, the patient was free, and shows the following on the radiological studies.

Pre-operative MRI: A& B) Sagittal PD FSE and T2-weighted fat suppressed images show a complex tear of the PHMM. **Post-operative MRI:** C) &D) Sagittal PD FSE serial images show a “new meniscus” which is seen as thin and small inhomogeneous signal intensity structure in the site of the totally removed PHMM. **Post operative Plain x ray:** E) & F) Post-operative anterior-posterior and lateral radiograph of the knee shows evidence of tibial tunnel (ACLR). No bony pathology or osteoarthritic changes could be detected.

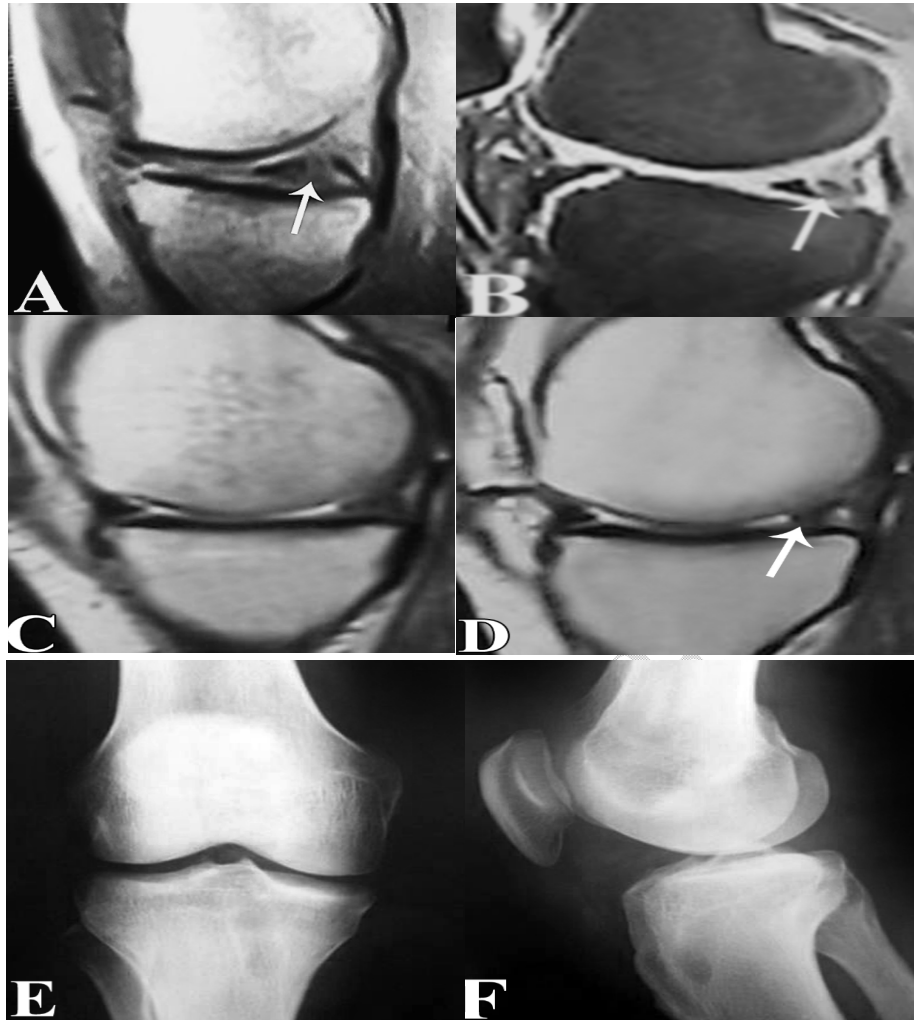


Fig 1: Pre-operative MRI, Post-operative MRI, and Post operative Plain x ray of knee

Case 4:

A 15-year-old male patient presented for routine follow up 6 months after ACL reconstruction and arthroscopic repair with Fast Fix® and partial resection of a torn discoid lateral meniscus (LM). Radiologic imaging studies of the patient revealed the following.

Plain x ray: No osteoarthritic changes could be detected. **Pre-operative MRI:** A) & B) Coronal T2-wieghted STIR and sagittal PD FSE images revealed moderate synovial effusion and a tear of the lateral discoid meniscus. **Post-operative MRI:** C) Coronal T2-wieghted fat suppressed image reveals decreased width of the LM (volume loss). D) Persistent abnormal

linear SI of both horns of the LM on PD FSE sagittal image. E) Sagittal PD fat suppressed image shows mild synovial effusion with no fluid signal of the anterior or posterior horns of the completely healed LM.

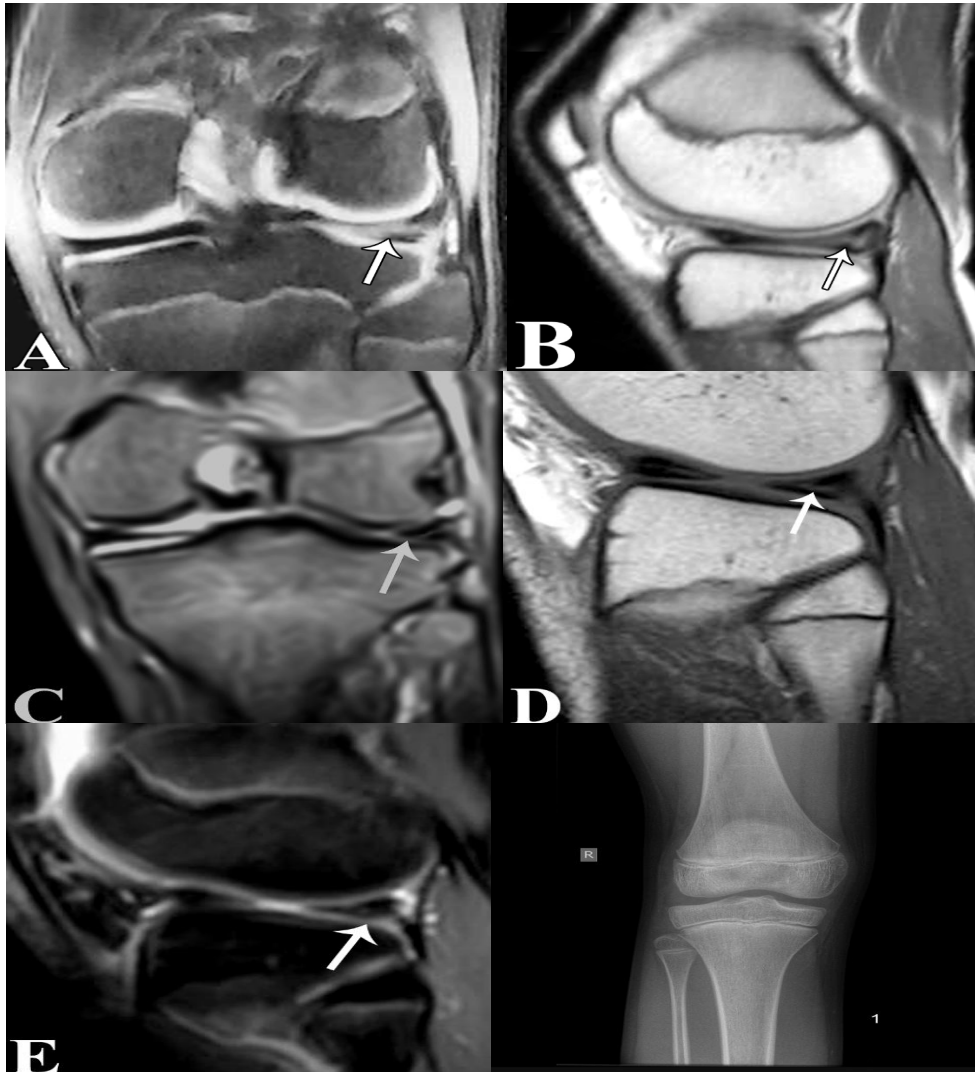

Fig 2: Pre-operative MRI, Post-operative MRI, and Plain x ray of knee

Discussion

The present study showed that 30 patients underwent MRI examination of the knee post operatively for follow up and according to patient's condition in the following: at 3-6 months 10% had Partial healing, at 6-12 months; 50% had complete healing; 12-18months 13.4 %

had new meniscus formation & 18 months with complain of pain; 3.3% had anew tear. The time needed for beginning of meniscus healing after surgery ranged from 3-6months.

In accordance with our results, studies of Kijowski et al. ^[4], Magee, ^[5] & Ciliz et al. ^[6] as they demonstrated that following meniscal surgery, an MRI of the knee is often recommended for the examination of persistent or recurring knee discomfort or pain. For individuals who have not had previous knee surgery, MRI offers a high sensitivity and specificity for the detection of meniscus tears. Because the conventional criteria used to detect a meniscus injury cannot be used to the post-operative meniscus, diagnostic performance is reduced after partial meniscectomy.

The current study showed that among the 30 patients, the tear was found in the posterior 1/3 in 27 (90%) patients, the anterior 1/3 in 2 (6.6%) patients, the middle 1/3 in 1 (3.4%) patient, and the posterior 1/3 in 2 (6.6%) patients. As regard Patterns of meniscal tears, 36.4% had Degenerative tears, 30% had horizontal tear ,10% had Bucket-handle tears & 10% had Complex tears and Cleavage tears.

However, in the study of Chhabra et al. ^[7], The most common type of meniscus tear was the complex type on both MRI (17/44, 38.6%) and arthroscopy (18/44, 40.9%). In a population that has had surgery, it is expected that the horizontal or horizontal flap injuries with degenerative alterations would be the least frequent forms. On arthroscopy and MRI, the radial injuries were the lowest (2.8 0.2 and 6.0 4.8 mm), while the bucket handle tears were the greatest (39.0 5.5 and 50.27 7.9 mm).

While, in the study of Yoo et al. ^[7], A horizontal cleavage has to be the most often related tear type among the 24 who experienced tears.

In the study in our hands, as regard associated findings; detected either pre- or post-operative, or even during arthroscopy such as synovitis, synovial effusion, osteoarthritic changes and the ACL affection. As regard associated osteoarthritic changes: Out of 30 patients 18 (60%)

patients have no osteoarthritic (OA) changes, 7 (23.4%) patients represented with a pre and post operative grade I or II OA, 3(10%) represented with OA started postoperative and 2(6.6%) represented OA aggravated post-operative.

The present study showed that as regard arthroscopic intervention: thirty cases were treated; seventeen had arthroscopic repair, and thirteen underwent resection. As regard post operative clinical presentation: Out of 30 patients, 19 were asymptomatic (63.4%) and 11 patients (36.6%) experience symptoms such as: knee joint swelling, discomfort or pain, restriction of motion, instability/giving way, and catching/locking.

Whereas, in the study of Kijowski et al. ^[4], During the second arthroscopic operation, 76 of the 148 partially resected menisci were torn, whereas 72 were untorn.

Our results showed that as regard the meniscal findings in the post-operative MRI there were many findings, 36.6% were Healed, 10% had Partial healed and 6.6% were no healed and 3.3% had new tear in a distant location as follows depending on the arthroscopic intervention (Repair or resection). As regard Post-operative MRI findings among 13 patients underwent meniscectomy; 16.6% had Volume decreasing and 6.6 % has volume loss.

Our findings were supported by a research by Oei et al. ^[8], which showed that although 34% of patients from grade 1 and 2 categories had degenerative abnormalities repaired, 78% of patients had no radiographic alterations at all. According to Kumm et al.'s ^[9] investigation, a middle-aged person's linear intrameniscal signal intensity in MRI cannot be resolved during a 6-year follow-up. Such results are a substantial risk factor for a progressive meniscal tear in the medical community.

According to Kijowski et al.'s ^[4] research, MRI findings for an untorn post-operative meniscus were 100% sensitive and trustworthy when there was no line of enhanced signal through the meniscus that extended to the articular surface on PD and T2-weighted images. Additionally, they discovered a number of MRI features that were very specific for detecting

a recurrent tear, such as a line of intermediate-to-high signal or high signal through the meniscus extending into the articular surface on T2-weighted images with 95.8% specificity and a change in the signal intensity pattern through the meniscus on intermediate weighted or T2-weighted images when compared to the baseline MRI with 98.2% specificity.

In the previous research, all 36 post-operative menisci without a T2 line were left intact at surgery (100 percent NPV; negative predictive values), but 46 of the 79 post-operative menisci with intermediate T2 line, 16 of the 18 post-operative menisci with intermediate-to-high T2 line, and 14 of the 15 post-operative menisci with high T2 line were torn (58.2%, 88.9%, and 93.3%, PPV (Positive predictive values) (85.7%), displaced meniscus fragment (100%) and change in signal pattern across the meniscus (PPV 99.4%) were additional MRI features linked to damaged post-operative meniscus during surgery^[4].

On intermediate-weighted images, Lim and colleagues^[10] showed an 88% sensitivity for a line across the meniscus.

In contrast, White and colleagues^[11] reported that 71 arthroscopically confirmed recurring meniscal tears were discovered. For the diagnosis of recurrent meniscal tears, conventional MRI had sensitivity, specificity, positive predictive value, negative predictive value, and accuracy of 86%, 67%, 83%, 71%, and 80%, respectively; indirect MR arthrography had sensitivity, specificity, positive predictive value, negative predictive value, and accuracy of 83%, 78%, 90%, 64%, and 81%, respectively; and direct MR arthrography had 90%, 78%, 90%, 78%, and There was no discernible difference between one method's diagnostic efficacy and another's ($P > .54$). The most accurate marker of a recurrent tear was the surfacing intrameniscal T2-weighted signal intensity, which also had the greatest positive predictive value.

According to Magee's research^[5], conventional MR examination demonstrated a reasonable sensitivity and specificity for detecting meniscal retears in a post-operative knee (78%

sensitivity, 85% specificity). When compared to a standard MR exam, an MR arthrogram examination performed slightly enhanced sensitivity and specificity (88% sensitivity, 100% specificity). The diagnosis of a meniscal re-*tear* was more sensitive when pre-contrast conventional MR imaging was paired with post-arthrogram, T1-weighted, fat-saturated MRI (99% sensitivity, 85% specificity).

In comparison to arthroscopy, prior investigations showed that a standard MR exam could accurately diagnose a meniscal tear in individuals who had never had knee surgery with an accuracy of 90% or higher. Patients who had had meniscal resection or repair showed conventional MR accuracy to be less accurate ^[12, 13].

Conclusions

Within the first two years after arthroscopic operations, MRI plays a useful role in detecting anticipated morphological alterations of the knee menisci.

Consent

As per international standard or university standard, patient(s) written consent has been collected and preserved by the author(s).

Ethical Approval:

As per international standard or university standard written ethical approval has been collected and preserved by the author(s).

References

1. De Smet AA. How I diagnose meniscal tears on knee MRI. *AJR Am J Roentgenol.* 2012;199:481-99.

2. Nacey NC, Geeslin MG, Miller GW, Pierce JL. Magnetic resonance imaging of the knee: An overview and update of conventional and state of the art imaging. *J Magn Reson Imaging*. 2017;45:1257-75.
3. Pauli C, Grogan SP, Patil S, Otsuki S, Hasegawa A, Koziol J, et al. Macroscopic and histopathologic analysis of human knee menisci in aging and osteoarthritis. *Osteoarthritis Cartilage*. 2011;19:1132-41.
4. Kijowski R, Rosas H, Williams A, Liu F. MRI characteristics of torn and untorn post-operative menisci. *Skeletal Radiol*. 2017;46:1353-60.
5. Magee T. Accuracy of 3-Tesla MR and MR arthrography in diagnosis of meniscal re-tear in the post-operative knee. *Skeletal Radiol*. 2014;43:1057-64.
6. Ciliz D, Ciliz A, Elverici E, Sakman B, Yüksel E, Akbulut O. Evaluation of postoperative menisci with MR arthrography and routine conventional MRI. *Clin Imaging*. 2008;32:212-9.
7. Chhabra A, Ashikyan O, Hlis R, Cai A, Planchard K, Xi Y, et al. The International Society of Arthroscopy, Knee Surgery and Orthopaedic Sports Medicine classification of knee meniscus tears: three-dimensional MRI and arthroscopy correlation. *Eur Radiol*. 2019;29:6372-84.
8. Oei EH, Nikken JJ, Verstijnen AC, Ginai AZ, Myriam Hunink MG. MR imaging of the menisci and cruciate ligaments: a systematic review. *Radiology*. 2003;226:837-48.
9. Kumm J, Roemer FW, Guermazi A, Turkiewicz A, Englund M. Natural History of Intrameniscal Signal Intensity on Knee MR Images: Six Years of Data from the Osteoarthritis Initiative. *Radiology*. 2016;278:164-71.
10. Lim PS, Schweitzer ME, Bhatia M, Giuliano V, Kaneriya PP, Senyk RM, et al. Repeat tear of postoperative meniscus: potential MR imaging signs. *Radiology*. 1999;210:183-8.
11. White LM, Schweitzer ME, Weishaupt D, Kramer J, Davis A, Marks PH. Diagnosis of recurrent meniscal tears: prospective evaluation of conventional MR imaging, indirect MR arthrography, and direct MR arthrography. *Radiology*. 2002;222:421-9.
12. McCauley TR. MR imaging evaluation of the postoperative knee. *Radiology*. 2005;234:53-61.
13. Totty WG, Matava MJ. Imaging the postoperative meniscus. *Magn Reson Imaging Clin N Am*. 2000;8:271-83.