

Adipose Derived Stem Cells in the Treatment of Vitiligo

ABSTRACT

Background: Vitiligo is an acquired skin disorder with challenging treatment options. Adipose-derived stem cells can stimulate the differentiation of the adjacent cells into specialized cells owing to the effect of several growth factors. They may be able to differentiate into melanocyte precursors.

Objective: To detect the safety and effectiveness of ADSCs in the vitiligo treatment.

Methods: We recruited 15 patients in this study with stable vitiligo which is resistant to the ordinary methods of treatment. The injection of ADSCs was done in single session then followed by narrow band-UVB sessions twice weekly and the patients were assessed clinically after three months.

Results: The median percentage of re-pigmentation was 60%, while regarding the degree of improvement, 26.6% of patients showed excellent and 33.3% of patients had good responses. 53.3% of patients did not have any side effects while other patients experienced minimal side effects

Conclusion: ADSCs could be a promising and safe alternative treatment for resistant vitiligo cases.

Key words: Vitiligo, Adipose derived stem cells, narrow band-UVB

1. INTRODUCTION:

Vitiligo is a common, disfiguring autoimmune disease that has a major negative influence on sufferers' quality of life and self-esteem. It is characterized by isolated, dispersed, or diffuse white patches on the skin that are occasionally linked to an early whitening or greying of the hair. [1]

Dermabrasion, transplantation of epidermal or hair follicle outer root sheath cells, cultured epithelial cells or cultured epithelia sheet grafts, suction blistering grafting, minipunch grafting, platelet-rich plasma enriched (PRP) supplementation, and autologous mesenchymal stem cells (MSCs) are different methods including surgical and regenerative ways have been suggested to restore pigmentation in vitiligo. [2,3]

New potential treatments for patients with vitiligo have been emerged due to stem cell research. The outer root sheath (ORS) of the hair follicle's pluripotent cells can be differentiated and amplified to produce an endless supply of melanocytes for cell-based therapy. [4]

Adipose tissue is a particularly practical source for isolating adipose derived stem cells (ADSCs), which have been used in the field of regenerative medicine. Additionally, it was recently shown that adipose tissue significantly affects the cellular microenvironment [5], since they have the capacity to secrete a variable cytokines and growth factors, including HGF, IL-6, M-CSF, TGF- β 1, TNF-, and VEGF, that stimulate angiogenesis, tissue remodeling, and anti-apoptotic processes. Through direct intercellular processes and the production of these soluble molecules, they also exert anti-inflammatory and immunomodulatory action. [6,7,8]

In our study we aimed to assess the safety and efficacy of intralesional injection of autologous adipose derived stem cells in vitiligo patients' treatment in an effort to provide a new route for vitiligo patients to receive autologous cellular treatment.

2. PATIENTS AND METHODS:

In our study, 15 vitiligo patients with stable disease were included. The patients were gathered from Tanta University Hospitals' Dermatology & Venereology Department's outpatient clinics and all of them signed a consent before the beginning of the study.

The selected patients had localized and stable vitiligo with Vitiligo Disease Activity Score (VIDA) equals zero or one [9]. Patients suffering from systemic or blood diseases, very thin patients, and female patients in the period of pregnancy and lactation were excluded from the study.

All patients underwent a history taking, complete skin examination, and general examination. The vitiligo patches were examined by Wood's light to confirm the diagnosis. Full laboratory investigations were done including complete blood picture, hepatitis B, hepatitis C, HIV coagulation profile, and pregnancy test for female patients. Photographs of the lesions before, and after treatment were taken.

From each patient a localized vitiligo patch was selected and all the patches showed one hundred percent depigmentation, and were exposed to single injection of adipose derived stem cells followed by narrow band UVB sessions twice weekly for 3 months starting the day after the procedure.

The technique of surgery:

Lipoaspiration method:

The aspiration was done at operation room with complete aseptic precautions. The patients laid in a supine position with sterilization of the abdomen using povidone iodine 10%. Local injection of lidocaine was done at one side of the abdomen, then a small puncture was done using a scalpel. Through this opening a cannula was inserted allowing injection of tumescent anesthesia (1: 1,000,000 epinephrine and lidocaine 1% 1mg/kg in normal saline 0.9% solution) (Figure 1). A liposuction cannula was passed through the incision and was connected to a surgical suction machine. The cannula was moved back and forth to aspirate the fat into a container, after which it was drained into sterile 50 ml tubes and brought to the laboratory (Figure 2 A, B). An adhesive dressing and a compression garment were applied at site of aspiration for 2 weeks.

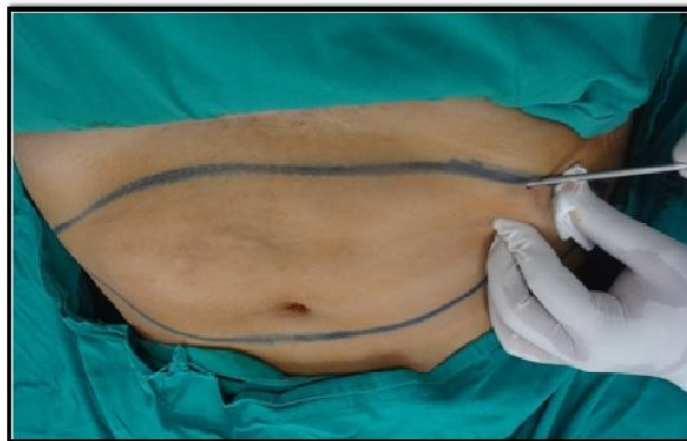

Figure (1): Insertion of a cannula at the site of incision for injection of tumescent anesthesia




Figure (2): A) Collection of fat in a sterile container. B) Collection of fat in a sterile 50 ml tube before centrifugation.

Adipose derived stem cells preparation:

The first step was washing of the collected fat with an equal volume of phosphate buffered saline(PBS) then centrifugation, the infranatant was aspirated and discarded to remove blood cells, anaesthesia and saline. This process was repeated for 3-4 times until the fluid in the final wash is clear. PBS was added to the washed adipose tissue to form 25 ml, then addition of collagenase 35ul with shaking. The mixture was incubated for 1 hour at 37 c with vigrous shaking every 10-15 minutes until digestion of fat tissue. The resultant fluid then centrifuged at 600 g for 5 minutes. The supernatant part was aspirated and discarded leaving the infranatant part which is stromal vascular fraction (SVF) pellet that was re-suspended in a solution formed of [Dulbecco's Modified Eagle Medium (44 ml), fetal bovine serum 10% (5 ml), and Penicillin-Streptomycin-Amphotericin B

mixture (1 ml)] (Figure 3). A second centrifugation at 600 g (2180 rpm) for 5-10 minutes was done and the infranatant was filtered through strainer (100 um) to remove the unwanted debris and fragments and a third centrifugation at the same previous speed for 5 minutes. The newly formed infranatant part represented the new pellet that was prepared for intradermal injection by addition of 2 ml of PBS. [10].



Figure (3): Pellet formed from centrifugation of (SVF pellet+ DMEM+ FBS+ Penicillin-Streptomycin-Amphotericin B mixture).

The injection technique:

Following the administration of local anaesthetic, cleaning and sterilization of the vitiliginous lesions was done by the use of alcohol 70%. After preparation, ADSCs were injected intradermally. The injection's endpoint was the appearance of a yellow bleb at the injection site. An insulin syringe (28G x 12) was used for the injection, and 0.1 ml was injected at each location, the depth of injection was 3 mm and the distance between each two points of injection was 1 cm.

The day after the procedure, patients started to receive NB-UVB therapy twice a week for a period of 3 months, according to the minimal erythema dose, started with a dose of 0.21 J/cm² that was increased by 20% per treatment session. [11]

Assessment of the treatment response

Serial photographs were taken at the initial visit and every month for a period of three months following the procedure and they were used for clinical assessment. The photographs were reviewed by three blinded dermatologists to compare before and after treatment in all patients to assess the percentage of repigmentation and the repigmentation response as follows: No change: (0%), Poor: (1–25%), Moderate: (26–50%), Good: (51–75%), Excellent: (76–99%), and complete repigmentation: (100%).

The patients' satisfaction was recorded whether not satisfied, slightly satisfied, satisfied or very satisfied. Any adverse effects after treatment had been reported.

Statistical data analysis:

With the aid of the IBM SPSS software package version 20.0, data were fed into the computer and evaluated. IBM Corp., Armonk, New York Number and percentage were used to describe qualitative data. The range (minimum and maximum), mean, standard deviation, and median were used to characterise quantitative data.

3. RESULTS:

Data on the patient's demographics summarized in (Table 1)

Table (1): Demographic data of the Patients (n= 15)

	No.	%
Gender		
Male	3	20.0
Female	12	80.0
Age (years)		
Min. – Max.	17.0 – 45.0	
Mean ± SD.	30.5 ± 9.6	
Median	33	
Duration of the disease(years)		
Min. – Max.	1.50 – 15.0	
Mean ± SD.	4.3± 3.7	
Median	3	
Skin type		
III	6	40.0
IV	9	60.0
Family history		
Negative	10	66.6
Positive	5	33.4

As regards the percentage of re-pigmentation, it ranged from 0% to 99% with median percentage of re-pigmentation 60% and the mean was 48.13 ± 39.2 (Table 2). While the degree of improvement showed, 26.6 % of patients with excellent response (Figure 4). 33.3% showed good response (Figure 5), 13.3% of patients showed moderate response, 20% of patients showed poor (Figure 6) and 6.6% of patients showed no repigmentation response (Table 2).

As regards the site of vitiligo patches, 3 (20.0%) patches were on the trunk, 4 (26.6%) on the extremities, 5 (33.3%) on the acral parts and 3 (20 %) patches were on the face. All the patches on the extremities showed excellent response, while all the acraly located lesions showed poor or no responses.

Regarding the patients' satisfaction, 40% of patients were very satisfied, 33.3% of patients were satisfied, 20% were slightly satisfied, and 6.6% were not satisfied at all.

As regards the side effects, 53.3% of patients did not complain of any side effects, 26.6% had pain, and 13.3% had tingling sensation at the liposuction site, and 6.6% of patients experienced ecchymosis in the injected vitiligo patch. All the side effects were mild and resolved spontaneously within few days.

Table (2): Percentage of repigmentation and degree of improvement (n=15)

Percentage of re-pigmentation	%	
Min. – Max.	0-99	
Mean ± SD.	48.13±39.2	
Median	60	
Degree of improvement	No.	%
No	1	6.6
Poor	3	20
Moderate	2	13.3
Good	5	33.3
Excellent	4	26.6

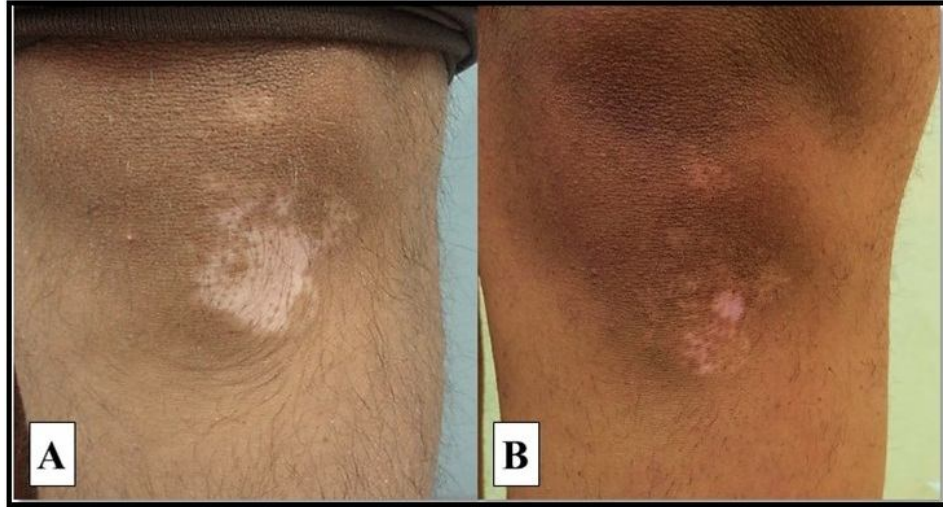
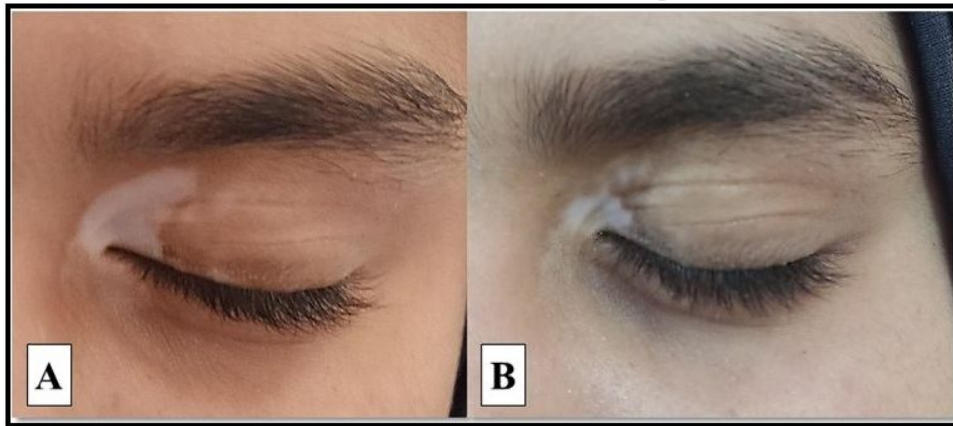
Figure (4): A) Male patient with lesion on the left knee before treatment with



ADSCs/NB-UVB. B) Excellent improvement at the end of treatment showing.

Figure (5): A) Female patient vitiligo lesion on the left eye lid before treatment with ADSCs/NB-UVB. B) Good improvement at the end of treatment.

4. DISCUSSION:

Adipose derived stem cells (ADSCs) are mesenchymal stem cells that have been found in the interfollicular dermis, the hypodermis, the dermal sheets, and the subcutaneous connective tissue near the base of hair follicles (dermal papilla cells). These cells have the ability to repair injured or dead cells and to trigger cellular regeneration, ADSCs are known to multiply and develop into several types of cells including skin cells [12]. Additionally, they significantly alter the cellular microenvironment by secreting a variety of bioactive substances with pleiotropic effects [13]. The primary role of ADSCs is to stimulate neighbouring cells to differentiate into specialised cells in response to certain growth factors. In addition, exogenous delivery of ADSCs mobilises other stem cells, including the epidermal stem cells from the hair follicle's "bulge" region. Based on the creation of growth factors, this step is taken [3].

There was only one trial to use the combination of ADSCs injection and NB-UVB conducted on mice that had induced vitiligo by monobenzene and concluded that clinically, there was significant reduction in vitiligo patches confirmed by presence of cellular infiltration and acanthosis by histopathological examination. [14]

Up to our knowledge, this is the first clinical study to assess the safety and efficacy of ADSCs injection in vitiligo treatment in humans.

15 patients with localised stable vitiligo participated in this study with VIDA score (0 or 1), from each patient a single vitiligo patch with 100% depigmentation was selected. Fat was aspirated from the lower abdomen, then the fat was processed to isolate ADSCs to be used for intradermal injection.

Regarding the technique, fat aspiration was from lower abdomen in all cases. Rohrich et al [15] studied the difference in adipocyte viability and quantity of ADSCs from different donor areas and found no significant differences between abdomen, thighs and flanks while, Guyuron and Majzoub [16] preferred lower abdomen for liposuction as it is easy accessible and contains abundant fat. Additionally, Padoin et al [17] discovered that lower abdomen lipoaspirate has a significantly higher concentration of ADSCs than other regions.

In our study, intralesional injection of ADSCs was done in the same day of fat aspiration based on the findings of Othmani AE et al [18] who claimed that a maximum of 12 hours could pass before SVF fractions with higher ADSC frequencies could be expanded in expansion culture. However, additional research indicated that this period might be increased to 24 hours without compromising ADSC recovery. [19].

Regarding the studied patient's characteristics, the patients' age ranged from 17 to 45 years with mean age of (30.5 ± 9.6) . They were 3 (20 %) males and 12 (80%) females of the studied patients. This higher percentage of female patients in our study could be explained by seeking for the treatment of vitiligo more by females mostly due to cosmetic and social reasons.

Regarding the degree of improvement in our study, 26.6% of patients had excellent response and 33.3% of patients had good response, 13.3% of patients showed

moderate response, 20% of patients showed poor response, and 6.6% of patients had no response. The mean percentage of re-pigmentation was 48.13 ± 39.24 .

Although the precise process by which ADSCs can cause re-pigmentation in vitiligo is uncertain, the following ideas could be put forth: melanocyte growth factor (MGF) and basic fibroblast growth factor (bFGF), which are products of ADSCs, may be responsible for the melanocytes' considerable stimulation of proliferation and migration. Furthermore, in comparison of keratinocyte and melanocyte monocultures, co-cultures with ADSCs showed a rise in the proportion of melanocytes that express TRP-2, E-cadherin, and N-cadherin positively. The adhesion between keratinocytes and melanocytes is regulated by E cadherin, whereas N-cadherin promotes contact between fibroblasts and melanocytes. Melanocytes that express TRP-2 (tyrosinase dopachrome) are thought to be melanocyte progenitors. Additionally, they help melanocytes to differentiate. [20,21]

Therefore, during migration before entering the epidermis, the melanocyte precursor cells might manufacture E-cadherin on their cell surface. Last but not least, it was proposed that ADSCs might develop into melanocyte precursors as proved by El Maadawi MZ et al [22] and Zavala et al. [23].

One of the determining factors of the success of a treatment modality of vitiligo treatment is the site of the lesions. In the current study, we found that the best response was noticed on extremities followed by the trunk and facial patches, and the worst response was observed in the acral patches. In agreement with our results, El-Zawahry et al [24] reported in their study that 90% of patients with acral vitiligo showed no response.

Acral lesions and lesions over joints typically respond poorly to surgical care and are resistant to medicinal treatment. On the contrary, Saleh et al [25] mentioned that the sites showed improvement after treatment with variable degrees were 100% of the lesions in hands, face, knee, and wrist, 80% of elbows, 75% of neck lesions, 66% of breast lesions, 20% of upper limb lesions, and 16% of lesions in lower limb and feet.

Regarding the side effects in our study, there were no complications in 53.3% of patients, 26.6% of patients had pain in the donor site after fat aspiration, 13.3% patients had tingling at the donor site, and 6.6% patients experienced ecchymosis at the injection site. All these side effects were mild and resolved spontaneously. Saleh et al [25] mentioned in their study that the most often seen side effects were infection, erythema, itching, burning feeling, rigors, and fever, all of which were moderate and did not require therapy to be stopped. Maione et al [26] in their analysis of complications in 1000 patients after autologous fat graft, they reported only 2 patients with hematoma in the first 24 hours at the donor site, and local deformity in the form of fibrosis in 83 patients as a late complication. No patients developed seroma, skin necrosis or infection.

5. CONCLUSION:

For patients with vitiligo, adipose-derived stem cells present a potentially successful and secure therapy alternative. To validate the usefulness of ADSCs in the therapy of vitiligo, we urge further research using bigger sample sizes and comparative controlled studies.

Consent

As per international standard or university standard, patient(s) written consent has been collected and preserved by the author(s).

Ethical Approval:

As per international standard or university standard written ethical approval has been collected and preserved by the author(s).

REFERENCES:

1. Krüger C, Schallreuter KU. A review of the worldwide prevalence of vitiligo in children/adolescents and adults. *Int J Dermatol*. 2012;51(10):1206-12.
2. Fisch SC, Gimeno ML, Phan JD, et al. Pluripotent nontumorigenic multilineage differentiating stress enduring cells (Muse cells): a seven-year retrospective. *Stem Cell Res Ther*. 2017;8(1):227.
3. Owczarczyk-Saczonek A, Wociór A, Placek W, et al. The Use of Adipose-Derived Stem Cells in Selected Skin Diseases (Vitiligo, Alopecia, and Nonhealing Wounds). *Stem Cells Int*. 2017;2017:4740709.
4. Vinay K, Dogra S, Parsad D, Kanwar AJ, et al. Clinical and treatment characteristics determining therapeutic outcome in patients undergoing autologous non-cultured outer root sheath hair follicle cell suspension for treatment of stable vitiligo. *J Eur Acad Dermatol Venereol*. 2015;29(1):31-7.
5. Bellei B, Papaccio F, Filoni A, et al. Extracellular fraction of adipose tissue as an innovative regenerative approach for vitiligo treatment. *Exp Dermatol*. 2019;28(6):695-703

6. Maumus M, Jorgensen C, Noël D. Mesenchymal stem cells in regenerative medicine applied to rheumatic diseases: role of secretome and exosomes. *Biochimie*. 2013;95(12):2229-34.
7. Zuk P. Adipose-Derived Stem Cells in Tissue Regeneration: A Review. *Stem Cells*. 2013;2013:713959.
8. Leto Barone AA, Khalifian S, Lee WP, et al. Immunomodulatory effects of adipose-derived stem cells: fact or fiction? *BioMed Res Int*. 2013;2013:383685.
9. Feily A. Vitiligo Extent Tensity Index (VETI) score: a new definition, assessment and treatment evaluation criteria in vitiligo. *Dermatol Pract Concept*. 2014;4(4):81-4.
10. Elsamongy M, Ayad H, Eid M, et al. The Efficacy of Autologous Nanofat Versus Enhanced Nanofat with Adipose-Derived Stem Cells Transfers in the Treatment of Atrophic Post Acne Scars. *J Advan Med and Med Res*. 2020; 32:17-31.
11. Bansal S, Sahoo B, Garg V. Psoralen-narrowband UVB phototherapy for the treatment of vitiligo in comparison to narrowband UVB alone. *Photodermatol Photoimmunol Photomed*. 2013; 29:311-7.
12. Mazini L, Rochette L, Admou B, et al. Hopes and Limits of Adipose-Derived Stem Cells (ADSCs) and Mesenchymal Stem Cells (MSCs) in Wound Healing. *Int J Mol Sci*. 2020;21(4).
13. Bellei B, Papaccio F, Filoni A, et al. Extracellular fraction of adipose tissue as an innovative regenerative approach for vitiligo treatment. *Exp Dermatol*. 2019;28(6):695-703.

14. Bian Y, Yu H, Jin M, et al. Repigmentation by combined narrow-band ultraviolet B/adipose-derived stem cell transplantation in the mouse model: Role of Nrf2/HO-1-mediated Ca²⁺ homeostasis. *Mol Med Rep.* 2022;25(1).
15. Rohrich RJ, Sorokin ES, Brown SA. In search of improved fat transfer viability: a quantitative analysis of the role of centrifugation and harvest site. *Plast Reconstr Surg.* 2004;113(1):391-5.
16. Guyuron B, Majzoub RK. Facial augmentation with core fat graft: a preliminary report. *Plast Reconstr Surg.* 2007;120(1):295-302.
17. Padoin AV, Braga-Silva J, Martins P, et al. Sources of processed lipoaspirate cells: influence of donor site on cell concentration. *Plast Reconstr Surg.* 2008;122(2):614-8.
18. Othmani A, Rouam S, Abbad A, et al. Cryopreservation Impacts Cell Functionality of Long Term Expanded Adipose-Derived Stem Cells. *Stem Cell Res Ther.* 2019;9:1.
19. Carvalho PP, Wu X, Yu G, et al. The effect of storage time on adipose-derived stem cell recovery from human lipoaspirates. *Cells Tissues Organs.* 2011;194(6):494-500.
20. Kim JY, Park CD, Lee JH, et al. Co-culture of melanocytes with adipose-derived stem cells as a potential substitute for co-culture with keratinocytes. *Acta Dermato-Venereol.* 2012;92(1):16-23.

21. Derycke LD, Bracke ME. N-cadherin in the spotlight of cell-cell adhesion, differentiation, embryogenesis, invasion and signalling. *Int J Dev Biol.* 2004;48(5-6):463-76.
22. El Maadawi Z, Fawzy M, Gabr H. In-vitro differentiation of adipose-derived stem cells into melanocytic lineage: A possible new alternative treatment for vitiligo. *The Egy J Histol.* 2016;39:260-8.
23. Zavala G, Sandoval C, Meza D, et al. Differentiation of adipose-derived stem cells to functional CD105(neg) CD73(low) melanocyte precursors guided by defined culture condition. *Stem Cell Res Ther.* 2019;10(1):249.
24. El-Zawahry BM, Elmasry MF, Ragab A. The role of long-wavelength ultraviolet A1 (UVA1) in acral vitiligo. *J Cosmet Dermatol.* 2019;18(4):1155-60.
25. Saleh AA, Salam OHA, Metwally GH, et al. Comparison Treatment of Vitiligo by Co-culture of Melanocytes Derived from Hair Follicle with Adipose-Derived Stem Cells with and without NB-UVB. *Pigmentary Dis.* 2017; (4) 256.
26. Maione L, Vinci V, Klinger M, et al. Autologous fat graft by needle: analysis of complications after 1000 patients. *Ann Plast Surg.* 2015;74(3):277-80.