

**Evaluation of Holmium (YAG)-Laser transurethral en bloc resection in patients with primary non-muscle invasive bladder cancer. Pilot study**

**Abstract**

**Background:** TURBT **Authors should avoid abbreviations in the abstract.** is the gold standard treatment for NMIBC. **Authors should avoid abbreviations in the abstract.**

Lasers have been introduced as a minimally invasive option to decrease complication. Holmium and the 2- $\mu$ m laser TURBT are the most frequently applied lasers in TURBT.

The aim of this work was to evaluate Holmium Laser en bloc transurethral resection of bladder tumor (eTURBT) technique in resection of a primary bladder mass in terms of efficacy (Complete resection of the mass, histopathological staging and grading) and safety (operation time, blood loss, bladder perforation) and oncological outcomes (recurrence and progression).

**Methods:** This pilot study included 40 patients with primary bladder mass scheduled for endo-urological staging procedure with primary solitary mass does not exceed 3 cm in largest dimension and two masses each of them isn't more than 2 cm in maximum diameter. Resection was done enbloc by karl storz 26fr resctoscope and using VersaPulse holmium(YAG) laser by lumenis. **Authors should avoid abbreviations in the abstract.**

**Results:** Operative time had a mean  $\pm$  SD of (37.01  $\pm$ 5.50) min. The average enucleation time had a mean  $\pm$  SD of (23.11 $\pm$  6.26) min. blood loss had a mean  $\pm$  SD of (0.3  $\pm$  0.57). There was no need for blood transfusion at all. Bladder perforation occurred in only one case. Obturator jerk did not occur at all. Postoperative irrigation was indicated in only five cases

(12.5%) with a mean  $\pm$  SD was (1.21 $\pm$ 3.32) hours. Postoperative urethral catheter time had mean  $\pm$  SD was (28.38  $\pm$ 9.22) hours. Postoperative hospital stay ranged between 1-3 day. In histopathological examination, All included cases revealed TCC **Authors should avoid abbreviations in the abstract**, low grade in 19 patients (47.5%) and high grade in 21 patients (52.5%). All specimens contained bladder detrusor muscle, the pathological staging was pTa in 14 patients (35%), pT1 in 22 patients (55%) and pT2a **Authors should avoid abbreviations in the abstract** in 4 patients (10%).

**Conclusions:** Holmium laser transurethral en-bloc TURBT is an effective, feasible, and safe procedure for managing NMIBC **Authors should avoid abbreviations in the abstract**, as it preserves the entire lamina propria and detrusor muscle in well-intact specimens which lowers recurrence and progression and decreases the need for a second look TURBT.

**Keywords:** Holmium (YAG)-Laser transurethral en bloc resection, Non-muscle invasive bladder cancer

## Introduction:

Bladder cancer is the second most common cancer in Egyptian males after HCC **Authors must write the meaning** and third most common cancer in Egyptian females.<sup>[3]</sup> **Authors must write the citations in order: 1,2,3, etc.**

TURBT has been yet the gold standard for the treatment of NMIBC **Authors must write the meaning**.<sup>[3]</sup> However, the main disadvantages of TURBT include thermal damage of the adjacent tissue and piecemeal resection of the tumor, followed by the risk of recurrence and difficulties in accurate pathological evaluation of the tumor stage.<sup>[5]</sup> It has been proven that the presence of detrusor muscle is crucial for the quality and completeness of resection. While the absence of detrusor muscle in the specimen is associated with a significantly high risk of residual disease, tumor understaging, and early recurrence.<sup>[6]</sup>

In contrary to the conventional TURBT technique, en bloc resection is based on the established oncological principle of dissecting through normal tissue representing a promising technique of NMIBC resection in the manner of “sculpting and resecting” instead of the conventional technique of “incising and scattering”.<sup>[5, 7, 8]</sup>

The advantages of en bloc resection are the ability to provide an intact tissue specimen for accurate pathological evaluation, low risk of scattering malignant cells, and minimum bleeding during resection.<sup>[8]</sup>

Laser has been proved to be safe, effective and minimally invasive for NMIBC. Holmium and the 2- $\mu$ m laser TURBT are the most frequently applied treatments for NMIBC, and these treatments result in satisfactory outcomes.<sup>[9, 10]</sup>

The aim of this work was to evaluate Holmium Laser **en???** block transurethral resection of bladder tumor (eTURBT) technique in resection of a primary bladder mass in terms of efficacy (Complete resection of the mass, histopathological staging and grading), **and** safety

(operation time, blood loss, bladder perforation) and oncological outcomes (recurrence and progression).

### **Patients and Methods:**

This pilot study included 40 patients with primary bladder mass scheduled for endourological staging procedure with solitary mass does not exceed 3 cm in largest dimension and two masses each of them isn't more than 2 cm in maximum diameter.

An informed written consent was obtained from the patient. The study was done after approval from the Ethical Committee Tanta University Hospitals.(IRB=34243/11/20).

Exclusion criteria were masses more than 3 cm in size, multiple masses, (more than 2 masses each of them > 2cm), recurrent masses, patients with suspected difficult **en???**-bloc resection or tumor stage  $\geq$  T2.

All patients were subjected to complete history taking, physical examination **(DRE) Authors must write the meaning**, laboratory investigations including urine analysis, complete blood picture, renal function tests, liver function tests, bleeding profile and fasting and postprandial blood sugar, radiological investigations including ultrasonography and CT abdomen and pelvis with IV contrast), urine cytology and cystoscopy. Second look cystoscopy was carried out four weeks after initial resection if indicated.<sup>(137)(143)</sup> **Authors must write the citations in order: 1,2,3, etc.** Follow up by ultrasound, urine cytology and cystoscopy according to EUA guidelines. **(Reference???)**

### **Operative steps:**

Patient was placed in the lithotomy position, after spinal anaesthesia was administered. After cystoscopic assessment, tumour resection was performed routinely with a semifilled bladder (200 - 300 mL of irrigation fluid "normal saline 0.9 %"). Resection is performed using the Storz A 26 Fr continuous irrigation resectoscope with a laser bridge with the laser fiber (supported or not by a double-J pusher) connected to the versapulse PowerSuite (Lumenis)

Laser with power and frequency set at 0.6 to 1.2 joules, 8-10 hz respectively. **It is recommended that authors write the trademark, manufacturer's name and registered trademark sign <sup>TM</sup>.**

#### **A- Mass resection:**

The bladder tumour was first identified, followed by a circumferential incision of macroscopically normal mucosa about 0.5–1.0 cm away from the tumour base using Holmium-Yag laser with blocking blood vessels entering the tumor before resection to reduce intraoperative hemorrhage. Laser fiber was put close to bladder wall; the bladder mucosa was cut in a “flash-firing” fashion. When the deep muscle layer was reached the fiber was moved forward along the muscle layer with the base of the tumor lifted and pushed away step by step, the resection proceeds toward the deep muscle layer. Thus, the target tumor tissue including detrusor muscle layers was dissected out after several rounds of the current incision and the tumor was resected in one piece. The incision depth could be controlled by the amount of pressure applied to the bladder wall and the time of cutting. During cutting, bleeding vessels were coagulated simultaneously, keeping a clear vision of the field. Bladder biopsy was taken from tumor bed after complete resection of the mass.

#### **B- Specimen retrieval**

Resected specimen was grasped with the loop electrode or coldpunsh forceps and retrieved out through the resectoscope sheath. Tumour specimen was preserved in formalin solution and sent for histopathological examination. Papillae lined with layers of malignant urothelial epithelium. No invasion of lamina propia or included muscle bundles. Bilharzial calcified ova are seen imbedded within muscle bundles.

#### **Postoperative management:**

All patients were catheterized after confirming the absence of haemorrhage using a 22 Fr triple way catheter. If needed, continuous saline irrigation was performed and stopped once

clear output was obtained. All Patients received a single dose of (40 mg Mitomycin C in 40 ml saline) immediately postoperative or within 6 hours after surgery except in cases of frank haematuria or suspected perforations.

### Statistical analysis

Statistical analysis was done by SPSS v26 (IBM Inc., Chicago, IL, USA). Quantitative variables were presented as mean and standard deviation (SD). Qualitative variables were presented as frequency and percentage (%).

### Results:

Table 1 shows distribution of the studied cases according to demographic data, medical history and risk factors.

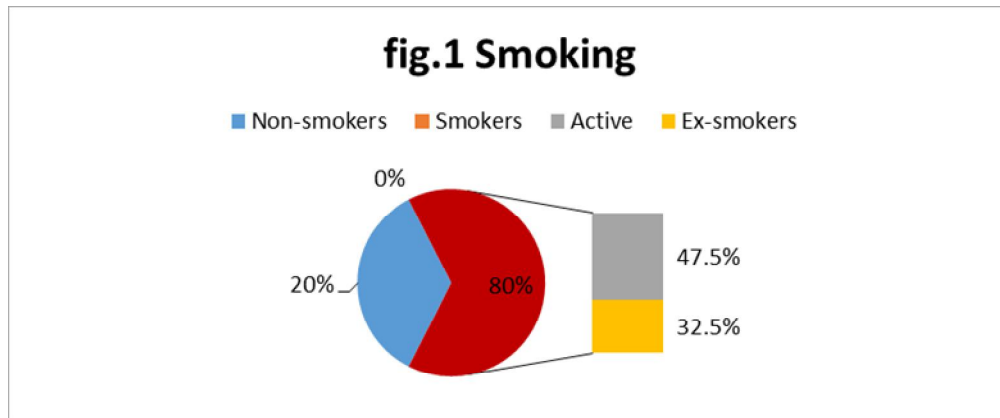
**Table 1: Distribution of the studied cases according to demographic data, medical history and risk factors**

			<b>N =40</b>
<b>Demographic data</b>	<b>Sex</b>	<b>Male</b>	33 (82.5 %)
		<b>Female</b>	7 (17.5 %)
	<b>Age (years)</b>		66.15 ± 8.28
	<b>Lifestyle</b>	<b>Rural</b>	21 (52.5%)
<b>Urban</b>		19 (47.5%)	
<b>Medical history</b>	<b>Hypertension</b>		21 (52.5%)
	<b>Diabetes Mellitus</b>		18 (45%)
	<b>Chronic liver disease</b>		7 (17.5 %)
	<b>Hepatitis C</b>		25 (62.5%)
<b>Risk factors</b>	<b>History of Bilharziasis</b>		9 (22.5%)
	<b>Smoking</b>		32 (80%)
	<b>Active smoker</b>		19 (47.5 %)
	<b>Ex-smoker</b>		13 (32.5%)

Data are presented as mean ± SD or frequency (%).

Table 2 shows distribution of the studied cases according to preoperative data.

**Figure 1 can be deleted because its information is already listed in Table 1.**



**Table 2: Distribution of the studied cases according to preoperative data**

		N =40
<b>Tumour location</b>	<b>Lateral</b>	25 (62.5%)
	<b>Posterior</b>	11 (27.5%)
	<b>Trigone</b>	4 (10%)
<b>Tumour number</b>	<b>Solitary</b>	38 (95%)
	<b>Multiple</b>	2 (5%)
<b>Tumour diameter (mm)</b>		29.79 ± 10.1

Data are presented as mean ± SD or frequency (%).

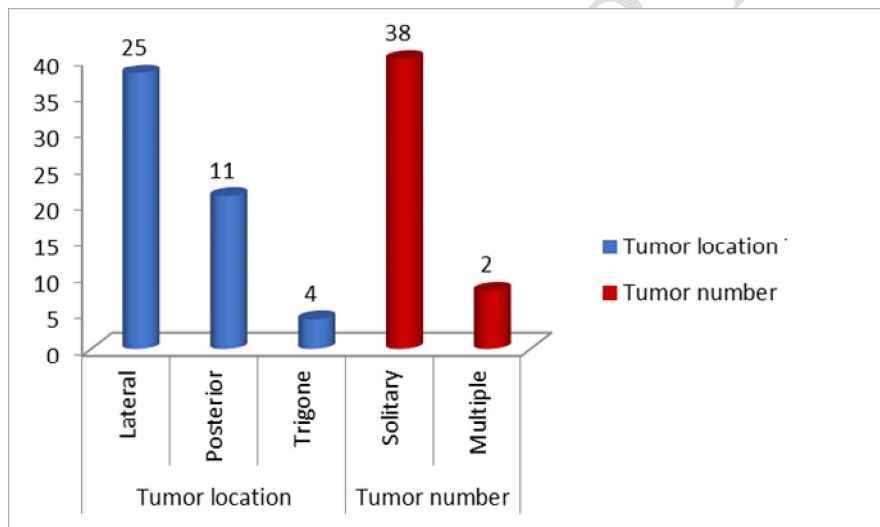


Fig.2 : Studied cases showing Tumor location and number

**Figure 2 can be deleted because its information is already listed in Table 2.**

Table 3 shows distribution of the studied cases according to intraoperative data and intraoperative complications.

**Table 3: Distribution of the studied cases according to intraoperative data and intraoperative complications**

		<b>N =40</b>
<b>Intraoperative data</b>	<b>Operative time (min)</b>	37.01 ± 5.50
	<b>Enucleation time (min)</b>	23.11 ± 6.26
<b>Intraoperative complications</b>	<b>Obturator nerve reflex</b>	0 (0%)
	<b>Bladder perforation</b>	1 (2.5%)
	<b>Blood loss (Hb drop=<del>gm/dl</del> g/dL)</b>	0.3 ± 0.57

Data are presented as mean ± SD or frequency (%).

Table 4 shows distribution of the studied cases according to postoperative data.

**Table 4: Distribution of the studied cases according to postoperative data**

		<b>N =40</b>
<b>Postoperative data</b>	<b>Irrigation time (hrs)</b>	1.21 ± 3.32
	<b>Catheter time (hrs)</b>	28.38 ± 9.22
	<b>Hospital stay (day)</b>	2.30 ± 0.53

Data are presented as mean ± SD

Table 5 shows distribution of the studied cases according to histopathological classification.

**Table 5: Distribution of the studied cases according to histopathological classification**

		<b>N =40</b>
<b>Histological grading of TCC</b>	<b>Low grade (1-2)</b>	19 (47.5%)
	<b>High grade (3)</b>	21 (52.5%)
<b>Histopathological staging</b>	<b>pTa</b>	14 (35%)
	<b>pT1</b>	22 (55%)
	<b>pT2a</b>	4 (10%)

Data are presented as frequency (%).

## Discussion

All procedures were done using holmium laser and all were successfully completed. The mean tumour diameter was 29.8 mm, they were located most commonly on the lateral wall in 25 of 40 (62.5 %), The average operative time was 37 min, the average enucleation time was 23 min. there were no obturator nerve reflex in all cases, bladder perforation occurred in only **2.5% (one case)**. Haemoglobin drop ranged between 0-1 ~~gm/dL~~ **g/dL** with a mean was 0.3 gm/dL and there was no need for blood transfusion at all. The mean irrigation time in our study is 1.2 hours while the mean catheterization time was 28.3 hours. The mean hospital stay was 2.3 days. Pathologically, detrusor muscle was present in 100% of specimens.

The most commonly used laser parameters for Holmium laser en bloc resection is 1-2 J at 20-40Hz. Maheshwari et al.,<sup>[14]</sup> used Holmium(YAG) laser in a setting of 1-2J at 40-50 Hz. While Hashem et al.<sup>[15]</sup> used it in a setting of 1-2J at 10-15HZ. Kramer et al.,<sup>[7]</sup> used it in a setting of 1-2J at 15-30HZ. In our study we used holmium YAG laser by "VersaPulse PowerSuite (Lumenis)" in a setting of 1-1.5J at 10-12Hz by 550-micron fiber. We used a similar power but a less frequency compared to other studies for simultaneous control of bleeders and better vision. **Authors must write the citations in order: 1,2,3, etc.**

For specimen extraction we used loop electrode or cold-punsh forceps for extraction of specimen through resectoscope sheath. In one patient in our study, we used the nephroscope with its forceps for the extraction of a large tumour that exceeded 3\*3 cm after failure of its extraction by resectoscopic instruments as it was difficult and time consuming. Different methods of extraction were used as in another studies such as ellik<sup>[14]</sup>, loop electrode<sup>[15]</sup> or specimen retrieval bag<sup>[7]</sup> All these studies included only tumours equal to or less than 4 cm in maximum diameter.

In the present study the average operative time was 37 min, and the average enucleation time was 23 min. These findings are comparable to findings in other studies<sup>[14,15]</sup> where the mean operative time was 38.9 min, the mean enucleation time was 30 min.,and in another study the mean operative time was 40.9 min, the mean enucleation time was 34 min.

As expected, there were no obturator nerve reflex in all cases in our study. Similarly, in other studies there was also no obturator nerve reflex in all cases.<sup>[7, 14, 15]</sup> This is mainly due to low power usage and low penetration depth of Holmium(YAG) laser.

Bladder perforation occurred in only 1 of 40 patients (~~0.025%~~ **(2.5%)**) in our study. In other studies, there were no bladder perforation at all.<sup>[7, 14, 15]</sup> We have only one case of bladder perforation that was detected intraoperatively by severe abdominal distension, pain, tachypnea and tachycardia, although there was not any visible perforation by cystoscopy, but

due to high suspicion of intraperitoneal leak, the case was managed by drain replacement. Later, on examining our instruments we found blockage of the outflow channel of the resectoscope sheath which may explain bladder overdistension and bladder perforation that occurred unnoticed as increased intravesical pressure lasted the whole procedure. Bladder perforation was caused by such increase in intravesical pressure rather than the resection itself. Fortunately, the patient recovered very well and left the hospital after 3 days.

In our study, Hemoglobin drop ranged between 0-1 ~~gm/dL~~ **g/dL** with a mean was 0.3 ~~gm/dL~~ **g/dL**; there was no need for blood transfusion at all. In contrary In another study<sup>[14]</sup>, the mean haemoglobin drop was 1.3 ~~gm/dL~~ **g/dL**, there was intraoperative bleeding in three patients, with only one required blood transfusion.

Similar to our results, Xishuang et al.,<sup>[8]</sup>, compared mTURBT, bTURBT and holmium laser-TURBT in 173 patients, they reported that the bTURBT and holmium laser-TURBT arms have fewer intraoperative and postoperative complications, including obturator nerve reflex, bladder perforation, as well as bleeding and postoperative bladder irrigation.

The mean irrigation time in our study is 1.2 hours. Which is comparable to other studies<sup>[14,15]</sup>, where the mean irrigation time was 1.7 and 1.6 hours respectively. The mean catheterization time was 28.3 hours in our study. In other studies, urethral catheter time varies from mean 30.76, 26.5 and 29.9 hours.<sup>[7, 14, 15]</sup> Regarding the mean hospital stay, it was 2.3 days in our study which is average between other studies where the mean hospitalization time was 1.5 days<sup>[14]</sup> and in another study 2.9 days<sup>[12]</sup>.

In the study by Dsouza et al.,<sup>[12]</sup>, a trial was performed to compare the safety and efficacy of cTURBT vs Hol-ERBT. The study included 50 patients (27 Conventional-TURBT and 23 HOL-eTURBT), they concluded that Hol-eTURBT was superior to Conventional -TURBT with respect to obturator jerk, bladder perforation, irrigation duration, catheterization, hospital stay and rate of recurrence. By comparing findings of our work with

that of the previous study, it seems that bladder perforation, obturator nerve reflex, irrigation duration, catheterization, hospital stay and rate of recurrence are relatively less in patients who underwent HOL-eTURBT.

~~Pathologically,~~ All tumour margins were pathologically examined and proved to be free from any malignant cells. All specimens contained bladder detrusor muscle (100%). This is an important advantage of eTURBT which obviates the need for unnecessary re-TURBTs to get another biopsy for pathological re-evaluation, thus reducing the bother for patients and economic burden. Similar results were obtained in a study by Hashem et al.,<sup>[15]</sup> (detrusor muscle was present in 98% of cases) and in another study by Kramer et al.,<sup>[7]</sup> (detrusor muscle was present in 100% of cases). In contrary, a lower rate of detrusor muscle presence was found in a study by Maheshwari et al.,<sup>[14]</sup> (detrusor muscle was present in 85% of cases). However, this study was retrospective involving 67 patients who underwent Hol-ERBT and the same study showed that there is increasing rate of detrusor muscle presence with increasing experience of the surgeon. The biopsies performed from tumour base after resection revealed a residual tumour in only 1 of the 4 patients with T2 (0.025%). In Naselli et al.,<sup>[5]</sup> a systematic review of the available literature about eTURBT, a list of 17 original papers was included in the review, the rate of residual disease after reTURBT of the en-bloc resection bed was 0.008% (only 1 case of 119). Nevertheless, overall recurrence rate appears to be similar to cTURBT, about 20% over a two-year period.

**Limitations:** First it is time-limited (1-year study), this short period study with subsequent shortage in long-term follow-up didn't allow estimation of the overall recurrence rate in all included patient. One of the drawbacks we encountered in our study, the high cost of laser, and the need for frequent machine maintenance, the need for frequent fiber exchange after every few cases.

## **Conclusions:**

Holmium laser transurethral en-bloc TURBT is an effective, feasible, and safe procedure for managing NMIBC, as it preserves the entire lamina propria and detrusor muscle in well-intact specimens, with negligible perioperative complications.

## References:

1. Parkin DM. The global burden of urinary bladder cancer. *Scand J Urol Nephrol Suppl.* 2008;12-20.
2. Ibrahim AS, Khaled HM, Mikhail NN, Baraka H, Kamel H. Cancer incidence in egypt: results of the national population-based cancer registry program. *J Cancer Epidemiol.* 2014;2014:437971.
3. Babjuk M, Oosterlinck W, Sylvester R, Kaasinen E, Böhle A, Palou-Redorta J, et al. EAU guidelines on non-muscle-invasive urothelial carcinoma of the bladder, the 2011 update. *Eur Urol.* 2011;59:997-1008.
4. Freedman ND, Silverman DT, Hollenbeck AR, Schatzkin A, Abnet CC. Association between smoking and risk of bladder cancer among men and women. *Jama.* 2011;306:737-45.
5. Naselli A, Puppo P. En Bloc Transurethral Resection of Bladder Tumors: A New Standard? *J Endourol.* 2017;31:20-24.
6. Mariappan P, Zachou A, Grigor KM. Detrusor muscle in the first, apparently complete transurethral resection of bladder tumour specimen is a surrogate marker of resection quality, predicts risk of early recurrence, and is dependent on operator experience. *Eur Urol.* 2010;57:843-49.
7. Kramer MW, Rassweiler JJ, Klein J, Martov A, Baykov N, Lusuardi L, et al. En bloc resection of urothelium carcinoma of the bladder (EBRUC): a European multicenter study to

compare safety, efficacy, and outcome of laser and electrical en bloc transurethral resection of bladder tumor. *World J Urol.* 2015;33:1937-43.

8. Xishuang S, Deyong Y, Xiangyu C, Tao J, Quanlin L, Hongwei G, et al. Comparing the safety and efficiency of conventional monopolar, plasmakinetic, and holmium laser transurethral resection of primary non-muscle invasive bladder cancer. *J Endourol.* 2010;24:69-73.

9. Bhatta KM. Lasers in urology. *Lasers Surg Med.* 1995;16:312-30.

10. Marks AJ, Teichman JM. Lasers in clinical urology: state of the art and new horizons. *World J Urol.* 2007;25:227-33.

11. Razzaghi MR, Mazloomfard MM, Yavar M, Malekian S, Mousapour P. Holmium LASER in Comparison with Transurethral Resection of the Bladder Tumor for Non-muscle Invasive Bladder Cancer: Randomized Clinical Trial with 18-month Follow-up. *Urol J.* 2021;18:460-65.

12. D'Souza N, Verma A. Holmium laser transurethral resection of bladder tumor: Our experience. *Urol Ann.* 2016;8:439-43.

13. Teng JF, Wang K, Yin L, Qu FJ, Zhang DX, Cui XG, et al. Holmium laser versus conventional transurethral resection of the bladder tumor. *Chin Med J (Engl).* 2013;126:1761-65.

14. Maheshwari PN, Arora AM, Sane MS, Jadhao VG. Safety, feasibility, and quality of holmium laser en-bloc resection of nonmuscle invasive bladder tumors - A single-center experience. *Indian J Urol.* 2020;36:106-11.

15. Hashem A, Mosbah A, El-Tabey NA, Laymon M, Ibrahiem EH, Elhamid MA, et al. Holmium Laser En-bloc Resection Versus Conventional Transurethral Resection of Bladder Tumors for Treatment of Non-muscle-invasive Bladder Cancer: A Randomized Clinical Trial. *Eur Urol Focus.* 2021;7:1035-43.

UNDER PEER REVIEW